

## Giant Aural Cholesteatoma - A Case Report

<sup>1</sup>Dr. M.V. Appa Rao ENT Surgeon. <sup>2</sup>Dr. D. Dakshina Murthy ENT Surgeon.

<sup>3</sup>Dr. B.H. Rao, Neuro Surgeon.

<sup>1</sup>Prof. & Head of ENT Dept, Maharaja Institute of Medical Sciences, Vizianagaram,

<sup>2</sup>Assistant Professor of ENT, Andhra Medical College, Visakhapatnam,

<sup>3</sup>Associate Professor of Neuro Surgery, Andhra Medical College, Visakhapatnam.

---

**Abstract:** We present a 65 year old male, who developed giant Cholesteatoma with intracranial extension, multiple cranial nerve palsies, lateral sinus thrombosis with obliteration and post aural fistula. The Patient had foul smelling discharge from right ear since childhood. He complained of headache and LMN type of facial paralysis (right) since 6 months. Patient underwent Right Modified Radical Mastoidectomy few months back but the post aural wound didn't heal. As we saw and evaluated the patient - CT and MRI Imaging showed extensive cholesteatoma involving entire temporal bone, part of occipital bone, extending into zygomatic bone, medially encroaching jugular foramen, and postero-inferiorly up to C1 and C2 vertebra, extended intracranially into both middle and posterior cranial fossa. Using skull base surgical principles entire cholesteatoma excised, patient had uneventful follow up for 6 months. This case emphasizes the value of pre-operative radiological assessment; we present this case because of rarity of giant cholesteatoma.

---

### I. Introduction

Cholesteatoma can be defined as a cystic lesion encased by a stratified squamous epithelium filled with Keratin with a capacity of invading adjacent structures. Chronic otitis media with cholesteatoma is potentially a serious disease leading to serious complications such as Sensory Neural Deafness, Facial Paralysis, labyrinthitis, meningitis and Brain abscess (1). The term "cholesteatoma" was first utilized by the German anatomist Johannes Mueller, in 1838, whose word signifies chole-cholesterol: esteado – fatness; oma – tumor, in other words, a tumor formed by greasy tissue and crystals of cholesterol (2). However, since the cholesteatoma originates from squamous keratinized epithelium of the tympanic membrane and/or external auditory meatus; without cholesterol crystals or fatness in its structure, this term passes to be incorrect(3). Cholesteatoma was also termed as pearl tumor, by Cruveilhier, in 1829; margaritoma by CRAIGIE, in 1891; epidermic cholesteatoma by CUSHING, in 1922; cholesteatoma epidermoid by CRITCHLEY and FERGUSON, in 1928; and keratoderma, by SHUKNECHT, in 1974(1).The annual incidence of cholesteatoma revolves around of 3 cases by 100,000 in children and 9 cases by 100,000 in adults, being more predominant in the male gender(4). Epidemiological data show a high prevalence of the cholesteatoma in the Caucasian, followed by the African people descendants, being rarely seen in Asiatic people (1).

According to the literature, they can be classified into congenital and acquired (5).

The congenital represent 2% to 5 % of all cholesteatomas, being more prevalent in the male sex (3:1) (4). They are found in four regions of the temporal bone: tympanic-mastoid, petrous apex, cerebellopontine angle and jugular foramen (6). Still there is a fifth localization that is little epithelial pearls between the layers of the tympanic membrane, which was described recently (2).

Proposed theories of congenital cholesteatoma include:

- (a) The presence of an ectopic epidermis rest,
- (b) In-growth of meatal epidermis,
- (c) Metaplasia following infection/inflammation and somewhat interestingly,
- (d) Reflux of amniotic fluid containing squamous epithelium in utero into the middle ear.

The actual incidence of congenital cholesteatoma is difficult to determine. Nevertheless, greater awareness among physicians has occurred with the introduction of the high resolution CT and MRI. Perhaps as a result, its incidence seems to be increasing (7, 8). Unlike primary acquired cholesteatoma, congenital cholesteatoma typically does not present with a prior history of otorrhea, tympanic membrane perforation, or previous surgery. While there is hearing loss (usually conductive initially), the tympanic membrane is typically normal. With a close inspection, however, a pearly white mass (so-called Michael's body) medial to the eardrum is often noted (7, 9). At the other end of the disease spectrum, the clinical picture of a child with otorrhea, hearing loss (conductive type), a tympanic membrane perforation in an atypical location together with a mastoid

filled with cholesteatoma also may represent the end point in the natural history of congenital cholesteatoma. Distinguishing between congenital and acquired cholesteatoma is, however, not always that obvious (10).

The acquired cholesteatomas are divided into primary, constituted from a tympanic membrane retraction resulting from the Eustachian tube dysfunction, or secondary, which is believed to be arising from the epithelial migration through the previous perforation of the tympanic membrane(5).

Proposed theories for the pathogenesis of acquired cholesteatoma, include (a) invagination of the tympanic membrane from chronic Eustachian tube dysfunction resulting in retraction pocket (primary acquired cholesteatoma), (b) basal cell proliferation, (c) epithelial in-growth into the middle ear through a perforation (the immigration theory), (d) or inadvertent implantation (following myringotomy or tympanoplasty surgery), and (e) squamous metaplasia of the middle ear epithelium secondary to chronic infection/inflammation/persistent use of ototopical agents(11).

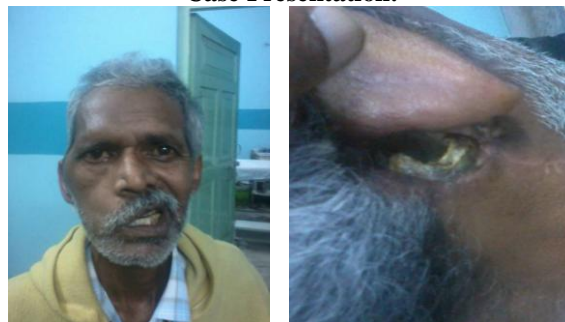
Another classification is based on the site of origin of the cholesteatoma, which is considered as an important factor for the surgical procedure and for the prognosis. (12).

1. Attic Cholesteatoma – Shrinkage of the pars flaccida of the tympanic membrane, extending into attic, aditus and occasionally into mastoid antrum.
  2. Cholesteatoma of the Tympanic Sinus – posterior superior shrinkage or perforation of the pars tensa, extending to sinus tympani and posterior portion of the tympanum.
  3. Cholesteatoma of the Pars Tensa – shrinkage and total adhesion of the tense part of the tympanic membrane.
- (a) The capacity of invasion, migration, alteration in the differentiation, proliferation and recurrence of the cholesteatoma is very similar to that of neoplasia(13,14).

Regarding the complications caused by the cholesteatoma, they can be divided into two groups: (1) the intracranial – meningitis, abscesses and thrombosis of the venous sinus and (2) intra temporal – mastoiditis, labyrinthine fistula, facial nerve paralysis, labyrinthitis and ossicular chain destruction. (1, 5, 15).

The management of chronic otitis media is essentially surgical. The primary objective is the complete eradication of the illness. The secondary objective is the preservation or the improvement of the function of the Tympanic ossicular system (16).

#### **Case Presentation:**



**Fig No: 1**

**Fig No:2**

It is a case of 65 year old male thin built, working as a farmer.

Main Complaint: Foul smelling Ear discharge (Right) since childhood

**History of Present illness:** Patient came with a complaint of deviation of mouth to left side(Fig No:1), inability to close right eye since 6 months, ear discharge, Post aural fistula with discharge (Fig No:2), difficulty in swallowing food, choking attacks while taking food since 2 months

**Past History:** Ear discharge present since childhood. Patient underwent Modified Radical Mastoidectomy by an ENT surgeon 2 months back after which the post aural wound didn't heal.

**Otorhinolaryngological Examination:** Right ear – shows cavity filled with purulent debris, post aural area shows fistula draining purulent discharge.

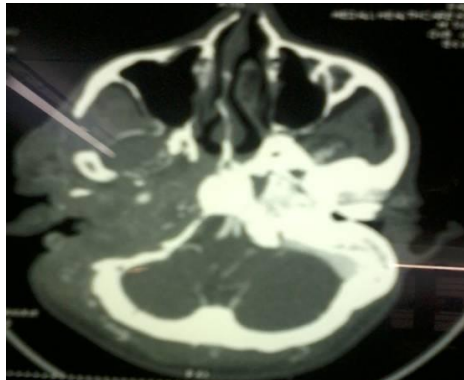#### **Cranial Nerve Examination:**

1. Right - LMN type Facial nerve paralysis - H.B. Grade V

2. IX, X, XII cranial nerve palsies on the right side present.

**Pure Tone Audiogram** shows severe sensory neural deafness in the right ear.

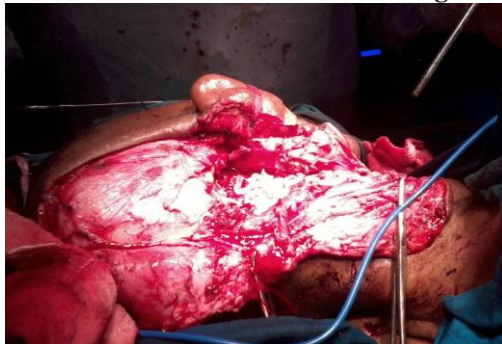**CT and MRI Report:**



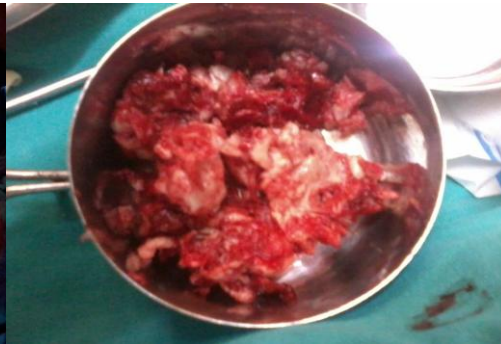**Fig No:3**

MRI showed a high signal lesion on T2, a moderately low signal lesion on T1 with rim enhancement after gadolinium infusion, consistent with diagnosis of cholesteatoma. The CT was reported that the lesion; cholesteatoma occupied the entire temporal bone destroying mastoid, squamous and petrous parts of temporal bone, extending anteriorly to zygoma, medially up to the sphenoid sinus, posteriorly the lesion is found to be extending and destroying the part of occipital bone, inferiorly involving jugular foramen, extending up to C1 & C2 vertebra.

#### **Surgical Procedure:**



**Fig No:4**



**Fig No:5**

Using the skullbase surgical principals, a modified endaural incision (Fig No:4) was taken as described by Dr Ram Tiwari(17), encircling the post auricular wound. The end aural incision extended postero-superiorly into the temporal region and antero- inferiorly extended up to the middle of the neck. Massive blocks of cholesteatoma ( Fig No:4) cleared totally. I.C.A. and Facial nerve identified and found to be running naked along the petrous. Neck Dissection done for control of great vessels in advance. Blind sac closure of external auditory canal done. Wound is camouflaged by rotating part of temporalis muscle inferiorly and part of sternomastoid muscle superiorly. Wound is closed after blocking the Eustachian tube with muscle and bone wax. Post operative recovery was good and the post auricular wound healed well though it took about 3 months.

## **II. Discussion**

Cholesteatoma is a non-malignant, slowly progressive, destructive middle ear disease. Extension of aural cholesteatoma through the temporal bone cortex is unusual (18). Bone destruction, due mostly to the osteoclastic erosion, is known to be an important cause of complications in chronic otitis media (19). Humeral factors, such as prostaglandin, cathepsin D, and a parathyroid hormone – like protein have been suggested as responsible for the activation of osteoclasts(20). The presented case is a good example of cholesteatoma invasiveness beyond the confines of the temporal bone.

This case emphasizes the need for utmost awareness regarding the development of a giant cholesteatoma that presents with relatively few or limited symptoms. Radiologic imaging modalities should be integrated into findings obtained from clinical history and physical examination even in conditions that are not suggestive of a giant cholesteatoma.

Cholesteatoma can exist for years as a non-aggressive state, with minimal symptoms that might seem mild to the family physician and therefore remain untreated until their potentially dangerous character becomes obvious. Otolologists have a responsibility to heighten awareness among general practitioners and pediatricians of the potentially life-threatening nature of cholesteatoma and the importance of proper attention by the family physician to seemingly mild otologic symptoms.

### References

- [1]. Ferlito O, Devaney KO, Rinaldo A, Milroy C, Wenig B, Iurato S, McCabe BF. Clinicopathological consultation ear cholesteatoma versus cholesterol granuloma. *Ann Otol Rhinol Laryngol.* 1997, 106:79-85.
- [2]. Pereira CSB, Almeida CIR, Vianna MR. Imunoexpressão da citoqueratina 16 e do antígeno nuclear Ki-67 no colesteatoma adquirido da orelha média. *Rev Bras de Otorrinolaringol.* 2002, 68(4): 453-60.
- [3]. Swartz JD. Colesteatomas of the middle ear. *Diagnosis Etiology and Complications. Radiol Clin North Am.* 1984, 22(1):15-34.
- [4]. Sprekelsen BM, Ebmeyer J, Anonopoulos A, Sudhoff H. Alteraciones de la membrana basal en el colesteatoma de oído medio. *Acta Otor Esp.* 2001, 52(4):330-5.
- [5]. Milewski C, Fedorowski A, Stan AC, Walter GF. Basic fibroblast growth factor (b-FGF) in the perimatrix of cholesteatoma. *HNO.* 1998(a), 46(9):804-8.
- [6]. Jacob R, Welkoborsky HJ, Mann W. Epithelium-stroma interaction in cholesteatoma of the middle ear. *Laryngorhinootologie.* 2001, 80(1):11-7.
- [7]. Kazahaya K, Potsic WP (2004) congenital cholesteatoma. *Curr Opin Otolaryngol Head Neck Surg* 12(5):398–403
- [8]. Nishizaki K, Yamamoto S, Fukazawa M, Yuen K, Ohmichi T, Masuda Y (1996) Bilateral congenital cholesteatoma. *Int J Pediatr Otorhinolaryngol* 34(3):259–264
- [9]. Nelson M, Roger G, Koltai PJ, Garabedian EN, Triglia JM, Roman S, Castellon RJ, Hammel JP (2002) Congenital cholesteatoma: classification, management, and outcome. *Arch Otolaryngol Head Neck Surg* 128(7):810–814
- [10]. Koltai PJ, Nelson M, Castellon RJ, Garabedian EN, Triglia JM, Roman S, Roger G (2002) The natural history of congenital cholesteatoma. *Arch Otolaryngol Head Neck Surg* 128(7):804–809.
- [11]. Lesinskas E, Kasinskas R, Vainutiene V (2002) Middle ear cholesteatoma: present-day concepts of etiology and pathogenesis [Lithuanian]. *Medicina (Kaunas)* 38(11):1066–1071; quiz 1141
- [12]. Sculerati N, Bluestone C. Pathogenesis of cholesteatoma. *The Otol Clin of North Am.* 1989, 22(5):859-68.
- [13]. Chole RA, Faddis BT. Evidence for microbial biofilms in cholesteatomas. *Arch Otolaryngol Head Neck Surg.* 2002, 128(10):1129-1133.
- [14]. Bujia J, Schiling V, Holly A, Stammberger M, Kastenbauer E. Hyperproliferation-associated keratin expression in human middle ear cholesteatoma. *Acta Otolaryngol.* 1993, 113(3):364-368.
- [15]. Verdugo RM, Caba GE, Serrano CA, Ortega AM. Colesteatoma gigante a tímpano cerrado. *Acta ORL Esp.* 2001, 52(2):147-9.
- [16]. Paparella MM, Moris MS, Costa SS. A one stage compromise of the open vs. closed method. *The IBM Procedure Proco of the Third Intem Conf on Cholesteatoma and Mastoid Surg.* Amsterdam: Kluger Publications; 1988.
- [17]. *Surgical anatomy of the Infra temporal fossa*, Edited by John D Langdon, Barry KB Berkontz, Bernard J Moxham.
- [18]. Atlas MD, Moffat DA, Hardy DG. Petrous apex cholesteatoma: diagnostic and treatment dilemmas. *Laryngoscope* 19192;102(12 Pt):12-5.
- [19]. Yoon TH, Lee SH, Park MH, Chung JW, Kim HJ. Inhibition of cholesteatomatous bone resorption with pamidronate disodium. *Acta Otolaryngol* 2001;121:178-81.
- [20]. Youngs R. Chronic suppurative otitis media-cholesteatoma. In: Ludman H, Wright T, editors. *Diseases of the ear* 6<sup>th</sup> ed. London: Arnold; 1988. p.386-97.