

A Maxillary Second Molar with an unusual positioning of Palato-Mesiobuccal Canal: A case report

Thomas Abraham 1* , Shashikala K 2 , Vanamala N 3

1*Post Graduate Student, 2 Professor and Head of Department, 3 Reader

Department of Conservative Dentistry and Endodontics, D.A.P.M.R.V Dental College, Bangalore

I. Introduction

A proper debridement, disinfection and a three dimensional hermetic seal of the root canal system were essential for a successful root canal therapy (1). Majority of the endodontic failures occurs because of undetected roots/canals. Hence, a clear understanding of the root canal anatomy and its possible variations is a prerequisite for successful root canal treatment (2).

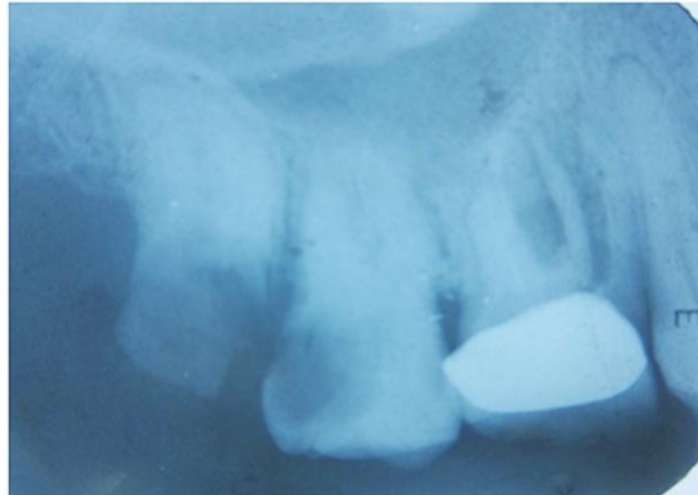
Maxillary second molar have a variety of different shapes, resulting in diagnostic and treatment challenges. They are generally described as a group of teeth with 3 roots, 1 palatal (P) and 2 buccal [Mesiobuccal (MB) & Distobuccal (DB)], each root having 1 root canal. (3). There are reports of maxillary second molar in fusion with a supernumerary tooth (4), 'C' shaped palatal canal (5), one (6), five (7) or even six root canals (8). Other variations include one (6), four (9), five (10) roots and taurodontism (11). However, the most common root canal variation in maxillary molar is the presence of a second MB canal (P-MB) positioned mesial and palatal to the MB canal.

Case reports of maxillary first molars with unusual position of the second MB canal (P-MB) have also been reported (12,13); however, this anomaly has not been documented in the maxillary second molar to date. The present case report describes the endodontic management of a maxillary second molar with an unusual positioning of P-MB, which is not yet reported in literature. The case was diagnosed with careful clinical examination of the pulp chamber floor and confirmed using Cone Beam Computerized Tomography scanning. Additionally, the case report may intensify the complexity of maxillary first molar variation and is intended to reinforce clinicians' awareness of the rare location of root canal orifices of maxillary first molar.

II. Case Report

A 45 year old male patient reported with a chief complaint of continuous and referred pain in relation to upper right back region of the jaw for several days. Patient also complained of presence of sensitivity episodes to hot and cold beverages even after the removal of the stimulus. Medical history taken was non-contributory. Patient reported of a root canal treatment on the right upper back tooth 3 years back. On clinical examination, the oral hygiene of the patient was examined to be fair. Dental examination revealed 16 with full crown, deep carious lesion in relation to 17 and grossly decayed 18 with poor restorability. Tender on vertical percussion was negative with 16 and was positive with 17. On palpation the response was negative in relation to 16, 17 and 18. Radiographic evaluation found that 16 was root canal treated with full crown and fracture of MB root can be seen. 17 showed radiolucency involving pulp with no periapical changes and 18 showed complete coronal radiolucency. Sensitivity tests like electric pulp tests and thermal tests was done, in which 17 showed positive response. Finally from the clinical, radiographic and sensitivity tests, the diagnosis of 17 showed symptomatic irreversible pulpitis with symptomatic apical periodontitis. Due to the poor restorability of 18 and poor prognosis to retain 16, extraction was advised for both the teeth. The treatment plan was to defer the extraction of 16, due to the asymptomatic clinical condition and patient's unwillingness, 18 was advised for extraction and 17 for non – surgical endodontic therapy. Fig 1

Fig 1:- Pre – Operative IOPA revealing grossly decayed 18, pulpally involved 17 and root canal treated 16 and fractured MB root with crown.



After administering 3 ml of local anaesthesia (Lignox 2% A), the caries was excavated from the proximal walls. Distal wall reconstruction was done with glass ionomer cement(GC Universal Restorative) so as to obtain a good isolation. The tooth was isolated with rubber dam and a conventional endodontic access cavity was prepared. After extirpating the pulp tissues, three principle orifices were located with DG 16 explorer (Hu - Friedy). An unusual pattern of developmental root fusion line (DRFL) was observed within the pulp chamber floor. The conventional triangular access was modified to a rectangular shape to uncover the dentine over the DRFL which revealed an additional canal in the mesio palatal aspect (Fig 2). The working length of each canal was estimated by means of Ingle's method using K – files [Mani Inc. files] (Fig 3). Intra – Oral camera (VistaCam Digital) was used to properly visualize the orifices, which show an “X” shape pulpal floor topographic appearance. Fig 4

Fig 2:- Intra – Oral picture of access cavity in relation to 17 showing 3 canals along with an unusual location of Palato – Mesiobuccal Canal.

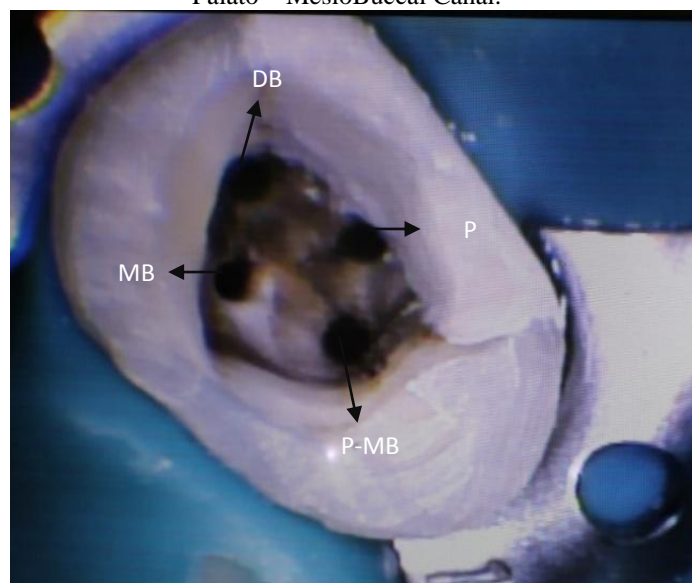


Fig 3:- IOPA revealing the working length determination.

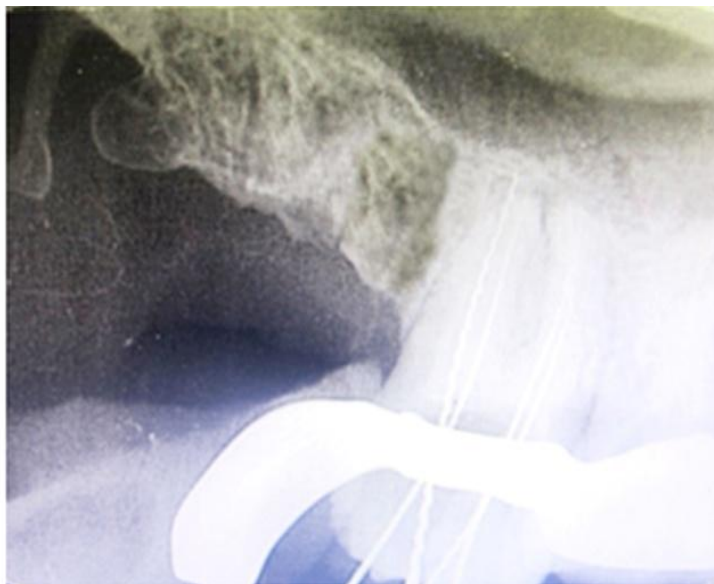
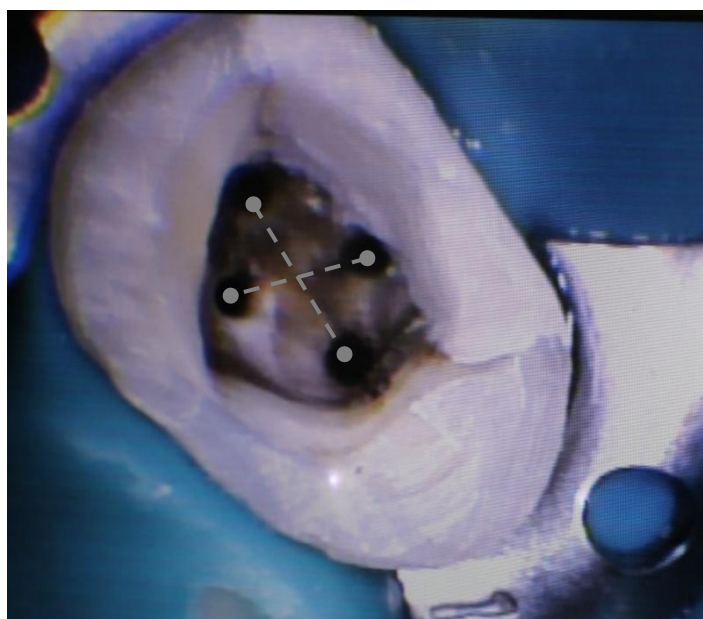


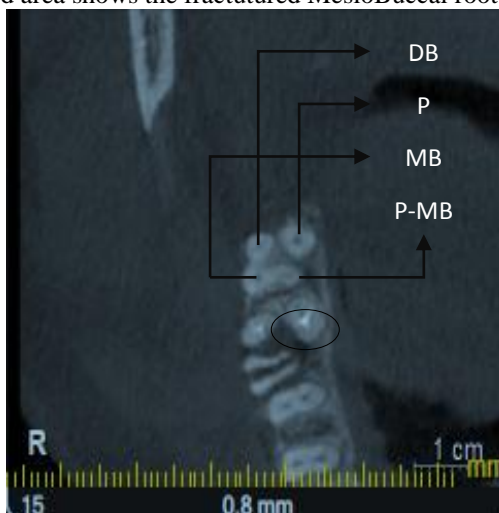
Fig 4:- Intra – Oral picture showing an “X” shape pulpal floor topography.



An intra oral periapical radiograph and CBCT scan was advised to confirm the location of eccentrically placed Palatal orifice (P-MB) and then was closed with a temporary restoration.

The CBCT image showed fractured MB root of 16 and a broad mesial root extending bucco–palatally with second mesio – buccal canal located close to the palatal canal in relation to 17. Fig 5

Fig 5:- CBCT picture reveals Palatal, MesioBuccal, DistoBuccal and Palato – MesioBuccal canal of 17 and encircled area shows the fractured MesioBuccal root of 16.



In the next appointment, the canals were initially instrumented with #15 K file [Mani Inc. Files] under copious irrigation with 3% sodium hypochlorite and 17% EDTA. Coronal flaring was carried out by using Gates Glidden Drill [Mani No. 2 & 3]. Cleaning and shaping of the canals was done by using Hyflex CM rotary files with modified hybrid technique. The canals were obturated with 2% gutta – percha cones and Sealapex [Sybronendo] using lateral condensation technique. The access cavity was then restored with posterior composites. Fig6 periodic recalls were made at 1, 3 and 6 months. 6 month follow up IOPA shows resorption of the sealer puff, satisfactory and progressive healing. The patient will be reviewed periodically to assess treatment outcome. Fig 7

Fig 6:- Post – Obturation IOPA.

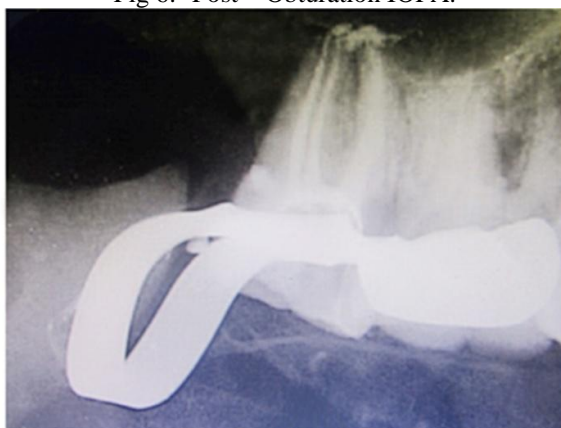
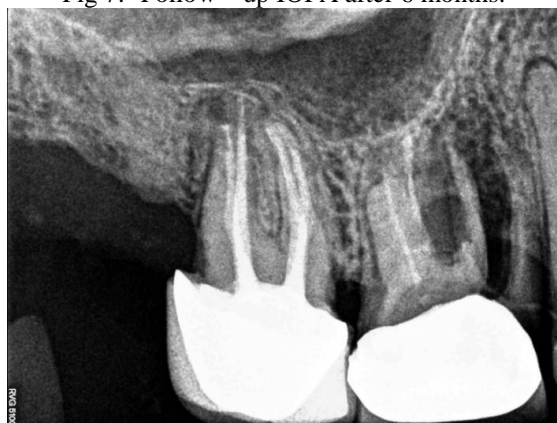
Fig 7:- Follow – up IOPA after 6 months.



III. Discussion

Preoperative and working radiographs should be carefully examined in order to detect extra canals(14). However, supplementary MB canals are occasionally challenging to locate on conventional radiographs because of their small size and superimposition of the main MB canal and the periodontal ligament space (14). Detection will be even more complicated if the additional canal is located in an unusual position. Stropko found the MB2 canal in 73.2% of first molars, 50.7% of second molars, and in 20.0% of third molars in a pool of 1,732 maxillary molars conventionally treated over an 8.5-year period (15).

The “MB2” canal is commonly located palatally and mesially to the “MB1” (16). Gilles & Reader described the MB2 canal according to the main mesiobuccal canal and found the mean distance of the mesiolingual orifice from the mesiobuccal orifice 2.31 and 1.82 mm, respectively(17). Zhang et al reported that the MB2 canal was located less than 1mm mesially to the MB-P line and 2mm palatally from the MB orifice(18). Görduysus et al determined the location of the MB2 canal in 45 extracted maxillary molars and found these measurements 0.69 mm mesially and 1.65 mm palatally(19). However, in the present case the MB2 canal was located much closed to the palatal root canal orifice which was not reported in any clinical or laboratory studies nor clinical case reports so far. This unusual morphology was diagnosed clinically with magnification and confirmed with the help of CBCT.

When extra canals in the MBR are suspected, rhomboidal access preparation should be made in contrast to the traditional triangular form (20). However, if the MB2 canal is located palatally like in the present case, a rectangular access is recommended. The “subpulpal grooves or developmental grooves” on the pulpal floor should be carefully examined and explored using endodontic explorer (21), round burs (22) or ultrasonic tips (20) to locate potential canal orifices. In addition, use of magnification, micro-openers, bubble test, champagne test, transillumination, red line test, white line test are important aids in locating canal orifices (23). Apart from the aforesaid diagnostic tools, the operator experience (15) and lengthier time spent per appointment (24) show a major role in tackling extra canals.

The second mesiobuccal canal has been cited in the dental literature as MB2, mesiopalatal, second mesiobuccal, and the mesiolingual canal. Additionally, various authors have interchangeably used the term “mesiopalatal” to describe both, the MB2 as well as the mesial of the two palatal canals/roots. Accordingly, Kottoor et al proposed a new anatomically based nomenclature for root canalsthat provides a clear picture of anyexisting root and canal aberranciesin maxillary and mandibularmolars. In the present case, rootcanal orifices were named according to this nomenclature [3].

IV. Conclusion

The incidence of variations, especially the multiplicity of canals in maxillary second molar is not common. However, if the additional canal orifice is located in an unusual position, their documentation provides important awareness for clinicians and draw attention to their existence so that similar anatomy may be recognized and adequately treated endodontically.

References

- [1]. Sharma S, Mittal M, Passi D, Grover S. Management of a maxillary first molar having atypical anatomy of two roots diagnosed using cone beam computed tomography. *J Conser Dent*.2015;18:342-45
- [2]. Kottoor J, Albuquerque DV, Velmurugan N. Four-Rooted Mandibular First Molar with an Unusual Developmental Root Fusion Line: A Case Report. *Case Reports in Dentistry*.2012;237302:1-4
- [3]. Kottoor J, Albuquerque DV, Velmurugan N. A New Anatomically Based Nomenclature for the Roots and RootCanals— Part1:Maxillary Molars. *International Journal of Dentistry*.2012;120565:1-7
- [4]. Weinstein T, Rosano G, Del Fabbro M, Taschieri. Endodontic treatment of a geminated maxillary second molar using an endoscopoe as magnification device. *2010;43:443-50*.
- [5]. Singla M, Aggarwal V. C-Shaped palatal canal in maxillary second molar mimicking two palatal canals diagnosed with the aid of spiral computerized tomography. *Oral Surg Oral Med Oral Pathol Radiol Endod* 2010;109:92-5 .
- [6]. Jaikrishnan S, Kottoor J, Mathew J, Kumar SR, George S, Hari K. Evaluation and endodontic management of a patient with 6 single-rooted molars: a case report. *Gen Dent* 2015;63:35-3 .
- [7]. Zhu Z, Zhao SL. Maxillary second molar with five root canals: a case report. *Shanghai Kou Qiang Yi Xue* 2011;20:219-2 .
- [8]. Kim JR, Choi SB, Park SH. A maxillary second molar with 6 canals: a case report. *Quintessence Int*. 2008;39:61-4.
- [9]. Qun L, Longing N, Qing Y, Yuan L, Jun W, Qingyiue D. A case of asymmetric maxillary second molar with double palatal root. *Quintessence Int* 2009;40:275-6.
- [10]. Kottoor J, Hemalathi S, Sudha R, Velmurugan N. Maxillary second molar with 5 roots and 5 canals evaluated using cone beam computerized tomography; a case report. *Oral Surg Oral Med Oral Pathol Oral Radiol Endod* 2010;109:162-5.
- [11]. Radwan A, Kim SG. Treatment of a hypertaurodontic maxillary second molar in a patient with 10 taurodonts: a case report. *J Endod* 2014;40:140-4.
- [12]. Kottoor J, Velmurugan N, Sudha R, Hemalathi S. Maxillary First Molar with Seven Root Canals Diagnosed with Cone-Beam Computed Tomography Scanning: A Case Report. *Journal of Endodontics*. 2010;36:915-21.
- [13]. Chakradhar Raju RVS, Sathe N, Morisetty P K, Veeramachaneni C. Endodontic management of a maxillary first molar with unusual location of second mesio buccal orifice. *J Conserv Dent*.2010;13:162-64.
- [14]. Fava LR, Dummer PM. Periapical radiographic techniques during endodontic diagnosisand treatment. *IntEndod J* 1997;30:250–61.
- [15]. Stropko JJ. Canal morphology of maxillary molars: clinical observations of canal configurations. *J Endod* 1999 Jun;25(6): 446-50.

- [16]. Kulild JC, Peters DD. Incidence and configuration of canal systems in the mesiobuccal root of maxillary first and second molars. *J Endod.* 1990;16:311–317.
- [17]. Gilles J, Reader A. A SEM investigation of the mesiolingual canal in human maxillary first and second molars. *Oral Surg Oral Med Oral Pathol.* 1990;70:638–643
- [18]. Zhang CF, Ding RY, Yin XZ, Zhao BH, Lin QG. Location and negotiation of second mesiobuccal canals in maxillary molars. *Zhonghua Kou Qiang Yi Xue Za Zhi.* 2003;38:86–88. 28.
- [19]. Baldassari-Cruz LA, Lilly JP, Rivera EM. The influence of dental operating microscope in locating the mesiolingual canal orifice. *Oral Surg Oral Med Oral Pathol Oral Radiol Endod.* 2002;93:190–194.
- [20]. Kottoor J, Velmurugan N, Surendran S. Endodontic management of a maxillary first molar with eight root canal systems evaluated using cone-beam computed tomography scanning: a case report. *J Endod* 2011;37:715–9.
- [21]. Ferguson DB, Kjar KS, Hartwell GR. Three canals in the mesiobuccal root of a maxillary first molar: a case report. *J Endod* 2005;31:400–2.
- [22]. Garg AK, Tewari RK, Kumar A, Agrawal N. Endodontic treatment of a maxillary first molar having three mesiobuccal canals with the aid of spiral computed tomography: a case report. *J Oral Sci* 2010;52:495–9.
- [23]. Vertucci FJ. Root canal morphology and its relationship to endodontic procedures. *Endod Topics* 2005;10:3–29.
- [24]. Corcoran J, Apicella MJ, Mines P. The effect of operator experience in locating additional canals in maxillary molars. *J Endod* 2007;33:15–7.