

## Gastroprotective effect of flavonoid quercetin and coenzyme Q10 in indomethacin-induced gastric ulcers in normal and diabetic rats

Eman F. Khaleel<sup>1,4</sup>, Dalia G. Mostafa<sup>2,4</sup> and Ghada A. Abdel-Aleem<sup>3,5</sup>

<sup>1</sup>Department of Medical Physiology, Faculty of Medicine, Cairo University, Cairo, Egypt.

<sup>2</sup>Department of Medical Physiology, Faculty of Medicine, Assiut University, Assiut, Egypt.

<sup>3</sup>Department of Medical Biochemistry, Faculty of Medicine, Tanta University, Tanta, Egypt.

<sup>4</sup>Department of Medical Physiology, College of Medicine, King Khalid University, Abha, Saudi Arabia.

<sup>5</sup>Department of Medical Biochemistry, College of Medicine, King Khalid University, Abha, Saudi Arabia.

**Abstract:** Various studies have indicated that peptic ulcers occurring during the course of diabetic state are more severe and often associated with complications such as gastrointestinal bleeding. This study is an attempt to understand the pathogenesis of indomethacin-induced gastric ulcers occurring during the diabetic state using suitable markers and its amelioration by quercetin and coenzyme Q10 (CoQ10). In this study, diabetic rats showed an increase in the gastric mucosal levels of Molandialdehyde (MDA), inducible nitric oxide synthase (iNOS), interleukin-6 (IL-6), tumor necrosis factor (TNF- $\alpha$ ), BAX and p53 and a decrease in the activities of superoxide dismutase (SOD) as compared to normal control (non-diabetic) rats. There was an increase in gastric ulcer index and gastric ulcer lesions in diabetic gastric mucosa when compared to the normal control group. Pre-treatment with quercetin and/or CoQ10 to normal groups or diabetic groups which treated by indomethacin caused a significant decrease in gastric ulcer index, MDA, iNOS, IL-6, TNF- $\alpha$ , BAX and p53 with concomitant increase in SOD activity when compared with normal and diabetic rats treated with indomethacin alone. So quercetin and CoQ10 are effective in protection against indomethacin-induced gastric ulcers in normal and diabetic rats. Our findings could bring new hope for a novel modality of gastric ulcer treatment.

**Keywords:** Coenzyme Q10, Diabetes Mellitus, Gastric ulcer, Indomethacin, Quercetin.

### I. Introduction

Diabetes mellitus is a heterogeneous metabolic disorder characterized by hyperglycemia resulting from defective insulin secretion, resistance to insulin action or both. Majority of the diabetic patients suffer from diabetic nephropathy, retinopathy, cardiomyopathy, neuropathy, however, little attention has been paid to the incidence and healing rate of peptic ulcer in diabetes [1].

Peptic ulcer is a common disorder of the entire gastrointestinal tract [2]. It occurs mainly in the stomach and the proximal duodenum. The prevention or cure of peptic ulcer is one of the most important challenges confronting medicine nowadays, as it is certainly a major human illness affecting nearly 8 to 10 % of the global population, and of these 5% suffer from gastric ulcers [3].

Increased production of free radicals, inhibition of cell proliferation, infiltration of polymorphonuclear leukocyte, induction of apoptosis, tumor necrosis factor- $\alpha$  (TNF- $\alpha$ ) overexpression, and interleukin-1b (IL-1b) upregulation are coupled to gastric ulcer etiology [4]. Hence, the mechanism by which gastric ulcers are produced remains unclear [1].

Gastric ulcer therapy faces nowadays a major drawback because most of the drugs currently available in the market show limited efficacy against gastric diseases and are often associated with severe side effects [5]. In this context, the use of medicinal plants is in continuous expansion all over the world for the prevention and treatment of different pathologies [6].

Indomethacin is frequently used and clinically relevant experimental model for the induction of acute gastric ulcer, its use in the present study was based on the fact that non-steroidal anti-inflammatory drugs are commonly used worldwide [7].

Indomethacin is known to produce erosions, ulcerative lesions, and petechial bleeding in the mucosa of stomach as serious side effects [8]. The development of the gastric mucosal lesions induced by indomethacin is mainly mediated through generation of oxygen free radicals and lipid peroxidation [9] as well as nitric oxide (NO) through iNOS, leading to oxidative burst, which inflicts endothelial damage [10].

The flavonoid quercetin (3,3',4',5,7-pentahydroxyflavone) is one of the most potent antioxidant of plant origin. It protects the gastrointestinal mucosa from acute lesions induced by various experimental models and against different necrotic agents, including restraint stress, aspirin [11], indomethacin [12], and ethanol-induced gastric ulcers [13].

The main mechanism of action for the gastroprotective effects of this flavonol are its antioxidant properties [13].

It has been shown in previous studies that antioxidant agents such as coenzyme Q10 and quercetin have positive effects in DM [14].

Coenzyme Q10 (ubiquinone) is a naturally occurring compound widely distributed in animals and humans. An essential role of coenzyme Q10 is as an electron carrier in the mitochondrial respiratory chain. Moreover, coenzyme Q10 is one of the most important lipophilic antioxidants, and it can also regenerate the other powerful lipophilic antioxidant, alpha-tocopherol [15], besides replenishment of prostaglandin E2 and nitric oxide in the gastric mucosa; characters that endorse its potential usefulness against gastric damage [16].

Coenzyme Q10 has been shown to act as a hepatoprotective agent, also affects glucose and lipid metabolism in vitro and in vivo in monogastric species [17].

The aim of this study is to investigate and compare how the extent of oxidative damage and the antioxidant capacity in the gastric mucosa of non-diabetic and diabetic rats with induced gastric ulcer by indomethacin. Also, we investigate the possible protective role of coenzyme Q10 and quercetin.

## **II. Materials And Methods**

### **2.1 Drugs and chemicals**

Indomethacin, Thiobarbituric acid, n-butanol, pyridine, sodium dodecyl sulfate (SDS), acetic acid and diethyl ether were obtained from Sigma Chemical Co. (St. Louis, MO, USA). Indomethacin was suspended in 2% NaCO<sub>3</sub> [18]. All drugs solutions and suspensions were freshly prepared and used. Quercetin (No. Q4951), CoQ10 (C<sub>59</sub>H<sub>90</sub>O<sub>4</sub>, Cat No. C9538), Evans blue dye (Cat No. 206334) and 2,3,5-triphenyltetrazolium chloride (TTC, Cat T8877) was purchased from Sigma-Aldrich (St. Louis, MO, USA). CoQ10 was prepared in 1% aqueous solution of Tween 80 as previously described [19].

### **2.2 Experimental Animals:**

Healthy adult male Wistar albino rats weighing 250 – 300 g and aged 8 weeks obtained from the animal facility centre of the college of medicine at King Khalid University, Abha, Saudi Arabia were used. They were housed in plastic cages at a temperature of 23 ± 2°C and 55 ± 15% humidity, with a 12 h light/12 h dark cycle and fed standard rodent diet and water ad libitum. The rats were fasted overnight before the study. All experiments performed on laboratory animals in this study followed the “Principles of laboratory animal care” (NIH Publication No. 85, Rev, 1985).

### **2.3 Experimental design**

60 animals were classified into 2 major groups of control or diabetic rats (each group 30 rats), each of these 2 groups were further subdivided into five subgroups (each group 6 rats) and treated as follows.

1. Control groups: were either normoglycemic (non-diabetic) or diabetic rats received 1ml normal saline i.p.
2. IND treated groups: were normal or diabetic gastric ulcer induced rats which received normal saline, i.p for 14 days and then received single oral dose of indomethacin (IND, 20 mg/kg).
3. IND+Qur treated rats: were normoglycemic or diabetic rats received i.p dose of Quercetin (50 mg/kg) for 14 days and then received a single oral dose of IND.
4. IND+COQ10 treated rats: were normoglycemic or diabetic rats received i.p dose of CoQ10 (20 mg/kg) for 14 days and then received a single oral dose of IND.
5. IND+Qur+CoQ10: were normoglycemic or diabetic rats received a concomitant dose of both Qur and CoQ10 using same doses and routs as above and then received a single oral dose of IND.

CoQ10 and Quercetin doses and mode of administration selected in according to previously published research which demonstrated a safe and therapeutic effect of Quercetin and Co Q 10 in rats [19, 20].

### **2.4 Induction of diabetes mellitus**

Diabetes mellitus was induced in Wistar rats by single intraperitoneal injection of streptozotocin (50mg/kg) dissolved in 0.1M-citrate buffer (pH 4.5) after overnight fasting for 12 h. The diabetes was assessed by determining the blood glucose concentration within 48 hours after injection of streptozotocin. The rats with blood glucose level above 250 mg/dl were selected for the experimental studies [4, 21].

### **2.5 IND gastric Ulcer induction**

At the end of day 14, the rats were fasted overnight. The rats of the ulcer groups mentioned above were received an intragastric gavage dose of 20 mg/kg indomethacin dissolved in 2% NaCO<sub>3</sub> and brought to a volume of 1.0 ml with saline (pH 6.8). Indomethacin was administered at 7:30 AM and the animals were placed in their home cages with free access to food and water. Six hours after indomethacin dosing, the rats were anesthetized and killed with light diethyl ether, the stomachs were isolated, investigated for gastric lesions and

some parts were quickly removed and treated as described below for biochemical, molecular and histopathological studies.

## **2.6 Assessment of gastric mucosal lesions**

Each stomach was opened along the greater curvature. Then, the stomachs were washed with ice-cold saline and examined for macroscopical mucosal lesions by an observer unaware of the treatment protocol. The gastric mucosal lesions were expressed in terms of ulcer index (U.I.) according to Peskar et al. [22] which depends on the calculation of a lesion index by using of a 0-3 scoring system based on the severity of each lesion. The severity factor was defined according to the length of the lesions. Severity factor 0 = no lesions; 1 = lesions < 1 mm length; 2 = lesions 2-4 mm length and 3 = lesions > 4 mm length.

The lesions score for each rat was calculated as the number of lesions in the rat multiplied by their respective severity factor. The U.I. for each group was taken as the mean lesion score of all the rats in that group.

## **2.7 Preparing the tissue homogenate**

100 mg of the stomach tissues were homogenized separately in 0.1 mole Tris-HCl buffer, pH 7.4 using a homogenizer at 4°C with a diluting factor of 4. The crude tissue homogenate was then centrifuged at a speed of 9000 rpm for 15 min in a cold centrifuge and the supernatant was collected and stored at -20°C until analysis for measuring the levels of Malondialdehyde (MDA), the activities of superoxide dismutase (SOD) and inducible nitric oxide synthase (iNOS) and levels of inflammatory markers including interleukin-6 (IL-6) and tumor necrosis factor (TNF- $\alpha$ ).

## **2.8 Oxidative stress assays**

Lipid peroxidations in the gastric homogenates were measured by measuring the levels of the Thiobarbituric Acid Reactive Substances (TBARS) using commercial kits (Cat No. NWK-MD-A01, NWLSS, Vancouver, Ca) as per manufacturer's instructions. TBA reacts with Malondialdehyde (MDA) forming an MDA-TBA<sub>2</sub> adducts at 532 nm. In brief, tissue supernatant (50  $\mu$ L) was added to test tubes containing 2  $\mu$ L of butylated hydroxytoluene (BHT) in methanol to prevent oxidation of sample. Next, 50  $\mu$ L of acid (1 M phosphoric acid) and 50  $\mu$ L of TBA solution were added. The tubes were mixed, incubated for 60 min at 60°C and centrifuged. The supernatant was aliquoted and absorbance measured at 532 nm. TBARS levels were expressed as nmol/mg protein.

Superoxide dismutase (SOD) activity in gastric homogenates was measured using a commercial kit (Cat. No. 706002, Cayman Chemical, Ann Arbor, MI, USA) as per manufacturer's instructions. Briefly, the kit uses hypoxanthine and xanthine oxidase to generate superoxide radical that is detected through its reaction with a tetrazolium salt to form a formazan dye that absorbs at 440 nm. SOD dismutates superoxide to hydrogen peroxide, resulting in a decrease in the amount of formazan dye and absorbance read at 440 nm. The calculated SOD activity was expressed as U/mg protein, protein was measured by Bradford method.

## **2.9 ELISA of inflammatory markers and iNOS**

Inducible nitric oxide synthase (iNOS, Cat. No R6663) levels were determined in the gastric homogenates using special rat ELISA kit purchased from STZ ELISA Company, USA. Levels of TNF- $\alpha$  and IL-6 in gastric homogenates were determined by ELISA (Cat no. ab46070, Abcam, Cambridge, MA, USA and Cat No. ELR-IL6-001, RayBio, MO, USA, respectively) as per the manufacturer's instruction. In brief, 100  $\mu$ L of homogenate supernatant was used in the reaction and the intensity of the developed color at 450 nm was directly proportional to the concentration of TNF- $\alpha$  and IL-6 contained in the samples. Gastric levels of TNF- $\alpha$  and IL-6 levels were expressed as pg/mg protein.

## **2.10 RNA extraction and RT-PCR**

The procedure was optimized for semiquantitative detection using the primer pairs and conditions described in Table 1. Published sequences of RT-PCR primers used for the detection of BAX, p53 and  $\beta$ -actin were used according to the procedure established already in our labs [19]. Total RNA was extracted from the frozen parts of gastric tissue (30 mg) using an RNeasy Mini Kit (Qiagen Pty. Ltd., Victoria, Australia) according to manufacturer's directions. The concentration of total RNA was measured by absorbance at 260 nm using a UV1240 spectrophotometer (Shimadzu, Kyoto, Japan). The purity was estimated by the 260/280nm absorbance ratio. Single-strand cDNA synthesis was performed as follows: 30  $\mu$ L of reverse transcription mixture contained 1  $\mu$ g of DNase pretreated total RNA, 0.75  $\mu$ g of oligo d (T) primer, 6  $\mu$ L of 5x RT buffer, 10 mM dithiothreitol, 0.5 mM deoxynucleotides, 50 U of RNase inhibitor, and 240 U of reverse transcriptase (Invitrogen). The RT reaction was carried out at 40°C for 70 min followed by heat inactivation at 95°C for 3 min. The tested genes and the internal control ( $\beta$ -actin) were amplified by RT-PCR using 2  $\mu$ L RT products from each sample in a 20  $\mu$ L reaction containing Taq polymerase (0.01 U/ml), dNTPs (100 mM), MgCl<sub>2</sub> (1.5 mM) and buffer (50 mM Tris-

HCl). Rt-PCR reactions consisted of a first denaturing cycle at 97°C for 5 min, followed by a variable number of cycles of amplification, consisting of denaturation at 96°C for 30 sec, annealing for 30 sec, and extension at 72°C for 1 min. A final extension cycle of 72°C for 15 min was included. Annealing temperature was adjusted for each target: 60°C for P53 and 55°C for BAX and  $\beta$ -actin. A control reaction without reverse transcriptase was included for every sample of RNA isolated to verify the absence of contamination. PCR products (10  $\mu$ l) were electrophoresed on 2% agarose gels containing 100 ng/ml ethidium bromide, and photographed with a Polaroid camera under ultraviolet illumination.

### **2.11 Histological studies**

Histological examination of stomach samples was carried out by routine histological procedures. Tissue fixation was carried out, immediately after the experimental procedure, with 10% neutral buffered formaldehyde solution (pH 7.0). Processing was carried out as per the schedule for dehydration, clearing and paraffin infiltration, and then the collected tissue was embedded in paraffin. Finally, 5  $\mu$ m sections were cut and mounted on clean glass slides coated with Mayer's egg albumin.

### **2.12 Statistical Analysis**

Statistical analysis was performed using Graphpad Prism Statistical Software package (version 6). Data was presented as means with their standard deviations (mean $\pm$ SD). Normality and homogeneity of the data were confirmed before ANOVA. Differences among the experimental groups were assessed by one-way ANOVA followed by Tukey's test.

## **III. Results**

### **3.1 Results of gastric specimens of control groups of rats: (Figure 1)**

Our results show normal gastric mucosa with no evidence of ulceration in control group (A), control+IND+CoQ10 group (D) and control+IND+quercetin+CoQ10 group (E). Large hemorrhagic ulcerated areas of different length were seen in control+IND group (B). Fewer small to moderate ulcers were seen in control+IND+quercetin (C).

### **3.2 Assessment of gastric specimens obtained from diabetic group of rats: (Figure 2)**

Normal gastric mucosa with no evidence of ulceration was seen in control DM1 group (A) and DM1+IND+Quercetin+CoQ10 group (E). Large haemorrhagic ulcerated areas of different length were seen in DM1+IND (B). Fewer small to moderate ulcers were seen in DM1+IND+quercetin (C) and DM1+IND+CoQ10 groups (D).

### **3.3 Results of ulcer index: (Figure 3)**

Our results show that there was significant increase in gastric ulcer index in normal+IND and DM1+IND groups when compared to control normal and control DM1 groups of rats respectively.

CoQ10 or Quercetin treatment alone or combined treatment of both caused significant decrease in gastric ulcer index in normal+IND and DM1+IND when compared to control normal or normal+IND groups and control+IND or DM1+IND. The combined treatment of both CoQ10 and quercetin in DM1+IND caused more significant decrease in ulcer index when compared to control DM1, DM1+IND, DM1+IND+CoQ10 and DM1+IND+Quercetin which indicated synergistic effect of both drugs together.

### **3.4 Results of oxidative stress markers**

The levels of MDA, SOD and iNOS were shown in figure (4), figure (5) and figure (6) respectively. Our results show significant increase in MDA and iNOS with concomitant decrease in SOD in normal+IND and DM1+IND groups when compared to control normal and control DM1 groups.

Treatment with Quercetin or CoQ10 or combined treatment of both in normal+IND or DM1+IND groups caused significant decrease in MDA and iNOS and significant increase in SOD when compared to normal+IND or DM1+IND groups. The combined treatment of both quercetin and CoQ10 caused the most significant decrease in MDA and iNOS and increased in SOD, which indicate synergistic effect of both drugs.

### **3.5 Results of inflammatory markers**

The levels of IL-6 and TNF- $\alpha$  are shown in figure (7) and figure (8) respectively. Our results shows significant increase in IL-6 and TNF- $\alpha$  in normal+IND and DM1+IND when compared to control normal and control DM1. There were significant increase in both marker in control DM1 when compared to control normal. The treatment of normal+IND and DM1+IND with quercetin and/or CoQ10 caused significant decrease in IL-6

and TNF- $\alpha$  when compared to normal+IND and DM1+IND. The combined treatment of both quercetin and CoQ10 caused the most significant decreased in their levels.

### **3.6 Levels of P53 and BAX mRNA**

Figure (9) shows semi quantitative reverse transcription PCR product and relative expression of gastric tissue mRNA P53 and BAX in reference to B actin mRNA. We found that P53 and BAX mRNA in control normal and DM1 were barely detectable. It was noteworthy that the level of P53 mRNA and BAX mRNA increased in normal+IND group and DM1+IND group. Their levels decreased with treatment with CoQ10 and/or quercetin when compared to control+IND or DM1+IND respectively, but still consistently elevated when compared to normal control or control diabetic. We found that the combined treatment of CoQ10 and quercetin in normal control+IND and DM1+IND caused the most significant decrease in the levels of P53 mRNA and BAX mRNA and even though normalized these apoptotic markers.

### **3.7 Microscopic pictures of gastric tissue obtained from control groups of rats received various form of treatment: (Figure 10)**

Normal gastric mucosa was seen in control normal group (A). Focal sloughing of almost whole thickness of mucosa surrounded by mild oedema and polymorphonuclear leukocyte (PNL) infiltration was seen in normal+IND group (B). Normal+IND+Quercetin group (C) and normal+IND+CoQ10 group (D) show evidence of very superficial gastric erosion of the mucosa. Almost normal gastric mucosa was seen in normal+IND+quercetin+Q10 group (E).

### **3.8 Microscopic pictures of gastric tissue obtained from diabetic groups of rats received various form of treatment: (Figure11)**

Control DM1 group (A) shows normal gastric mucosa. DM1+IND group (B) shows extensive loss of gastric mucosa and submucosa giving rise to deep ulcer, the floor of which is formed by muscularis propria. The surrounding gastric mucosa shows evidence of acute inflammatory reaction, hyperemia, edema and atrophy of some gastric glands. DM1+IND+quercetin (C) and DM1+IND+CoQ10 (D) groups show that the mucosa shows evidence of superficial ulceration with mild inflammatory reaction comparable to specimen (B). DM1+IND+Quercetin+CoQ10 group (D) shows almost normal gastric mucosa.

## **IV. Discussion**

Owing to increased rate of diabetes mellitus in human population, related complications like gastroparesis, intestinal enteropathy have become common. Although the incidence of gastric ulcer in diabetic patients is paradoxically low, ulcers that occur often become severe leading to gastrointestinal bleeding [4].

In the present study, gastric ulcers in rats were induced by IND, and we studied the gastroprotective effect of quercetin, CoQ10 and combined quercetin and CoQ10 in normal and type I diabetic rats exposed to IND-induced gastric ulceration.

We observed the absence of hemorrhagic ulcerative areas by macroscopical examination in control normal and diabetic rats. Vador et al. [1] found that in normal rats 16 h fasting caused no macroscopic damage or hemorrhagic lesions whereas, 16 h fasting in diabetic rats caused hemorrhagic gastric lesion in the glandular part of the stomach. So fasting depletes gastric mucus glycoprotein, and this depletion may be involved in the pathogenic mechanism of the formation of gastric mucosal lesions [23].

IND is one of NSAIDs have been widely used clinically as anti-inflammatory and analgesic agents. We observed that administration of IND in normal and diabetic rats caused multiple ulcerations with hemorrhage by gross examination along with significant increase in gastric ulcer index as compared with control rats. These results were in agreement with previous studies [9,16,24]. Moreover, these results were confirmed by histopathological examination of gastric mucosa in IND administered rats which showed necrosis of mucosa, exposed muscularis mucosa, and congestion of blood vessels.

The study of Konturek et al. [25] demonstrated that the number of stress lesions in diabetes rats were significantly higher than in non-diabetic rats indicating an increased susceptibility of gastric mucosa to stress lesions under diabetic conditions.

The study of Owu et al. [24] found that the photomicrographs of the gastric mucosa of normal and diabetic rats show that parietal cells are irregularly scattered and show some areas of necrosis in diabetic compared to normal rats. In addition, the epithelial cells appear well defined in the normal but broken and much more scattered in the diabetic rats. Lesions of the gastric mucosa in diabetes have previously been reported to include desquamation of the surface epithelium with diffuse and severe hemorrhage with localized erosion [26].

The ulceration induced by IND is attributed mainly to various processes, including generation of reactive oxygen species, initiation of lipid peroxidation, decreasing the levels of antioxidant parameters, infiltration of leukocytes, induction of apoptosis, and inhibition of prostaglandin E2 synthesis, nitric oxide level

and epithelial cell proliferation in the ulcer margin, which is critical for the reepithelization of the ulcer crater [27]. Decreased prostaglandin level, due to block of cyclooxygenase (COX) activity, impairs almost all aspects of gastroprotection as lower mucus and bicarbonate secretion, decreased mucosal blood flow, neutrophil infiltration, microvascular structural disruption, and increases acid secretions which, in turn, aggravate the ulcer [28].

Singh et al. [4] speculate that high glucose and ulcerogens treatment generates excessive ROS.

On the other hand, pretreatment of IND-administered to normal and diabetic rats with quercetin or CoQ10 or combined quercetin and CoQ10 significantly decreased the gastric ulcer index and the number of ulcers but the effect of CoQ10 was more than quercetin. Among the three treatments tested, co-administration of quercetin and CoQ10 showed the best effect in reducing the gastric ulcer index. In addition, the combined treatment had more reducing effect in normal rats compared to diabetic rats.

We also observed the absence of hemorrhagic ulcerative areas by macroscopical examination in IND+Qur+CoQ10 treated normal and diabetic rats.

In our study we found that diabetes caused a significant increase in the mucosal lipid peroxidation product (malondialdehyde MDA) levels as compared to normal control (non-diabetic) rats and a significant decrease in the mucosal antioxidant enzyme levels (SOD). This result is agreement with the study of Vador et al. [1].

ROS like superoxide radical anions and hydroxyl radicals are now considered one of the major causative factors for mucosal lesions through oxidative stress. The radicals promote mucosal damage by causing degradation of the epithelial basement membrane components, complete alteration of the cell metabolism and DNA damage [29]. GSH and CAT (antioxidant enzymes) scavenges the free radicals, thereby preventing ROS mediated gastric damage. They also maintain mucosal integrity and were selected as the marker for ROS mediated gastric damage. Diabetes caused a significant decrease in the GSH and CAT levels. Thus decrease in the antioxidant enzymes levels is also one of the mechanisms of gastric ulcer formation in diabetes [1].

The study of Vador et al. [1] is the first attempt to understand the pathogenesis of gastric ulcer. They found an imbalance in the mitochondrial redox state of the cell and lead to excess formation of reactive oxygen species (ROS). Increased oxidative stress within the cell leads to activation of the poly (ADP-ribose) polymerase (PARP) pathway, which regulates the expression of genes involved in promoting inflammatory reactions.

The prevention of oxidative damage in DM by the use of quercetin, a potent antioxidant flavonoid, or CoQ10 is one of the most important findings of our study. This result is in agreement with Kahraman et al. [13], Edremitlioğlu et al. [14] and El-Abhar [30].

Quercetin is known to be a potent antioxidant and has been shown to influence enzymes involved in scavenging reactive oxygen species in vitro and in vivo experiments [31].

The study of Gonzalez-Segovia et al. [32] observed that quercetin administration induced a decrease in lipid peroxidation in the pyloric antrum of infected animals. This finding could be a result of decreased neutrophil leukocyte infiltration and free radicals of neutrophil leukocytes in this gastric region. It is also conceivable that the antioxidant property of quercetin is involved in the decrease of lipid peroxidation, as suggested by Martín et al. [33] who described a decreased index of lipid peroxidation in gastric injury caused by ethanol. In these studies no changes were noted in neutrophil leukocyte infiltration.

The possible reason for this could be attributed to antioxidant property of quercetin that protects the gastric mucosa against oxidative stress associated with diabetes mellitus. Gohlke et al. [34] observed that plasma glucose level decreased and increased insulin release and insulin sensitivity under quercetin administration.

In El-Abhar [30] study, CoQ10 hindered indomethacin-induced ulcer formation and vascular permeability, elevated prostaglandin E2, restored the disturbed redox status and boosted nitric oxide level; however, it failed to increase mucus content significantly.

In fact, CoQ10 in the current work replenished the major antioxidant molecule in the gastric mucosa that was depleted by indomethacin administration, an effect that is in line with a previous study [16, 30]. Moreover, this ubiquinone has electron donating property that inhibits the decrease in SOD in gastric tissue (replenish endogenous antioxidants), hence justifying the preservation of mucosal glutathione levels and inhibiting lipid peroxidation and thereby stabilizes biological membranes, so it is essential for the health of all human tissue and organs. Since mucus production, rapid gastric cell turnover, as well as complete barrier function repair are highly energy dependent processes, thus it is emphasized that adequate energy, besides an intact mitochondria offered by the higher doses of CoQ10, are needed to combat gastric ulceration [35].

We found that diabetes resulted in a significant increase of plasma IL-6, TNF- $\alpha$  and iNOS levels. This is agreement with Demir et al. [36] who found that quercetin reduced plasma IL-6 and TNF- $\alpha$  to the levels those in non-diabetic animals. Therefore, we assumed that quercetin acts as an immunomodulator rather than an immunosuppressant in diabetic rats.

Previous study [4] had demonstrated that TNF- $\alpha$  & IL-1b were increased significantly in ulcerated diabetic gastric tissues compared with non-diabetic.

TNF- $\alpha$  is a proinflammatory cytokine, which induces severe inflammatory reaction leading to gastric damage. Histopathology of stomach of diabetic rats showed the presence of heavy infiltrates of neutrophils. Neutrophils have been reported to stimulate TNF- $\alpha$  activity [1].

In addition, we demonstrated that the levels of TNF- $\alpha$ , IL-6 and iNOS increased in diabetic gastric tissues which were elevated further upon exposure to indomethacin. This result is agreement with Singh et al. [4] who found that indomethacin upregulated the expression of TNF- $\alpha$  and IL-1 $\beta$  in the gastric tissues of diabetic rat compared with non-diabetic ones.

It is now well-recognized that the enhanced generation of NO by the iNOS may contribute to the pathogenesis of various gastroduodenal disorders including peptic ulcer [10]. High concentrations of NO may be detrimental by promoting inflammation via mucosal swelling and epithelial damage. An increase in iNOS activity and a decrease in eNOS activity in the gastric mucosa are closely related to the development of gastric mucosal lesions. Currently we confirmed that the indomethacin-induced gastric ulceration increased the mucosal iNOS expression, but reduced the eNOS expression in mice. This suggested that the iNOS-mediated NO was primarily responsible for indomethacin-induced gastric ulceration, caused by indomethacin.

Herein, quercetin & CoQ10 significantly decreased the levels of TNF- $\alpha$ , IL-6 and iNOS during protection of gastric ulcer.

Quercetin or CoQ10 treatment significantly reduced TNF- $\alpha$  level and thus prevented TNF- $\alpha$  mediated gastric mucosal damage.

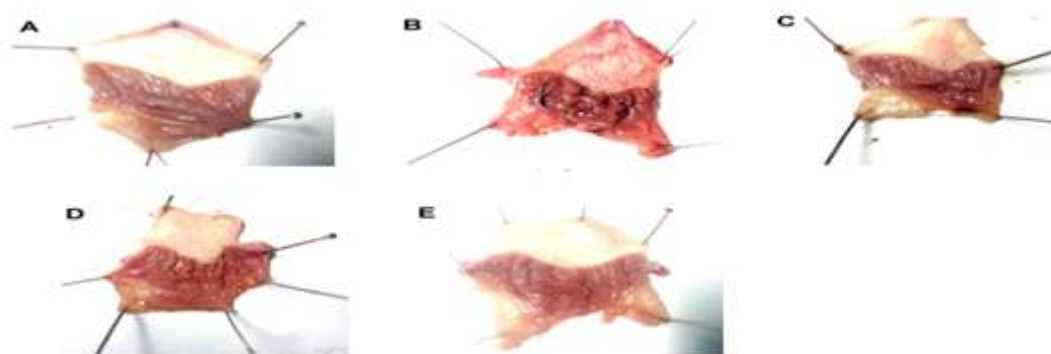
Quercetin has a direct anti-inflammatory property through degradation of the I $\kappa$ B $\alpha$  factor, preventing NF- $\kappa$ B nuclear translocation, as a result of the decreased genetic expression and production of relevant inflammatory mediators such as TNF- $\alpha$ , IL-1 $\beta$ , IL-6, and IL-8, as suggested by Min et al. [37] and Ruiz et al. [38].

ROS trigger apoptosis via oxidation of mitochondrial inner membrane phospholipid cardiolipin. Cardiolipin is essential for maintaining mitochondrial architecture and membrane potential and for providing support to proteins involved in mitochondrial bioenergetics [39]. Cytochrome c is anchored to the outer surface of the inner mitochondrial membrane by electrostatic and hydrophobic interactions with cardiolipin. During the early phase of apoptosis, mitochondrial ROS production is stimulated, and cardiolipin is oxidized. This destabilizes the interaction with cytochrome c, which then detaches from the membrane and is released into the cytoplasm through pores in the outer membrane. Cytochrome c release from mitochondria is a key step in the initiation of apoptosis [40, 41].

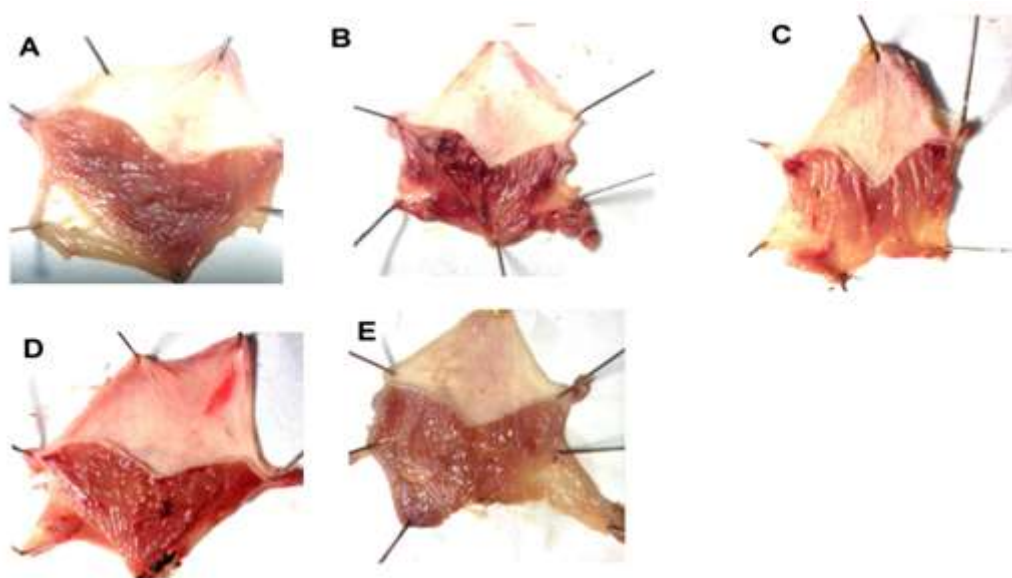
In our study, we demonstrated that indomethacin upregulated expressions of BAX and p53 in the gastric tissues of diabetic rat compared with non-diabetic ones. Quercetin & CoQ10 significantly attenuated their expressions.

CoQ10 possesses antiapoptotic activity [42] preserving thus gastric epithelial cells that secrete more mucus hampering gastric ulceration, as indomethacin gastropathy has been previously linked to programmed cell death [16].

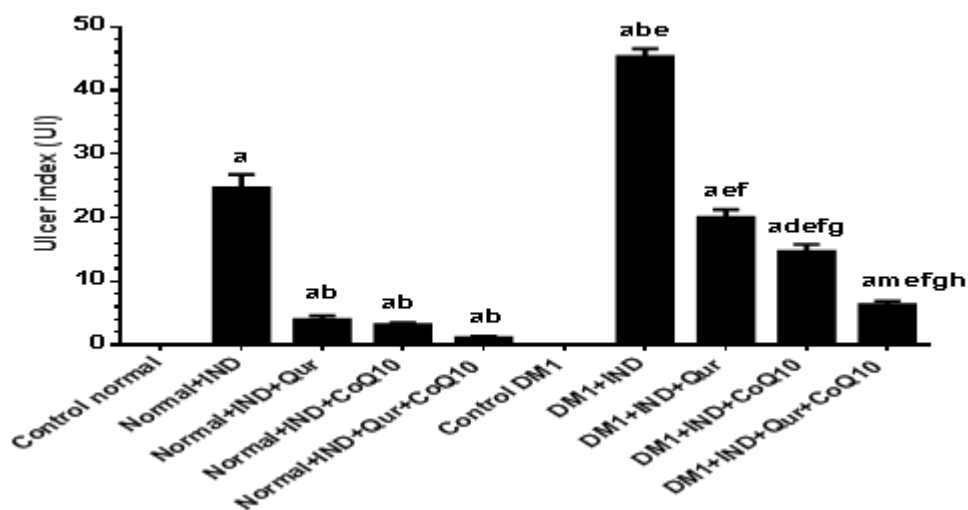
## V. Figures And Tables



**Figure 1:** Assessment of gastric ulcer lesions in the stomachs of Normal groups of rats (A) Control group. (B) Normal+IND group. (C) Normal+IND+Qur treated rats. (D) Normal+IND+CoQ10 treated rats. (E) Normal+IND+Qur+CoQ10 treated rats.

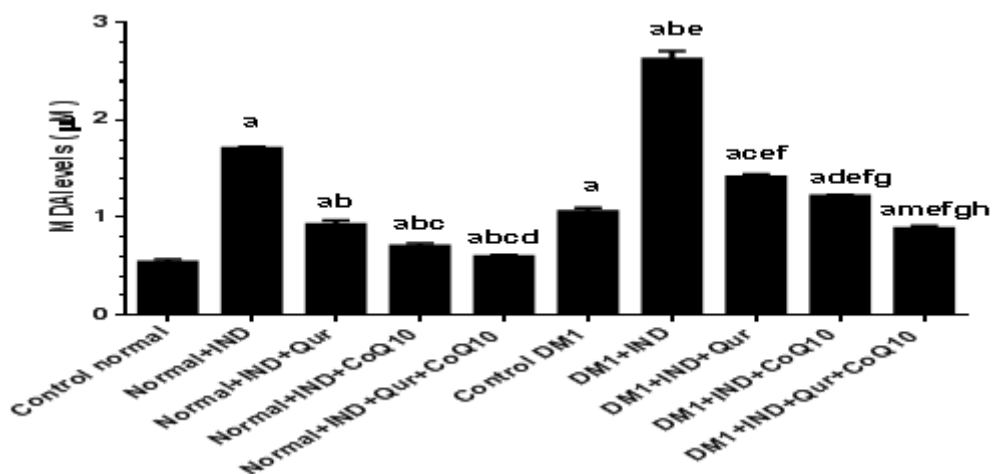


**Figure 2:** Assessment of gastric ulcer lesions in the stomachs of Diabetic groups of rats (A) Control diabetic group. (B) DM1+IND group. (C) DM1+IND+Qur treated rats. (D) DM1+IND+CoQ10 treated rats. (E) DM1+IND+Qur+CoQ10 treated rats.

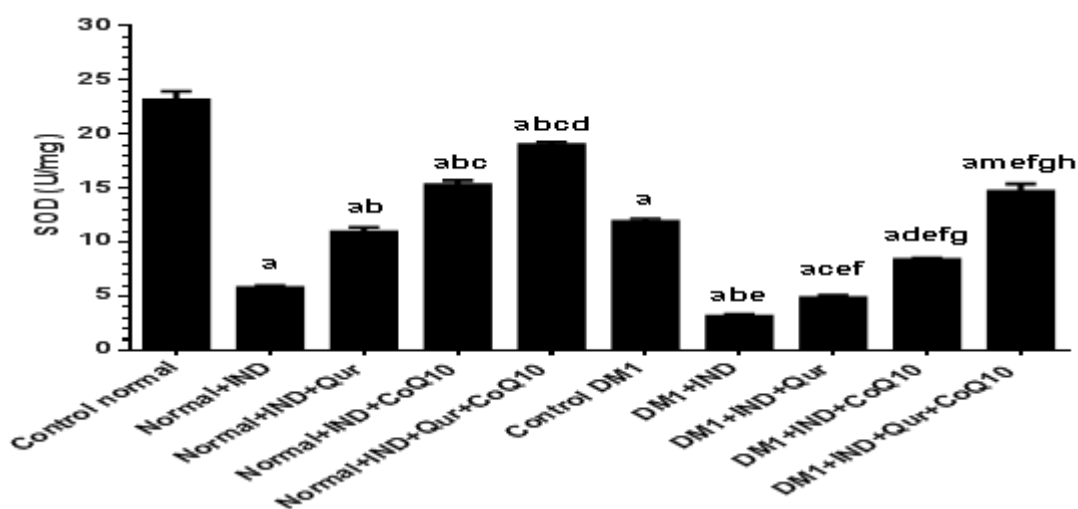


**Figure 3:** Ulcer index (UI) of stomachs obtained from all groups of rats. Values are expressed as Mean  $\pm$  SD for 8 rats in each group. Values were considered significantly different at  $P < 0.05$ . <sup>a</sup>Significantly different when compared to control normal group. <sup>b</sup>Significantly different when compared to Normal+IND group. <sup>c</sup>Significantly different when compared to Normal+IND+Qur. <sup>d</sup>Significantly different when compared to Normal+IND+CoQ10. <sup>e</sup>Significantly different when compared to Normal+IND+Qur+CoQ10. <sup>f</sup>Significantly different when compared to Control DM1. <sup>g</sup>Significantly different when compared to DM1+IND. <sup>h</sup>Significantly different when compared to DM1+IND+Qur. <sup>i</sup>Significantly different when compared to DM1+IND+CoQ10.

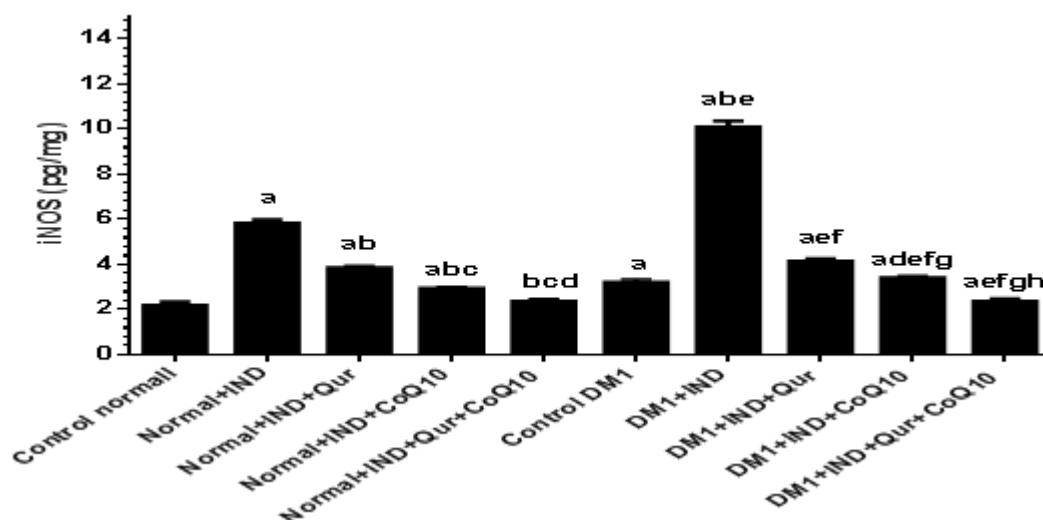




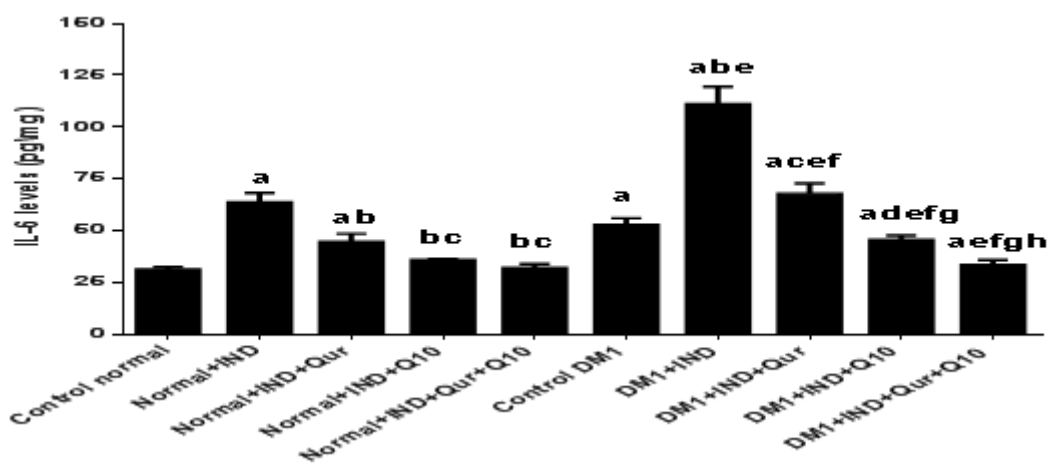
**Figure 4:** Levels of MDA in gastric homogenates of all groups of rats. Values are expressed as Mean  $\pm$  SD for 8 rats in each group. Values were considered significantly different at  $P < 0.05$ . <sup>a</sup>Significantly different when compared to control normal group. <sup>b</sup>Significantly different when compared to Normal+IND group. <sup>c</sup>Significantly different when compared to Normal+IND+Qur. <sup>d</sup>Significantly different when compared to Normal+IND+CoQ10. <sup>m</sup>Significantly different when compared to Normal+IND+Qur+CoQ10. <sup>e</sup>Significantly different when compared to Control DM1. <sup>f</sup>Significantly different when compared to DM1+IND. <sup>g</sup>Significantly different when compared to DM1+IND+Qur. <sup>h</sup>Significantly different when compared to DM1+IND+CoQ10.



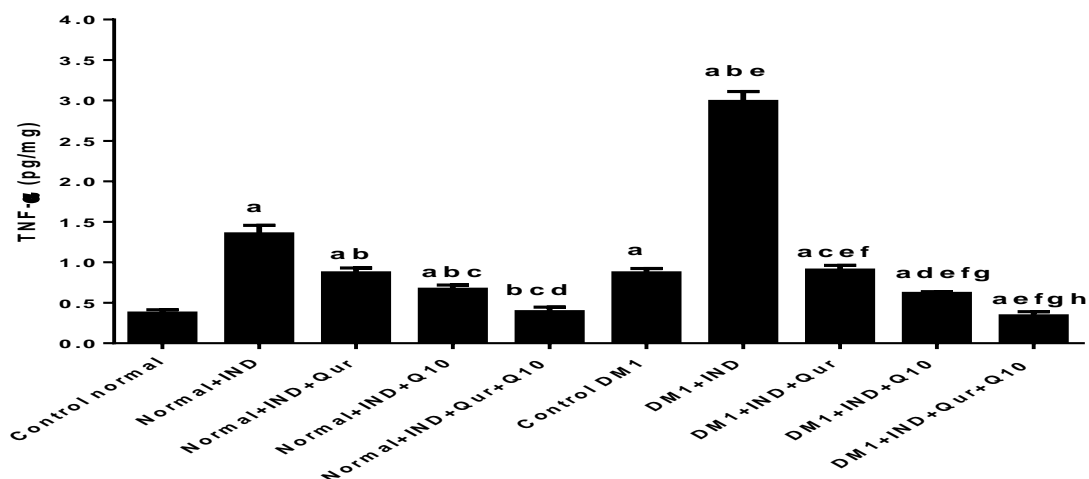
**Figure5:** Levels of superoxide dismutase (SOD) in gastric homogenates of all groups of rats. Values are expressed as Mean  $\pm$  SD for 8 rats in each group. Values were considered significantly different at  $P < 0.05$ . <sup>a</sup>Significantly different when compared to control group. <sup>a</sup>Significantly different when compared to control normal group. <sup>b</sup>Significantly different when compared to Normal+IND group. <sup>c</sup>Significantly different when compared to Normal+IND+Qur. <sup>d</sup>Significantly different when compared to Normal+IND+CoQ10. <sup>m</sup>Significantly different when compared to Normal+IND+Qur+CoQ10. <sup>e</sup>Significantly different when compared to Control DM1. <sup>f</sup>Significantly different when compared to DM1+IND. <sup>g</sup>Significantly different when compared to DM1+IND+Qur. <sup>h</sup>Significantly different when compared to DM1+IND+CoQ10.



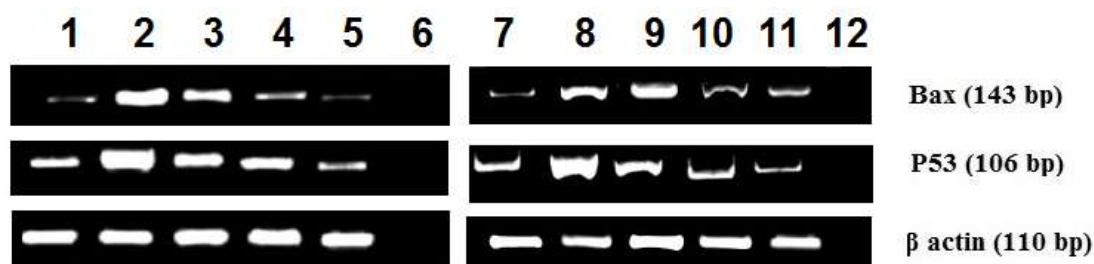
**Figure 6:** Levels of inducible nitric oxide synthase (iNOS) in gastric homogenates of all groups of rats. Values are expressed as Mean  $\pm$  SD for 8 rats in each group. Values were considered significantly different at  $P < 0.05$ . . <sup>a</sup>Significantly different when compared to control normal group. <sup>b</sup>Significantly different when compared to Normal+IND group. <sup>c</sup>Significantly different when compared to Normal+IND+Qur. <sup>d</sup>Significantly different when compared to Normal+IND+CoQ10. <sup>m</sup>Significantly different when compared to Normal+IND+Qur+CoQ10. <sup>e</sup>Significantly different when compared to Control DM1. <sup>f</sup>Significantly different when compared to DM1+IND. <sup>g</sup>Significantly different when compared to DM1+IND+Qur. <sup>h</sup>Significantly different when compared to DM1+IND+CoQ10.



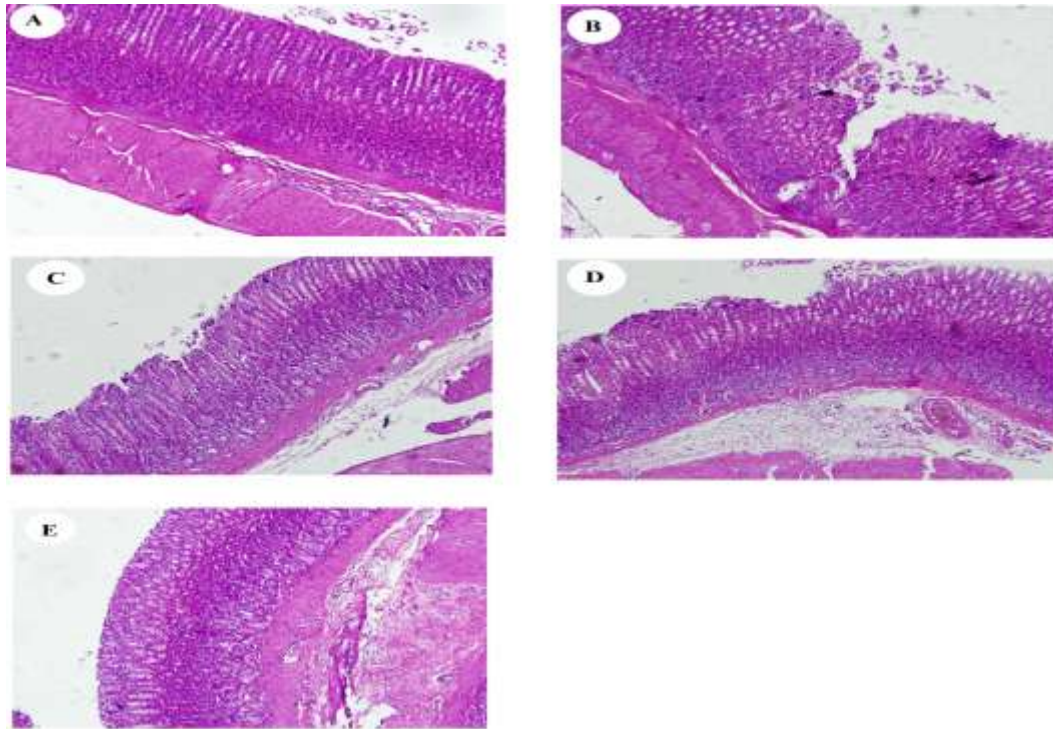
**Figure 7:** Levels of interleukin 6 (IL-6) in gastric homogenates of all groups of rats. Values are expressed as Mean  $\pm$  SD for 8 rats in each group. Values were considered significantly different at  $P < 0.05$ . <sup>a</sup>Significantly different when compared to control normal group. <sup>b</sup>Significantly different when compared to Normal+IND group. <sup>c</sup>Significantly different when compared to Normal+IND+Qur. <sup>d</sup>Significantly different when compared to Normal+IND+CoQ10. <sup>m</sup>Significantly different when compared to Normal+IND+Qur+CoQ10. <sup>e</sup>Significantly different when compared to Control DM1. <sup>f</sup>Significantly different when compared to DM1+IND. <sup>g</sup>Significantly different when compared to DM1+IND+Qur. <sup>h</sup>Significantly different when compared to DM1+IND+CoQ10.



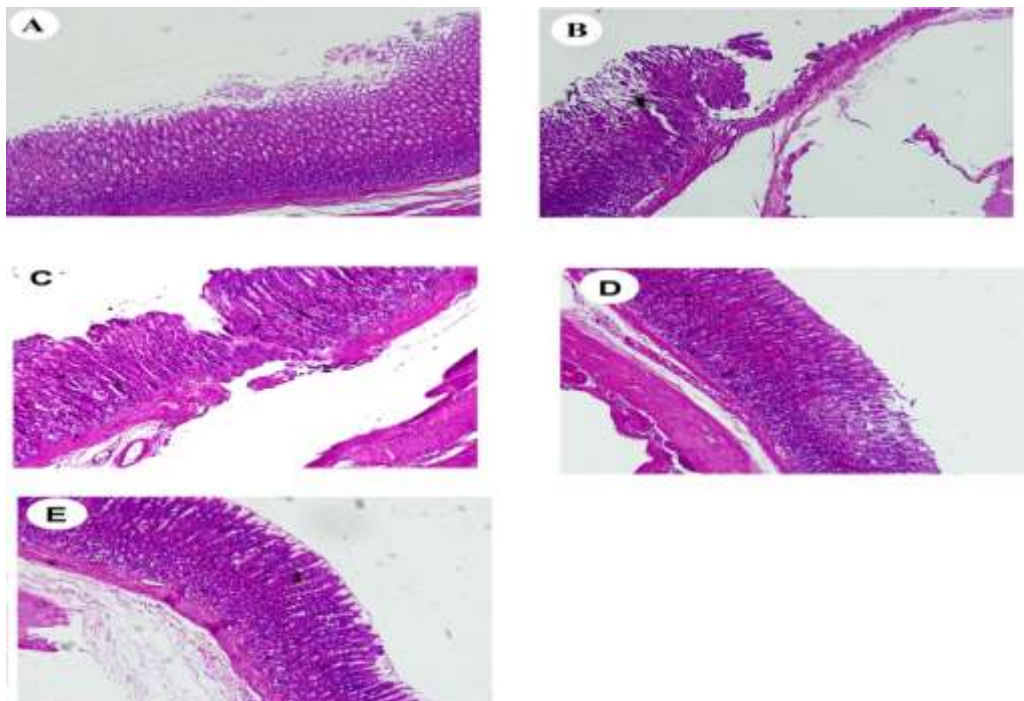
**Figure 8:** Levels of tumor necrosis factor- $\alpha$  (TNF- $\alpha$ ) in gastric homogenates of all groups of rats. Values are expressed as Mean  $\pm$  SD for 8 rats in each group. Values were considered significantly different at  $P < 0.05$ . .  
<sup>a</sup>Significantly different when compared to control normal group. <sup>b</sup>Significantly different when compared to Normal+IND group. <sup>c</sup>Significantly different when compared to Normal+IND+Qur. <sup>d</sup>Significantly different when compared to Normal+IND+CoQ10. <sup>m</sup>Significantly different when compared to Normal+IND+Qur+CoQ10. <sup>e</sup>Significantly different when compared to Control DM1. <sup>f</sup>Significantly different when compared to DM1+IND. <sup>g</sup>Significantly different when compared to DM1+IND+Qur. <sup>h</sup>Significantly different when compared to DM1+IND+CoQ10.



**Figure 9:** Semiquantitative reverse transcription PCR products and relative expression of gastric tissue mRNA of p53 and BAX in reference to  $\beta$ -actin mRNA (housekeeping gene). The RT-PCR products obtained from all groups were separated by 2 % agarose gel electrophoresis with 100 ng/ml ethidium bromide. **1:** Control normal group, **2:** Normal+IND group. **3:** Normal+IND+Qur. **4:** Normal+IND+CoQ10. **5:** Normal+IND+Qur+CoQ10. **7:** Control DM1, **8:** DM1+IND group. **9:** DM1+IND+Qur. **10:** DM1+IND+CoQ10. **11:** DM1+IND+Qur+CoQ10. 6 and 7 are negative control were reverse transcriptase was omitted.



**Figure 10:** Photomicrographs of gastric tissue obtained from the normal groups of rats received vehicle or various treatments. (A) were taken from Control normal group. (B) was taken from Normal+IND group. (C) was taken from Normal+IND+Qur. (D) was taken from Normal+IND+CoQ10. (E) was taken from Normal+IND+Qur+CoQ10. H&E stain (200X)



**Figure 11:** Photomicrographs of gastric tissue obtained from the Diabetic groups of rats received vehicle or various treatments. (A) were taken from Control DM1 group. (B) was taken from DM1+IND group. (C) was taken from DM1+IND+Qur. (D) was taken from DM1+IND+CoQ10. (E) was taken from DM1+IND+Qur+CoQ10. H&E stain (200X).

## VI. Conclusion

In summary, we documented that gastric ulcers in diabetic rats are severe and we have found that experimental diabetes aggravates acute indomethacin-induced gastric lesions via mechanism involving an increase in expression and release of proinflammatory cytokines such as TNF- $\alpha$  and IL-6.

We conclude that quercetin and CoQ10 are effective in protection against indomethacin-induced gastric ulcers though their actions under diabetic conditions seems to be attenuated, possibly due to reduction in SOD and increased MDA and the release of proinflammatory cytokines (IL-6 & TNF- $\alpha$ ), iNOS and apoptotic markers (BAX & p53) in diabetic conditions.

Our data demonstrated that treatment with quercetin and CoQ10 can prevent indomethacin-induced gastric ulceration in rats, by a number of distinct mechanisms. It was found that they can significantly reduce various inflammatory modulators including IL-6, TNF- $\alpha$  as well as iNOS. These, along with their ability to strengthen the mucosal defense system by augmenting antioxidants, gastric mucin, and PGE<sub>2</sub>, might be responsible for the excellent ulcer protection action of quercetin and CoQ10. Treatment with CoQ10 showed more protection than quercetin. Combined treatment showed complete protection.

## References

- [1]. Vador N, Jagtap AG, and Damle A, Vulnerability of Gastric Mucosa in Diabetic Rats, Its Pathogenesis and Amelioration by Cuminum cyminum, Indian Journal of Pharmaceutical Sciences, 74(5), 2012, 387-396.
- [2]. Mayty, P.; Biswas, K.; Roy, S.; Banerjee, R. K. and Bandyopadhyay, U., Smoking and pathogenesis of gastroduodenal ulcer-recent mechanistic update, Mol. Cell. Biochem., 253, 2003, 329-338.
- [3]. Calam, J. and Baron, J. H., Pathophysiology of duodenal and gastric ulcer and gastric cancer, Brit Med J., 323, 2001, 980-983.
- [4]. Singh LP, Sharma AV and Swarnakar S, Upregulation of collagenase-1 and -3 in indomethacin-induced gastric ulcer in diabetic rats: role of melatonin, J. Pineal Res, 51, 2011, 61-74.
- [5]. Bandyopadhyay, D.; Biswas, K.; Bhattacharyya, M.; Reiter, R.J. and Banerjee, R.K, Involvement of reactive oxygen species in gastric ulceration, protection by melatonin, Indian J. Exp. Biol., 40, 2002, 693-705.
- [6]. Mota KS, Dias GE, Pinto ME, Luiz-Ferreira A, Souza-Brito AR, Hiruma-Lima CA, Barbosa-Filho JM, and Batista LM., Flavonoids with gastroprotective activity, Molecules. 14(3), 2009, 979-1012.
- [7]. Morsy MA, Ashour OM, Fouad AA, and Abdel-Gaber SA, Gastroprotective effects of the insulin sensitizers rosiglitazone and metformin against indomethacin-induced gastric ulcers in Type 2 diabetic rats, Clin Exp Pharmacol Physiol. 37(2), 2010, 173-7.
- [8]. Prasad SV, Srinivas A, and Ambareesh K, Protective role oxiatard on drug induced ulcers in rats, Int J Biol Med Res, 3(3), 2012, 1948-1951.
- [9]. Kim JH, Kim BW, Kwon HJ, and Nam S-W, Curative effect of selenium against indomethacin-induced gastric ulcers in rats, J Microbiol Biotechnol 21(4), 2011, 400-404.
- [10]. Adhikary B, Yadav SK, Chand S, Bandyopadhyay SK, and Chattopadhyay S, Black tea and theaflavins suppress various inflammatory modulators and i-NOS mediated nitric oxide synthesis during gastric ulcer healing, Free Radic Res, 45(7), 2011, 767-78.
- [11]. Rao, C.V.; Govindarajan, S.K.O.R.; Rawat, A.K.S.; Mehrotra, S. and Pushpangadan, P, Quercetin, a bioflavonoid, protects against oxidative stress-related gastric mucosal damage in rats, Nat. Prod.Sci, 9, 2003, 68-72.
- [12]. Alarcon De La Lastra, C.; Martin, M.J.; and Motilva, V, Antiulcer and gastroprotective effects of quercetin., a gross and histologic study, Pharmacology, 48, 1994, 56-62.
- [13]. Kahraman, A.; Erkasap, N.; Koken, T.; Serteser, M.; Aktepe, F.; and Erkasap, S., The antioxidative and antihistaminic properties of quercetin in ethanol-induced gastric lesions, Toxicology, 183, 2003, 133-142.
- [14]. Edremitlioglu M, Andic MF, and Korkut O, Quercetin, a Powerful Antioxidant Bioflavonoid, Prevents Oxidative Damage in Different Tissues of Long-Term Diabetic Rats, Balkan Med J, 29, 2012, 49-55.
- [15]. Siemieniuk and Skrzydlewska, Coenzyme Q10: its biosynthesis and biological significance in animal organisms and in humans, Postepy Hig Med Dosw, 59, 2005, 150-9.
- [16]. Malash AM, Abdallah DM, Agha AM and Kenawy SA, Gastroprotective Efficacy of Coenzyme Q10 in Indomethacin-Induced Gastropathy: Other Potential Mechanisms, Ulcers. 2012, Article ID 957898, 7 pages.
- [17]. Kobayashi, Y., M. Miyazawa, A. Kamel, K. Abe, and T. Kojima, Ameliorative effects of mulberry (*Morus alba* L.) leaves on hyperlipidemia in rats fed a high-fat diet: Induction of fatty acid oxidation, inhibition of lipogenesis, and suppression of oxidative stress, Biosci. Biotechnol. Biochem. 74, 2010, 2385-2395.
- [18]. Venkova K, Earnest DL, and Meerveld BG, Protective Effect of Tegaserod against Indomethacin-Induced Gastric Injury in the Rat, The Open Pharmacology Journal, 2, 2008, 10-16.
- [19]. Eleawa, S. M., Alkhateeb, M., Ghosh, S., Al-Hashem, F., Shatoor, A. S., Alhejaily, A., and Khalil, M. A., Coenzyme Q10 protects against acute consequences of experimental myocardial infarction in rats, International Journal of Physiology, Pathophysiology and Pharmacology, 7(1), 2015, 1-13.
- [20]. Anjaneyulu M, Chopra K, and Kaur I, Antidepressant activity of quercetin, a bioflavonoid, in streptozotocin-induced diabetic mice, J Med Food, 6(4), 2003, 391-5.
- [21]. Chang KJ, Effect of taurine and beta alanine on morphological changes of pancreas in streptozotocin induced diabetic rats, Adv Exp Med Biol, 483, 2000, 571-7.
- [22]. Peskar BM, Ehrlich K and Peskar BA, Role of ATP-sensitive potassium channels in prostaglandin-mediated gastroprotection in the rat, J. Pharmacol. Exp. Ther., 301(3), 2002, 969-974.
- [23]. Igarashi S, Kume E, Narita H, and Kinoshita M, Food deprivation depletes gastric mucus glycoprotein in streptozotocin-induced diabetic rats, Jpn J Pharmacol, 84, 2000, 51-5.
- [24]. Owu DU, Obembe AO, Nwokocha CR, Edoho IE, and Osim EE, Gastric Ulceration in Diabetes Mellitus: Protective Role of Vitamin C, ISRN Gastroenterology, Jun 16, 2012, 7 pages;362805.
- [25]. Konturek PC, Brzozowski T, Burnat G, Szlachcic A, Koziel J, Kwiecien S, Konturek SJ, and Harsch IA, Gastric ulcer healing and stress-lesion preventive properties of pioglitazone are attenuated in diabetic rats, J Physiol Pharmacol, 61(4), 2010, 429-36.
- [26]. Verne GN and Sninsky CA, "Diabetes and the gastrointestinal tract," Gastroenterology Clinics of North America, 27(4), 1998, 861-874.

- [27]. Suleyman B, Halici Z, Odabasoglu F, and Gocer F, The effect of lacidipine on indomethacin induced ulcers in rats, *Int J Pharmacol*, 8(2), 2012, 115–121.
- [28]. Wallace, J.L., Prostaglandins, NSAIDs, and Gastric Mucosal Protection: why doesn't the stomach digest itself? *Physiol. Rev.* 88, 2008, 1547–1565.
- [29]. Schraufstatter I, Hyslop PA, Jackson JH, and Cochrane CG, Oxidant-induced DNA damage of target cells, *J Clin Invest*, 82, 1988, 1040–50.
- [30]. El-Abhar HS, Coenzyme Q10: a novel gastroprotective effect via modulation of vascular permeability, prostaglandin E, nitric oxide and redox status in indomethacin-induced gastric ulcer model. *Eur J Pharmacol*, Dec 15;649(1-3), 2010, 314–9.
- [31]. Jeong, S. M., M. J. Kang, H. N. Choi, J. H. Kim, and J. I. Kim, Quercetin ameliorates hyperglycemia and dyslipidemia and improves antioxidant status in type 2 diabetic db/db mice, *Nutr.Res. Pract.* 6, 2012, 201–207.
- [32]. Gonzalez-Segovia R, Quintanar J L, Salinas E, Ceballos-Salazar R, Aviles-Jimenez F and Torres-López J, Effect of the flavonoid quercetin on inflammation and lipid peroxidation induced by *Helicobacter pylori* in gastric mucosa of guinea pig, *J Gastroenterol*, 43, 2008, 441–447.
- [33]. Martín MJ, La-Casa C, Alarcon-de-la-Lastra C, Cabeza J, Villegas I, and Motilva V, Anti-oxidant mechanisms involved in gastroprotective effects of quercetin, *Z Naturforsch*, 53, 1998, 82–8.
- [34]. Gohlke A, Ingelmann CJ, Nürnberg G, Weitzel JM, H. M. Hammon, Görs S, Starke A, Wolfram S and Metges CC, Influence of 4-week intraduodenal supplementation of quercetin on performance, glucose metabolism, and mRNA abundance of genes related to glucose metabolism and antioxidative status in dairy cows, *J. Dairy Sci.* 96, 2013, 6986–7000.
- [35]. Samini S, Shafaroodi H, Shirazi-Beheshtiha SH, Mosavi Z, and Samini M, A Direct Comparison of Anti-ulcer Effects of Coenzyme Q10 and Vitamin C on Indomethacin-induced Gastric Ulcer in Rat: A Controlled Experimental Study, *Journal of Cardio-Thoracic Medicine*, 1(2), 2013, 34–40.
- [36]. Demir EA, Öz M, Alp Mİ, and Gergerlioğlu HS, Levels of IL-6 and TNF- $\alpha$  in diabetic rats: effect of quercetin, *Ibni Sina Journal of Medical Sciences*, 1(2), 2015, 27–31.
- [37]. Min YD, Choi CH, Bark H, Son HY, Park HH, Lee S, et al., Quercetin inhibits expression of inflammatory cytokines through attenuation of NF-kappaB and p38 MAPK in HMC-1 human mast cell line, *Infl amm Res.* 56, 2007, 210–5.
- [38]. Ruiz PA, Braune A, Hölzlwimmer G, Quintanilla-Fend L, and Haller D, Quercetin inhibits TNF-induced NF-kappaB transcription factor recruitment to proinflammatory gene promoters in murine intestinal epithelial cells, *J Nutr*, 137, 2007, 1208–15.
- [39]. Klingenberg M, Cardiolipin and mitochondrial carriers, *Biochimica et Biophysica Acta*, vol. 1788, no. 10, 2009, 2048–2058.
- [40]. Orrenius S and Zhivotovsky B, Cardiolipin oxidation sets cytochrome c free, *Nature Chemical Biology*, vol. 1, no. 4, 2005, 188–189.
- [41]. Ma ZA, Zhao Z, and Turk J, Mitochondrial dysfunction and  $\beta$ -cell failure in type 2 diabetes mellitus, *Exp Diabetes Res*, 2012, 2012:703538.
- [42]. Papucci L, Schiavone N, Witort E et al., Coenzyme Q10 prevents apoptosis by inhibiting mitochondrial depolarization independently of its free radical scavenging property, *Journal of Biological Chemistry*, vol. 278, no. 30, 2003, 28220–28228.