

## Periodontally Accelerated Osteogenic Orthodontics: A Surgical Technique and Case Report

Dr Jabir Ahmed Arakkal, Dr Nagarathna D.V and Bipina .p

A j institute of dental sciences department of periodontics kuntikana manglore 575004

---

**Abstract:** Corticotomy-assisted orthodontic treatment involves selective alveolar decortication in the form of decortication lines and grooves which is performed around the teeth that are desired to move orthodontically. This procedure is done to induce a state of increased bone turnover and, which will enhance in a faster rate of orthodontic tooth movement. This technique has several advantages, including faster tooth movement, shorter treatment time span, safer expansion of constricted arches, enhanced post-orthodontic treatment stability and extended envelope of tooth movement. This case report describes a surgical technique and case report involving periodontally accelerated osteogenic orthodontics.

---

### I. Introduction

Periodontally accelerated osteogenic orthodontic (PAOO) technique is defined as the orthodontic treatment combined with alveolar corticotomy along with bone augmentation grafting. As a promising adjuvant technique based on the transient nature of demineralization-remineralisation process in healthy tissues, PAOO consists of alveolar corticotomy and bone grafting of labial and palatal/lingual surfaces, followed by orthodontic force. Significant acceleration in orthodontic tooth movement has been extensively reported following a combination of selective alveolar decortications and bone grafting which is responsible for increased scope of tooth movement and long term improvement in periodontal health.

Main benefits of PAOO are reduced orthodontic treatment time, increased bone volume and post-orthodontic stability. The average orthodontic treatment time for adults is considerably longer than for adolescent patients, ranging from 18.7 to 31 months<sup>2-4</sup>. It is also more likely for adult patients to experience root resorption because of an aplastic, narrow, and less vascular periodontal membrane, as well as denser, avascular, and aplastic bone<sup>5</sup>. Surgically assisted orthodontic tooth movement has been used since the 1800s. Corticotomy-facilitated tooth movement was first described by L.C. Bryan in 1893, published in a textbook by S. H. Guilford<sup>6</sup>. In the past 50 years, rapid tooth movement without significant root resorption has been reported<sup>7-10</sup>.

In these cases, the total treatment time was reduced to one-third to one-fourth that of traditional non extraction and extraction orthodontic treatments<sup>10</sup>. The number of adult patients seeking orthodontic treatment has been increasing in the recent years. The efficiency of orthodontic tooth movement in these patients can be increased when well-planned force systems are applied to bony tissues that offer less resistance against the desired movement which results in faster orthodontic movement, treatment goals can be achieved in a shorter period, without compromising the results.

There are several differences between orthodontic treatment of adults and adolescents, being it psychological, biological and clinical differences. Adults have more specific objectives and concerns related to dentofacial aesthetics, the type of orthodontic appliance and the duration of treatment. An important factor of consideration in adult patients is that they are more prone to periodontal complications since their teeth are confined to thick mineralised alveolar bone.

The role of periodontics in PAOO is becoming important. It is important for the periodontics to know the details of procedure to fulfill the need of patients.

### II. Case Report

The patient, a 27-year-old female, was undergoing orthodontic treatment since one and half years, but the orthodontist couldn't close the space between 17 and 15, 27 and 25 within this time period. A decision was made to perform PAOO to accelerate the space closure during the treatment process.

Patient was referred to Dept of Periodontology, A.J Institute of Dental Sciences for further treatment.

#### Periodontal Treatment Procedure

In step one, oral prophylaxis was carried out using ultrasonic tips and recalled after 1 week to perform PAOO.

Pre-treatment analysis for the space was done using cephalometric tracing (Fig.2) and cast which was recorded in millimeters (Fig.1).

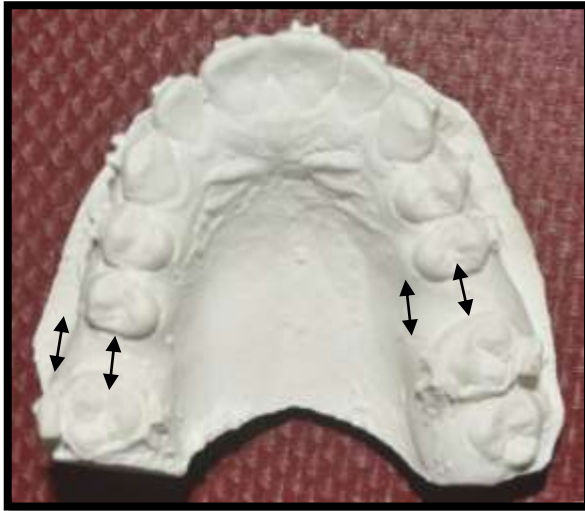


Fig.1 Pre surgery cast

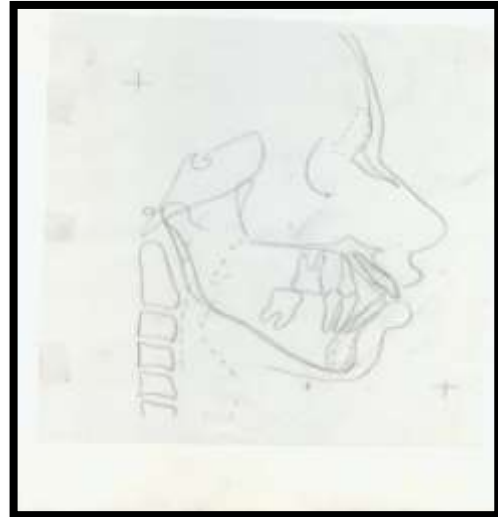

Fig.2 Pre surgery cephalometric analysis

**In step two PAOO was performed after 1 week.**

All surgical procedures were performed after obtaining the consent of the patient. After administration of local anesthesia 2 % lidocaine with adrenaline (1:100000), crevicular incision was given buccally extending from 15 to 25 (Fig.4). Full thickness mucoperiosteal flap was reflected beyond the apex of the teeth (Fig.5). Selective decortication was performed on buccal site (Fig.6). Vertical corticotomy cuts were made between the roots from 15 to 25 using a diamond round bur size 2mm in diameter, stopping just short of the alveolar crest (about 3mm). Cortical perforation was made at the selected areas to increase blood supply to graft. Grooves were filled with graft material (tata bone graft) (Fig.7) and (Fig.8). Closure was done with interrupted suture using 4-0 resorbable sutures (Fig.9). Surgical area was covered with periodontal pack (Fig.10). Post operative instructions were given with medication amoxicillin, 500 mg *t.i.d.* for 5 days and chlorhexidine mouth rinse 0.2% *b.i.d.* for 2 weeks. Ibuprofen as needed was prescribed for postoperative discomfort. Patient was recalled after 1 week for suture removal and reevaluation. Orthodontic appliance was activated after 1 week of the surgery.

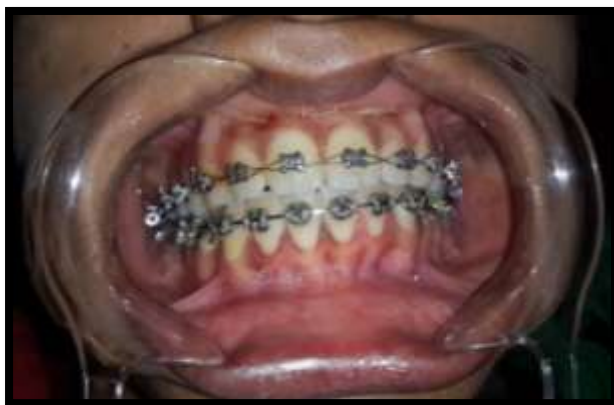

Fig.4

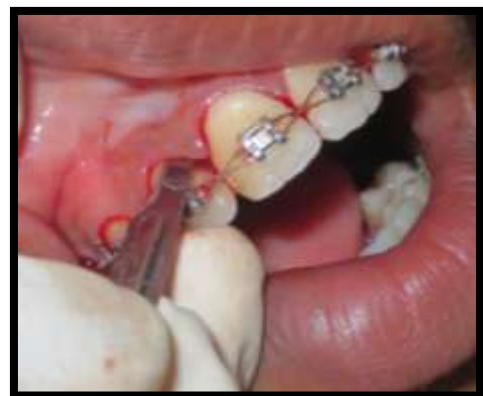

Fig.4 – crevicular incision given

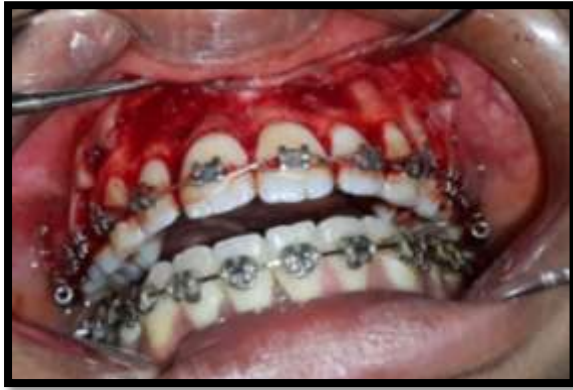

Fig.5- Full thickness mucoperiosteal flap elevated

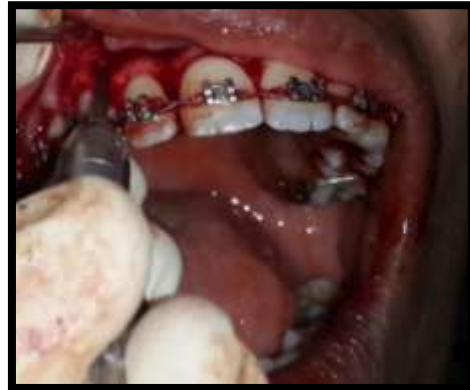

Fig.6-Vertical grooves



Fig.7 -Graft material

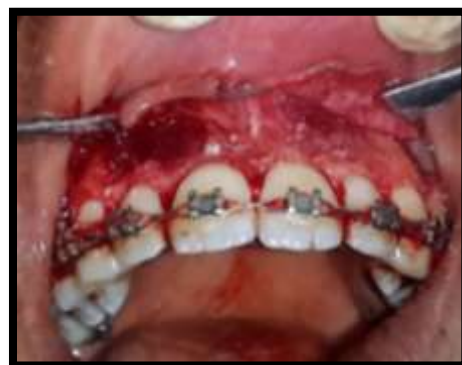

Fig.8-Graft material placed

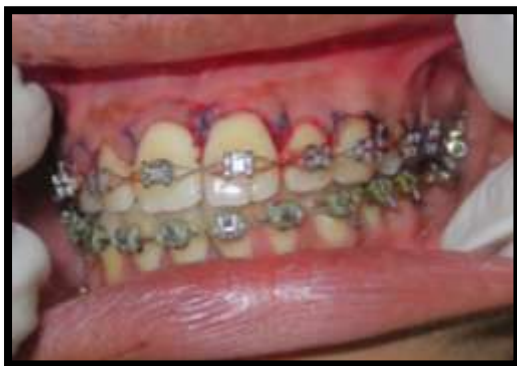

Fig.9- Suturing done

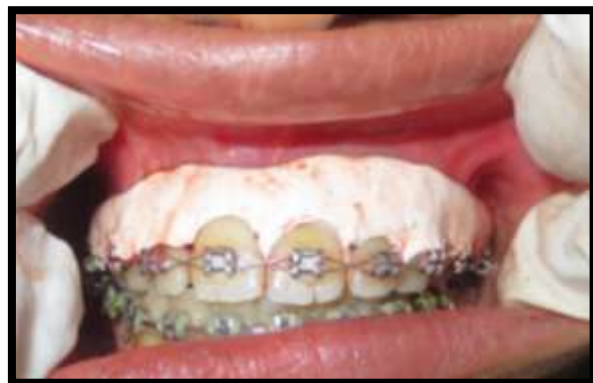

Fig.10- Placement of coe pack

In step three One week after surgery orthodontic treatment began.

Cephometric tracing and cast analysis for space closure between 17 and 15, 27 and 25 was done after four months. There was closure of **6.5mm** of space.

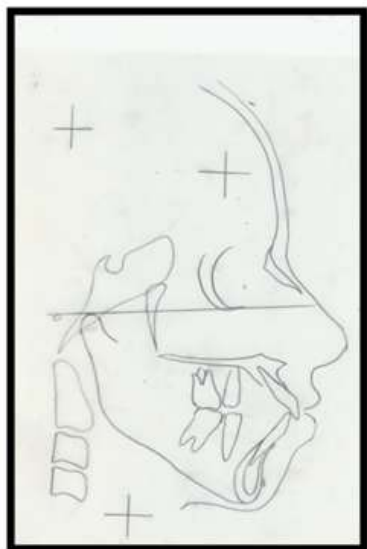


Fig.11 Post surgery analysis with

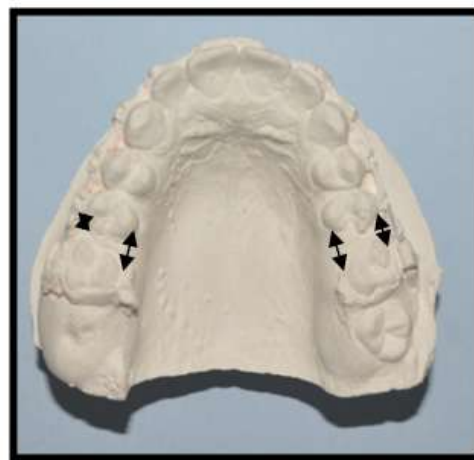

Fig.12 Post surgery analysis with cast after 4months cephalometric tracing after 4 months

### III. Discussion

Periodontally accelerated osteogenic orthodontic technique has been commonly used in conjunction with orthodontic treatment. The original technique is described by Kole<sup>7</sup> included a combined intra radicular corticotomy and supra apical osteotomy. later the supra apical osteotomy was replaced by corticotomy and labial and lingual corticotomy cuts were used to circumscribe the roots of the teeth.

Reduction of orthodontic therapy time is considered to be an important goal in management of malocclusion. Corticotomy has been proposed as an alternative to conventional orthodontic treatment in different adult case.

Hsuan-Chen Chang et al<sup>1</sup> reported that the complete retraction of anterior teeth combined with corticotomy in cases with severe maxillary protrusion took less than 3 and half months. In cases performed with PAOO it was observed dramatic changes in orthodontic time when bone responding to traumatic stimuli, bone tissue have a initial stage called regional accelerating phenomenon(RAP) characterized by a transient increase in the bone turn over and a decrease in trabacular bone density.

In this case study, a rapid space closure was achieved in 4 months. According to Hajji<sup>10</sup>, an average treatment time for the PAOO procedure was one-third to one-fourth of traditional orthodontic treatment. Wilcko et al<sup>11</sup> reported an average of 6.1 months of treatment time for the PAOO procedure. The present case result agreed with these observations. The present case is also in accordance with the procedures described by Köle and Wilcko et al<sup>4</sup>, corticotomy was performed only at the buccal aspects in this case. This was in agreement with Germec et al<sup>12</sup>, who reported rapid tooth movement when corticotomy was performed at the buccal aspects of alveolar bone.

This study adds a note on that the space closure or tooth movement which couldn't be achieved by the orthodontic treatment in one and half years of time period could be achieved by the PAOO technique at a shorter time period. Also this study indicates that PAOO is the better technique when orthodontist find difficulty in closing the space and moving the teeth.

### IV. Conclusion

Corticotomy facilitated orthodontics is an effective treatment alternative in adults with severe malocclusion to decrease treatment time and increase quality of treatment. The periodontics should choose appropriate surgical technique according to alveolar topography.

### References

- [1]. Hessam Nowzari, Frank Kazuo Yorita, and Hsuan-Chen Chang. Periodontally Accelerated Osteogenic Orthodontics Combined with Autogenous Bone Grafting. *Compendium* 2008; (4).
- [2]. Vig PS, Weintraub JA, Brown C, et al. The duration of orthodontic treatment with and without extractions: a pilot study of five selected practices. *Am J Orthod Dentofacial Orthop.* 1990;97(1):45-51.
- [3]. Kocadereli I. Changes in soft tissue profile after orthodontic treatment with and without extractions. *Am J Orthod Dentofacial Orthop.* 2002;122(1):67-72.
- [4]. Wilcko WM, Wilcko T, Bouquot JE, et al. Rapid orthodontics with alveolar reshaping: two case reports of decrowding. *Int J Periodontics Restorative Dent.* 2001;21(1):9-19.

- [5]. Reitan K. Biomechanical principles and reactions. In: Graber TM, Swain BF. Orthodontics: Current Principles and Techniques. St. Louis, MO: C.V. Mosby Company; 1985:101-192.
- [6]. Guilford SH. Orthodontia: Or Malposition of the Human Teeth,Its Prevention and Remedy. Philadelphia, PA: Spangler and Davis;1893.
- [7]. Köle H. Surgical operations on the alveolar ridge to correct occlusal abnormalities. Oral Surg Oral Med Oral Pathol. 1959;12(5):515-529.
- [8]. Anholm JM, Crites DA, Hoff R, et al. Corticotomy-facilitated orthodontics. J Calif Dent Assoc. 1986;14(12):7-11.
- [9]. Suya H. Corticotomy in orthodontics. In: Hösl E, Baldauf A,eds. Mechanical and Biological Basis in Orthodontics Therapy. Heidelberg, Germany: Hütlig Buch; 1991:107-226.
- [10]. Hajji SS. The influence of accelerated osteogenic responses on mandibular de-crowding [thesis]. St. Louis, MO; St Louis University:2000.
- [11]. Frost HM. The regional acceleratory phenomenon: a review.Henry Ford Hosp Med J. 1983;31(1):3-9.
- [12]. Germec D, Giray B, Kocadereli I, et al. Lower incisor retraction with a modified corticotomy. Angle Orthod. 2006;76(5):882-890.
- [13]. Hegedüs Z. The rebuilding of the alveolar process by bone transplantation. Dental Cosmos. 1923;65:736.
- [14]. Misch CE, Dietsch F. Bone-grafting materials in implant dentistry. Implant Dent. 1993;2(3):158-167.