

Evaluation of Obstructive Uropathy with Computed Tomography Urography and Magnetic Resonance Urography - A Clinicoradiological study

Dr.Meenakumari Ayekpam, Dr.Tseizo Keretsu, Dr.AK Kaku Singh

I. Introduction:

Obstructive uropathy refers to the presence of structural or functional changes in the urinary tract due to obstruction to the normal flow of urine. It is due to functional or anatomic lesions that can be located anywhere in the urinary tract, from the renal tubules to the urethral meatus.¹ It has a bimodal distribution. It is common in childhood mainly due to congenital anomalies of the urinary tract. It declines with age until late adulthood (60 to 65 years) where the incidence rises, predominantly in men, due to prostatic hyperplasia or cancer.²

Technologic advances in both computed tomography (CT) and magnetic resonance (MR) imaging have resulted in the ability to image the urinary tract in ways that surpass the prior mainstay of urinary tract imaging, the intravenous urography.

With the introduction of multidetector technology, CT urography, to date, has emerged as the initial heir apparent to intravenous urography; many years of experience have now clearly demonstrated that CT is the test of choice for many urologic problems, including urolithiasis, renal masses, urinary tract infection, trauma and obstructive uropathy.³

MR urography (MRU) is also used to evaluate the urinary tract and has the advantage of not using ionizing radiation and the potential to provide more functional information than CT.⁴ MRU as a technique for assessment of the urinary tract was first described by Hennig J et al⁵ in 1987.

The most common MR urographic techniques for displaying the urinary tract can be divided into two categories: static-fluid MR urography and excretory MR urography. Static-fluid MR urography makes use of heavily T2-weighted sequences to image the urinary tract as a static collection of fluid, and can be repeated sequentially (cine MR urography) to better demonstrate the ureters in their entirety and to confirm the presence of fixed stenoses, and is most successful in patients with dilated or obstructed collecting systems. Excretory MR urography is performed during the excretory phase of enhancement after the intravenous administration of gadolinium-based contrast material.⁶

This study evaluates the cause and level of urinary obstruction in patients with obstructive uropathy using CT Urography and correlates it with the findings of MR Urography.

Aims and Objectives:

The principle objective of the study was to investigate patients with clinical suspicion of obstructive uropathy and in patients where the cause of hydronephrosis remained undetected or inconclusive from Intravenous Pyelogram (IVP) or Ultrasonography in the following ways:

1. To determine the cause and site of obstruction with Computed Tomography Urography and Magnetic Resonance Urography.
2. To correlate Computed Tomography Urography findings with that of Magnetic Resonance Urography.

II. Materials and Methods:

The Cross-sectional study was carried out in the Department of Radiodiagnosis, Regional Institute of Medical Sciences, Imphal in collaboration with the Department of Urology, RIMS, Imphal. The study commenced from October 2013 to September 2015, for a period of two years. Study Population consisted of all patients with obstructive uropathy attending the Department of Urology, RIMS, Imphal during the study period who fulfill the inclusion criteria as below were included in the study.

Inclusion Criteria: All patients with clinical diagnosis of obstructive uropathy and patients where the cause of hydronephrosis remained undetected or inconclusive from Intravenous Pyelogram (IVP) or Ultrasonography were included in the study.

Exclusion Criteria: Patients with metallic implants in their bodies, prosthetic heart valves or pace-maker, patients with suspected metallic foreign body in any organ of the body. Patients with known allergy or hypersensitivity to an iodine-containing contrast agent or with severely impaired renal function (S.Creatinine > 2 mg/dl), pregnant women and patients with hyperthyroidism were excluded.

The sample size was kept at 60. Study variables included were age, sex, socio economic status, reason of failure of IVP, CT and MR findings.

The study was performed by using PHILIPS BRILLIANCE 64 SLICE CT and SIEMENS 1T Harmony Model-SIEMENS 2004 A.1 TESLA MRI.

The following CT protocol was used, first a Scout film was taken followed by an initial unenhanced scan extending from upper pole of kidney to the base of bladder. A non-ionic contrast agent (100–150mL of 300 mg I/mL at 2–4 mL/s) was administered by using Mallinckrodt Auto Injector through the 18 G IV cannula inserted in the antecubital vein and the 3 phases- corticomedullary, nephrographic, and pyelographic phases was taken.

The following MR sequences were used for MR Urography : HASTE (half-Fourier acquisition single-shot turbo spin-echo) sequences, T1- weighted fat-suppressed sequence, T1- weighted FL2D sequences, T2-weighted TRUFI sequence, T2- weighted TSE sequences.

For Statistical analysis, Kappa statistics was used for agreement. The study commenced only after the approval of the Institutional Ethical Committee (IEC), RIMS, Imphal. Informed consent was taken from all the participants and confidentiality was maintained.

III. Results and Observation:

A total of 60 patients suspected of obstructive etiology on the basis of clinical examination and laboratory investigations or where the cause of hydronephrosis remained undetected or inconclusive from Intravenous Pyelogram (IVP) or Ultrasonography were examined by CT Urography and MR Urography for the period starting from October 2013 to September 2015. The results have been summarized and presented in tabular forms and charts under different headings:

1. Age distribution:

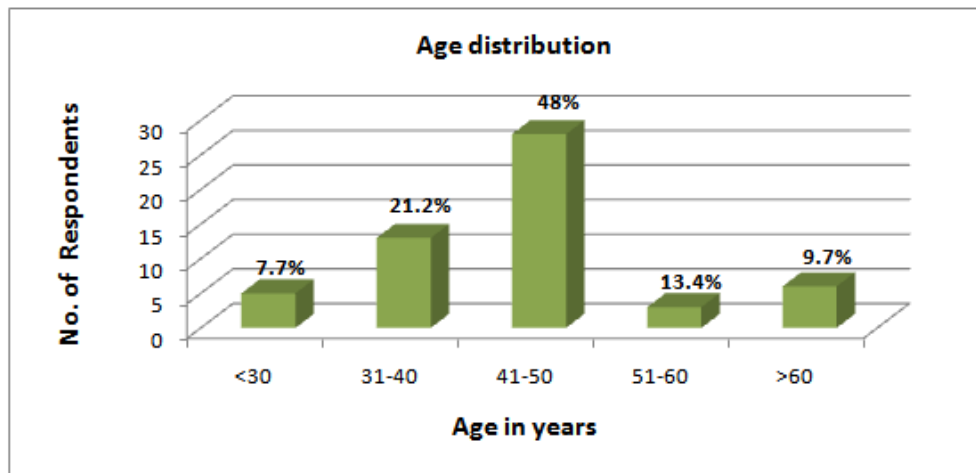


Fig 1: Bar diagram showing age distribution of the respondents.

Majority of the respondents were from the age group 41-50 years of age which accounted for 48.0% of cases. Mean age was 46.2 years with a standard deviation of 2.3 years.

2. Sex distribution

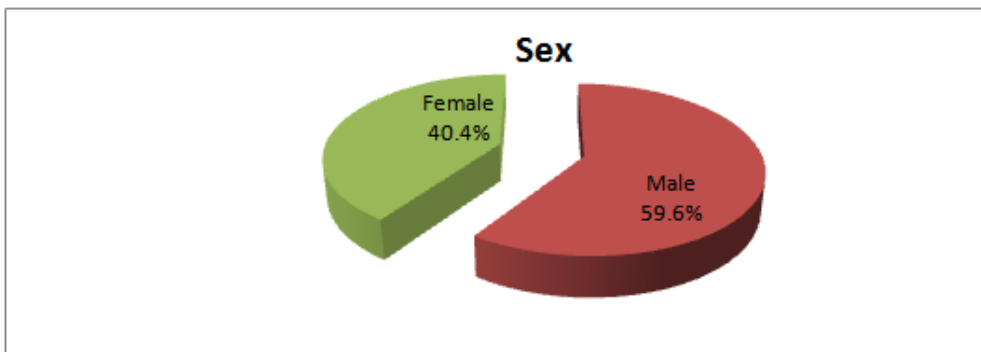


Fig 2: Pie chart showing distribution of the respondents by sex.

More than half of the respondents were male (59.6%) as shown in figure 2.

3. Distribution of the respondents by cause/reason of failure of IVP.

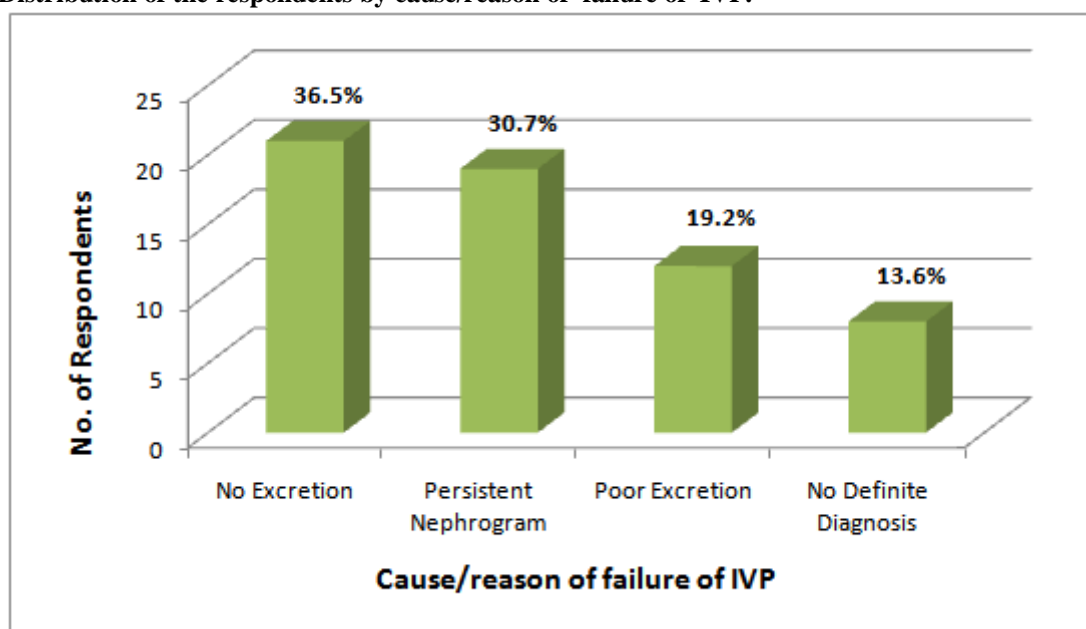


Fig 3: Bar diagram showing distribution of the respondents by cause/reason of failure of IVP.

Many had no excretion (36.5%), persistent nephrogram (30.7%) for failure of IVP and no definite diagnosis was seen in 13.6% of cases as shown in figure 3.

4. Distribution of the respondents by cause and site of obstruction with relation between CT and MR urography findings.

Obstruction	No. of renal units (MR)	%	No. of renal units (CT)	%	Kappa statistics
Yes	49	41.5	45	38.2	Value =0.70 (0.237-0.378)
Stone	26	22.0	32	27.1	Value =0.46 (0.224-0.435)
Renal	6	5.1	8	6.8	
Upper ureter	5	4.2	6	5.1	
Mid ureter	14	11.9	15	12.7	
Lower ureter	1	0.8	3	2.5	
Stricture	11	9.3	6	5.1	Value =0.35 (0.473-0.156)
Upper Ureter	5	4.2	3	2.5	
Mid Ureter	1	0.8	1	0.8	
Lower Ureter	5	4.2	2	1.7	
Tumour	9	7.6	4	3.4	Value =0.54 (0.034-0.139)
Ureter	1	0.8	0	0.0	
Bladder	4	3.4	2	1.7	
Prostate	4	3.4	2	1.7	
Extraordinary	3	2.5	3	2.5	Value=1.0 (0.427-0.559)
Retroperitoneal fibrosis	2	1.7	2	1.7	
Lymphocele	1	0.8	1	0.8	
No Obstruction	69	58.5	73	61.8	
Total	118	100.0	118	100.0	

In MR urography only 26 cases of urinary stone could be identified. But in case of stricture and tumour, most cases were identified in MR urography than CT urography. In case of extra urinary obstructions both MR urography and CT urography could identify the same number of cases. CT urography identified 2 solitary kidneys among 60 patients giving rise to 118 renal units. Among these 118 units 32 of them (38.1%) had obstruction; calculus in 32 renal units (27.1%) and acalculus in 13 (11.0%). Among acalculus obstruction, 6 of them were stricture, 4 of them were tumour and 3 of them were extraordinary as shown in the above table.

Overall there was substantial agreement (K=0.70) between CT urography and MR urography. There was good agreement between stricture and tumour identification between them and excellent agreement in extra urinary obstruction. All this finding was found to be significant (CI not crossing 1 value).

IV. Discussion:

The study was carried out in the department of Radiodiagnosis, Regional Institute of Medical Sciences, Imphal in collaboration with the Department of Urology, RIMS, Imphal which included 60 patients with clinical suspicion of obstructive uropathy and patients where the cause of hydronephrosis remains undetected or inconclusive from Intravenous Pyelogram (IVP) or Ultrasonography. Among the 60 suspected obstructive uropathy patients, nearly half of the respondents were from the age group of 41-50 years and mean age was 46.2 years. Mean age of urinary obstruction was similar with study by Bozgeyik Z et al⁷ where the mean was 45.5 years. Male patients were more common than the female patients. Most of the patients were from middle socioeconomic status.

In this study the main cause of failure of IVP was no excretion in more than one third of the cases and so CT and MR urography was performed. Other causes were persistent nephrogram, poor excretion and no definite diagnosis. This finding was consistent with the study by Abou El-Ghar ME et al⁸ where the commonest cause was no excretion in 26% of cases followed by persistent nephrogram, no excretion and no definite diagnosis.

In CT urography of the 60 patients, only 118 renal units could be identified (2 patients had solitary kidney). Obstruction was identified in 45 cases (38.2%) by CT urography : 32 cases (27.1%) of urinary stone could be identified; 8 cases of renal, 6 cases of upper ureter, 15 cases of middle ureter and 3 cases of lower ureter stone. Stricture could be identified in 6 cases (5.1%), tumour in 4 cases (3.4%) and extraurinary obstruction in 3 cases (2.5%). In the study conducted by Moawad MA et al⁹ fourteen (46.6%) cases was caused by urinary tract stones, four (13.3%) with urinary bladder masses involving ureteric orifices, three (10%) with pelviureteric junction obstruction (PUJ) obstruction, three (10%) with compression of ureters, three (10%) with ureteric injuries, two (6.6%) with bladder neck obstruction, and one (3.3%) case with ureteric stricture could be identified.

In case of MR urography only 26 cases of urinary stone could be identified. Same finding was observed in Regan F et al¹⁰ MRU/KUB showed ureteric calculi in 21/29 (72%) of patients with calculi seen at CT. But in case of stricture and tumour, more cases were identified in MR urography than CT urography. In case of extra urinary obstructions both MR urography and CT urography could identify the same cases. Similar finding was found in the study by Shokeir AA et al¹¹ where Ureteral strictures were identified by NCCT in 18 of the 65 cases (28%) and by MRU in 54 of 65 (83%). NCCT and MRU could identify all extraurinary causes of obstruction in the same study. In the study by Eassaa W et al¹² both NCCT and MRU could identify all extra urinary causes of obstruction.

In this study, the overall agreement between MR urography and CT urography was substantial (K=7.0) and confidence interval was narrow and not crossing 1 value. Good agreement was found in the diagnosis of stricture and tumour in between the two techniques. In case of extra urinary obstruction agreement was excellent giving K=1 and the finding was significant (CI- 0.034- 0.139).

V. Conclusion

In this study of 60 patients with obstructive uropathy, out of 118 renal units, 45 units of obstruction were identified as obstructed by CT urography. In case of MR urography 4 more cases of 49 obstructed units could be identified. In calculus obstruction CT urography could identify more cases than MR urography. But MR urography detected more cases of stricture and tumour. Overall agreement was substantial in between the two groups with good agreement seen in detection of stricture and tumour. Excellent agreement was found in between the two techniques for identifying extra urinary obstruction.

References:

- [1]. Klahr S. Obstructive nephropathy. Intern Med 2000 May;39(5):355-61.
- [2]. Morrissey JJ, Klahr S. Interstitial inflammation and fibrosis in obstructive nephropathy: the role of ACE inhibitors and nitric oxide. Nefrologia 1998 Jan;18(1):37-45.
- [3]. Silverman SG, Leyendecker JR, Amis ES. What is the current role of CT urography and MR urography in the evaluation of the urinary tract. Radiology Feb 2009;250(2):309-23.
- [4]. Khanna PC, Karnik ND, Jankharia BG, Merchant SA, Joshi AR, Kukreja KU. Magnetic resonance urography versus intravenous urography in obstructive uropathy: a prospective study of 30 cases. J Assoc Physicians India Jun 2005;53(9):527-31.
- [5]. Hennig J, Friedburg HG, Frankenschmidt A. Rapid acquisition with relaxation enhancement MR urography: a fast non tomographic imaging procedure for demonstrating the efferent urinary pathways using nuclear magnetic resonance. Der Radiologe 1987 Feb;27(1):45-7.
- [6]. Leyendecker JR, Barnes CE, Zagoria RJ. MR Urography: techniques and clinical applications. Radiographics Jan 2008;28(1):23-5.
- [7]. Bozgeyik Z, Kocakoc E, Sonmezgoz F. Diffusion-weighted MR imaging findings of kidneys in patients with early phase of obstruction. Eur J Radiol 2009 Mar;70(1):138-41.
- [8]. Abou El-Ghar ME, Shokier AA, Refaie HF, El-Diasty TA. MRI in patients with chronic obstructive uropathy and compromised renal function: a sole method for morphological and functional assessment. Br J Radiol 2008 Aug;81(968): 624-9.
- [9]. Moawad MA, El-Zawawy MS. The role of multidetector computed tomography urography in the evaluation of obstructive uropathy. Menoufia Med J 2015 Aug;28(2):554-8.

- [10]. Regan F, Kuszyk B, Bohlman E , Jackman S. Acute ureteric calculus obstruction: unenhanced spiral CT versus HASTE MR urography and abdominal radiograph. *Brit J Radiol* 2005 Jun;78(930):506-11.
- [11]. Shokeir AA, El-Diasty T, Eassa W, Mosbah A, El-Ghar MA, Mansour O, et al. Diagnosis of ureteral obstruction in patients with compromised renal function: the role of non invasive imaging modalities. *J Urol* 2004 Jun;171(6):2303-6.
- [12]. Eassaa W, Shokier AA, El-Diasty T, Mosbah A, Mohsen T, Mansour O, et al. Diagnosis of noncalcareous hydronephrosis: role of magnetic resonance urography and non contrast computed tomography. *J Urol* 2004 Feb;63(2):225-9.