

Prosthodontic Rehabilitation with Overdenture Using Modified Impression Technique: A Case Report

Dr. Vishakha Bhandare

Abstract: *Tooth loss may be associated with trauma, caries, periodontal disease, congenital defects, and iatrogenic treatment. It has a negative impact on physical and mental attitude of the patient. It also affects masticatory functions, aesthetics, and self-image of the patient^[10]. Prosthodontic rehabilitation involves restoration of all of them. Over denture in the era of implant dentistry allows the preservation of teeth that prevents residual bone resorption, improves retention and stability and provides proprioception, which enhances the masticatory efficiency.*

Natural teeth opposing an edentulous arch causes increased resorption of the opposing arch, supra eruption of natural teeth and other detrimental changes in the tissue that ultimately jeopardizes the success of prosthetic rehabilitation.

This case report, intends to describe where few remaining natural maxillary teeth opposes a distal extension partially edentulous lower arch. The treatment involved preservation of upper teeth to receive a tooth supported over denture using ball attachments, that prevented the chances of future development of combination syndrome and lower teeth were modified to receive cast partial denture. The final restoration was stable, well retained and esthetically pleasing, serving as a conservative approach.

Keywords: *Overdenture, proprioception, retention.*

I. Introduction:

In spite of rapid development of implant dentistry, preservation of teeth that are present is more important as De Van stated that "Perpetual preservation of what remains is more important than the meticulous replacement of what is missing". Tooth supported over dentures are a perfect example for this. It is a feasible alternative for complete extraction of teeth and replacement with complete dentures or implant supported over denture. From that concept only, preservation of roots has gained importance. Morrow et al^[7] and Lord and Teel^[6] in 1969 published an article related to over denture treatment.

Over denture is a removable partial denture or complete denture that covers and rests on one or more remaining natural teeth, the roots of natural teeth, and or dental implants. Over denture using some metal coverage over tooth is beneficial option as it protects the underlying tooth, provides additional retention, increases the efficiency of tooth supported over-denture and gives the patient a sense of excellent satisfaction by increasing retention. The main problem associated with over denture is periodontal and endodontic failure of retained abutment tooth because of improper coverage of tooth with coping resulting in open margin that increases chances of caries, poor oral hygiene maintenance that leads to periodontal problems. As prosthesis and abutment are closely related to each other that also lead to gingivitis around the retained tooth root, food lodgment and caries but all these can be manageable^[5], with excellent home care and professional assistance^[2]. Using preserved teeth as an over denture abutments is an efficient prosthetic treatment^[3] and for it to be successful requires proper diagnosis and planning so that preserved root will have sufficient bone height and periodontal support.

In this clinical report, we have planned upper over denture using ball attachments and lower cast partial dentures, so the future detrimental changes i.e. combination syndrome, caused by lower anterior teeth can be prevented with simple but yet effective treatment approach. In this we are using a modified impression technique for fabricating ball attachments so the parallelism can be maintained between them.

II. Case Report:

A 53 year old female patient reported to the Department of Prosthodontics, Govt. Dental College and Hospital, Aurangabad, with the complaint of inability to chew and unpleasing aesthetic. In upper arch 13,21,23,27 were present, and bilateral distal extension with 31, 32, 33,34,35,41,42,43,44 were present lower arch. Preoperative intraoral view is shown in fig no.1.

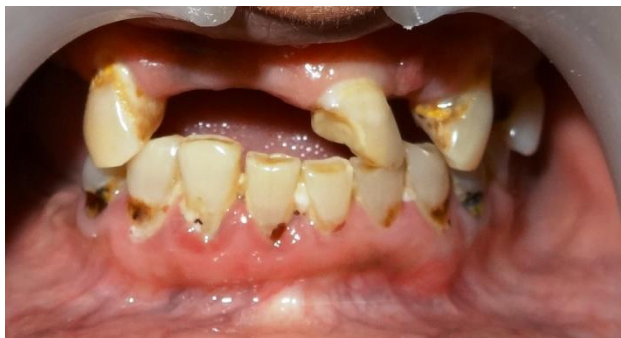

Fig no.1: preoperative intraoral view

After examination of diagnostic casts and OPG, the treatment plan was to preserve 13,21,23,27 teeth and to give tooth supported over denture using ball attachments and lower cast partial denture.

After making diagnostic impression, tentative jaw relation was recorded to check the inter arch space. After observing the space, we planned to give ball attachments on 13, 23 and short copings on 21, 27 as the needed retention will be obtained by doing this. Shallow vestibule and palate, short maxillary arch and insufficient inter arch space lead us with this treatment approach for upper arch. So, root canal treatment was performed on 13,21,23,27, and teeth were reduced to cervical level ^[1]. Post space were prepared and using pattern resin, posts patterns were made (Fig no.2).

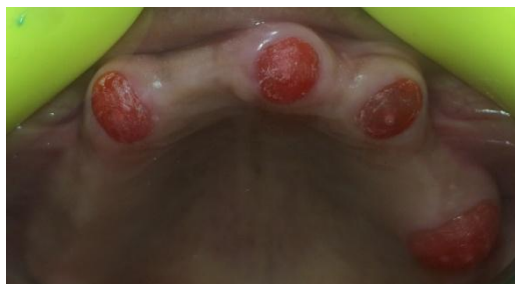

Fig no.2- post patterns in place

By using traditional impression techniques, parallelism between ball attachments cannot be verified so we used modified impression technique described by Cristian Schuch ^[4]. According to this technique, the posts with horizontal acrylic extension were placed in respective post space (Fig no.3), then vinyl polysiloxane (Dentsply) was placed around the posts (Fig no.4), followed by pick up impression with irreversible hydrocolloid (Fig no.5).Before pouring the impression with dental stone ,vinyl polysiloxane was applied over the post portion of patterns (Fig no.6) and then cast was fabricated.

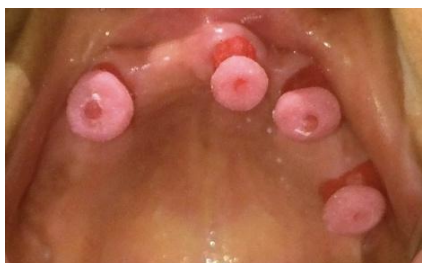

Fig no.3 - Posts in position

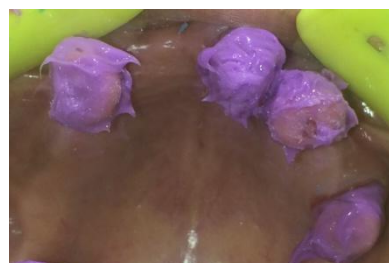

Fig no.4- Vinyl polysiloxane around posts

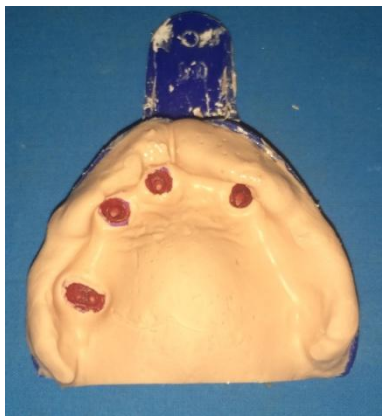

Fig no.5- Pick up impression in alginate

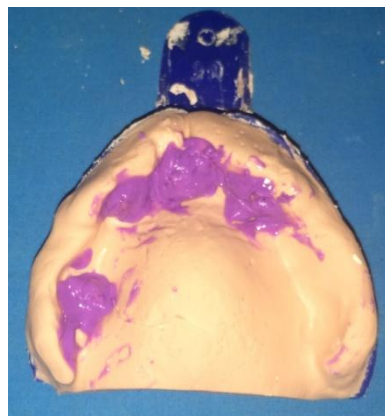


Fig no.6-Vinyl polysiloxane around them

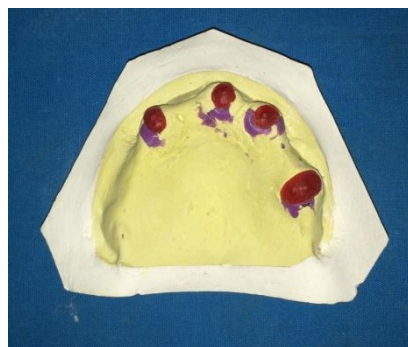


Fig no.7 - Patterns on cast

So the fabricated cast will have four post patterns positioned in post space made of light body of Vinyl polysiloxane material (Fig no.7). As the ball attachments were castable plastic patterns and therefore had to be positioned parallel to the post and to each other. The posts were placed on the cast and plastic balls were attached to it and parallelism was checked using surveyor (Fig no.8). Then casting was carried out and then cemented intra orally (Fig no.9).



Fig no.8- Surveying of plastic ball attachments on surveyor.

Mouth preparation was carried out for lower bilateral distal extension in that because of unfavorable crown contours of 34,35,44, metal crowns with buccal ceramic facing were given. RPI System was given over 34, 35 with indirect retainer on 34,43 and because of insufficient height of floor of mouth, lingual plate was planned. Final impression was made. Wax pattern was made and then casted and fitting was checked intra orally.

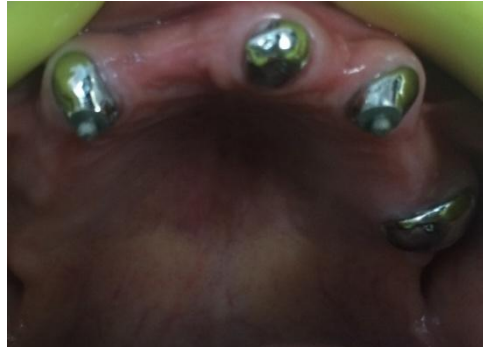

Fig no.9- copings in place

Preliminary impression followed by final impression of upper arch was made. To record the lower bilateral distal extension edentulous portion in functional form, final impression of lower arch was made using metal framework as tray. In this way dual impression was made i.e. edentulous portion in functional form and dentulous portion in anatomic form (Fig no.10). Followed by lower altered cast fabrication.

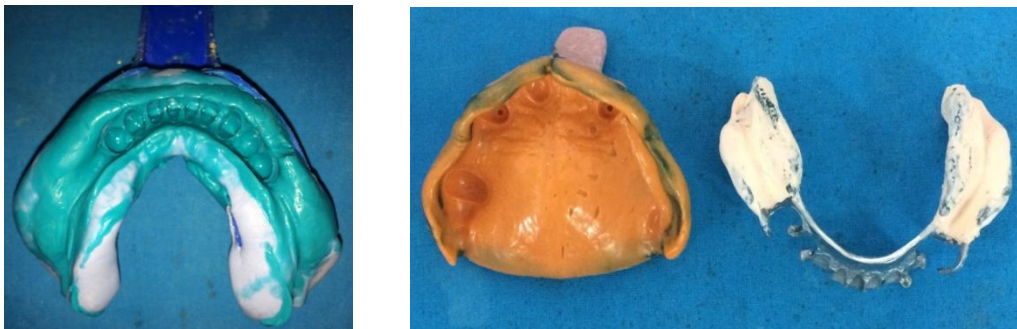


Fig no.10- Final impressions of upper and lower arch

Using face bow record (Fig no.11), upper cast was mounted and after recording vertical and centric relation (Fig no.12), lower cast was mounted.

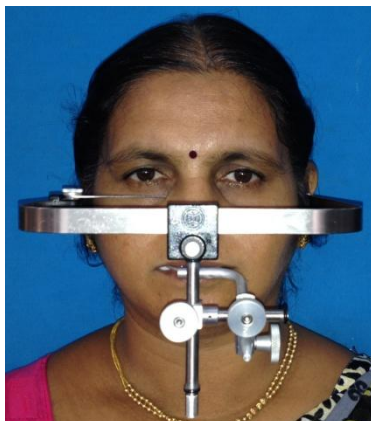

Fig no.11- Facebow record

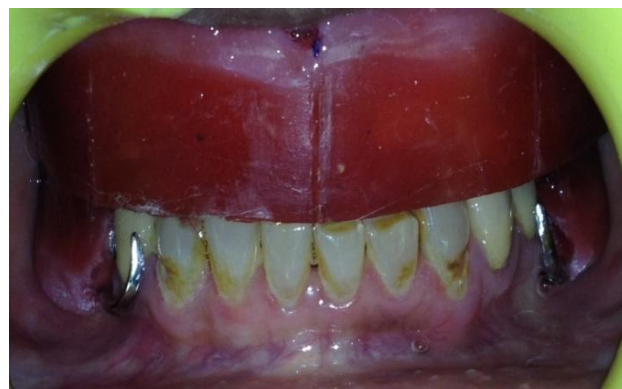

Fig no.12- Centric relation

Try in was carried out (Fig no.13). After processing of final denture, metal housings of ball attachments were picked up in denture using cold cure acrylic resin and denture was finished (Fig no.14). The final prosthesis is shown in the (Fig No.15). Recall check-up was done, and patient was satisfied with the prosthesis.

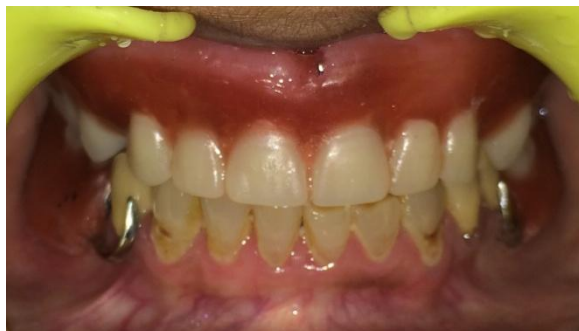

Fig no.13- Try in

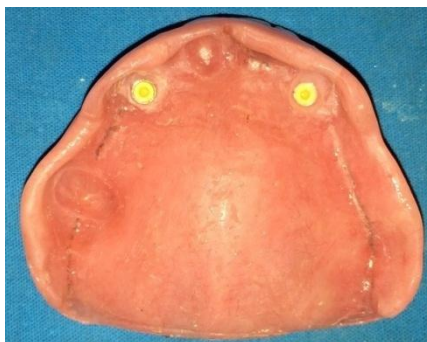

Fig no.13 Finished denture with female part incorporated



Fig no.14 Patient with Final prosthesis

III. Discussion

In this case report, we have planned for tooth supported over denture instead of complete denture or implant supported over denture, as stated by DeVan, it is always better to preserve teeth whenever possible. Preservation of teeth allows reduction in bone loss and maintains proprioception that gives patient a sense of chewing and improves the acceptability of prosthesis, which ultimately helps the patient to maintain hygiene of oral tissues that in return increases the life of prosthesis and maintains physiological dimension of patient.

Instead of using bare abutment root, it can be covered with metallic coping may be short or long, attachments and telescopic crown^[8, 9]. All these helps to protect tooth, provides additional retention so the patient's satisfaction will be more, improving the acceptability of the prosthesis. Selection of the attachments is important according to the requirement of the case. Sufficient space should be there for an attachment. Selection of attachment depends on vertical space available, crown/root ratio, type of coping, number of teeth support, type of opposing dentition^[8, 9]. It also depends on angulations of the root to the occlusal plane, amount and quality of bone support, location of abutments, chewing pattern and the musculature of the patient and patient desire. Among these various attachments available, the ball attachment system is considered as an appropriate, resilient mechanical attachment^[11]

Ball attachment have ball as male component and stainless steel caps with elastic retentive rings as female component. They are, usually available in normal and microforms. Here normal size was used. Best option for treatment for the extraction of teeth and placement of implants is over-denture with attachments.

Motivation of patient for this treatment is primarily important as he has to maintain good oral hygiene with professional assistance.

IV. Conclusion

Despite recent developments in dental implantology, the conservative approach to root preservation is still valid. In this case report, the use of short-coping and ball attachments to improve the retention and stability of over dentures is described. Modified impression technique was used to enhance the prognosis of abutment as well as of prosthesis. A regular maintenance program is recommended to prematurely prevent any problem.

References:

- [1]. Attachment Retained Removable Partial Denture: A Case Report. Sumit Makkar et al; IJCDS; may 2011; 2(2)
- [2]. Bassi F. Over denture therapy and worst-case scenarios: Alternative management strategies. *Int J Prosthodont* 2007; 20:350-3
- [3]. Crum RJ, Rooney GE. Alveolar bone loss in over dentures: a 5-year study. *J Prosthet Dent* 1978; 40:610-3.
- [4]. Cristian Schuch. An alternative method for the fabrication of a root supported over denture: A clinical report. *J Prosthet Dent* 2013; 109(1):1-4
- [5]. Jorgensen E. Effect of controlled oral hygiene in over denture wearers: a 3-year study. *Int J Prosthodont* 1991; 4:226-31.
- [6]. Lord JL, Teel S. The over denture. *Dent Clin North Am* 1969; 13:871-81.
- [7]. Morrow RM, Feldmann EE, Rudd KD, Trovillion HM. Tooth-supported complete dentures: an approach to preventive prosthodontics. *J Prosthet Dent* 1969; 21:513-22.
- [8]. Over dentures in general dental practice. Part 5—the use of copings and attachments. Basker RM, Harrison A, Ralph JP. *Br Dent J* 1983; 155:9-13.
- [9]. Over dentures--theory and technique. Zamikoff II. *J Am Dent Assoc* 1973; 86:853-7
- [10]. Oosterhaven s. p., Westert g. p., Schaub r. m.: Perception and significance of dental appearance: the case of missing teeth. *Community Dent. Oral Epidemiol.* 17: 123–126, 1989.
- [11]. Tokuhisa M, Matsushita Y, Koyan K. In vitro study of a mandibular implant over denture retained with ball, magnet, or bar attachment: comparison of load transfer and denture stability. *Int J Prosthodont* 2003; 16:128-34.