

## Concepts of Healing in Periodontal Therapy - Part I

Dr. Shubham Kumar<sup>1</sup>, Dr. Krishna Kumar Gupta<sup>2</sup>, Dr. Devleena Bhowmick<sup>3</sup>, Dr. Abhishek Singh<sup>4</sup>

<sup>1</sup>(PG Student, Department of Periodontology & Implantology, Sardar Patel Post Graduate Institute of Dental & Medical Sciences, Lucknow, UP, India)

<sup>2</sup>(Professor & Head, Department of Periodontology & Implantology, Vyas Dental College & Hospital, Jodhpur, Rajasthan, India)

<sup>3</sup>(PG Student, Department of Oral Medicine & Radiology, Sardar Patel Post Graduate Institute of Dental & Medical Sciences, Lucknow, UP, India)

<sup>4</sup>(PG Student, Department of Oral & Maxillofacial Surgery, Sardar Patel Post Graduate Institute of Dental & Medical Sciences, Lucknow, UP, India)

**Abstract:** Healing of wound remained a mystery for centuries with varying concepts in different frame of space and time. With the advent of latest techniques in molecular biology, this miracle of God has begun to unfold its mystery. Though humans claim to have known much of its model, the great variability of its nature still remains to be explored. The present review focuses on the healing of wounds with an emphasis on periodontal wound healing. For the ease of understanding, this review had been divided into three parts. This part of the article focuses on the basics of wound healing process.

**Keywords:** Wound Healing, Periodontal Wound Healing, Inflammation, Collagen, Granulation

### I. Introduction

The wound is defined as, “A forced separation or circumscribed damage of skin or mucosa”.<sup>[1]</sup> Wounds and their management are fundamental to the art and practice of surgery. The ancient Egyptians were the first civilization to have trained physicians to treat physical ailments and their medical papyri, such as the Smith papyrus (circa 1600 BC) and the Ebers papyrus (circa 1534 BC), provided detailed information on wound management with the application of various potions and grease to assist healing.

Indian physician **Sushruta** in his book “Sushruta Samhita” described about wounds (Vrana – Dusta, Suddha & Rudha) and described about basics of plastic surgery involving grafts and flaps for management of war inflicted wounds.<sup>[2]</sup> **Hippocrates** (Greek Physician and surgeon, 460-377 BC), known as the father of medicine, used vinegar to irrigate open wounds and wrapped dressings around wounds to prevent further injury and his teachings remained unchallenged for years. The concept of wound healing remained a mystery, as highlighted by the famous saying by **Ambrose Pare** (French military surgeon, 1510-1590), “**I dressed the wound. God healed it**”. However in the last 50 years, there has been a revolution in wound management. Since the discovery of the first growth factor in 1962; Epidermal Growth Factor, the science of wound repair and regeneration has advanced enormously from macroscopic level to nanoscience level.

Surgeons often encounter with trauma cases where wound is the primary pathology while access to the underlying pathology is made by creating a surgical wound during elective surgery. The goal of surgery in both the situations is to minimise the adverse effects of the wound, remove or repair damaged structures and harness the process of wound healing to restore the function.

The classification of surgical wounds was initially developed by the **American College of Surgeons** & later adapted by **Centers for Disease Control and Prevention (CDC)** which classifies surgical wounds into:

**Table 1: Classification of Surgical Wounds** <sup>[2,3]</sup>:

Class	Explanation	Risk of Infection	Examples
Class I: Clean	Uninfected operative wound where no inflammation is encountered and respiratory, GI, genital, and urinary tracts aren't entered	2% or Lower	Coronary Artery Bypass Grafting, Knee or Hip Replacement, Exploratory or Diagnostic Laparo-Scopy, Mastectomy, Axillary Node Dissection etc
Class II: Clean/Contaminated	Operative wound that enters the respiratory, GI, genital, or urinary tract under controlled conditions without unusual contamination when no infection or major break in technique has occurred	5% -15%	Dental Surgeries, Appendectomy, Transurethral resection of Prostate, Vaginal Hysterectomy etc
Class III: Contaminated	Open, fresh, accidental wound from surgery with a major break in sterile technique or gross spillage from GI tract; Incision in which acute, nonpurulent inflammation is	> 15%	Cholecystectomy/Appendectomy for Acute Inflammation, Bile spillage during cholecystectomy, Open cardiac massage, Bowel resection for infarcted or necrotic bowel

	encountered (including necrotic tissue without evidence of purulent drainage, such as dry gangrene)		etc
Class IV: Dirty-Infected	Old traumatic wounds with retained devitalized tissue; procedures with existing clinical infection (purulence already present in wound) or perforated viscera	> 30%	Dental Extractions with Abscess, Open Fracture with prolonged time in the field before treatment, Incision and drainage of perirectal abscess, perforated bowel repair

Wound healing is a mechanism whereby the body attempts to restore the integrity of the injured part. It is a summation of processes that follow injury and include coagulation, inflammation, matrix synthesis and deposition followed by angiogenesis, fibroplasia, epithelialization, contraction, remodelling and scar maturation. Wound healing is commonly described as taking place into three phases:<sup>[4 -6]</sup>

1. The Inflammatory Phase
2. The Proliferative Phase
3. The Remodelling Phase

Wound healing may either take place by “**Primary Intention**” or “**Secondary Intention**”. Healing by primary Intention is also known as healing by first intention. This occurs when the wound edges are closely approximated with minimal surrounding tissue trauma leading to least inflammation and best scar formation. If the wound edges are separated, such as when there has been tissue loss, healing takes place by granulation, contraction and epithelialisation with marked inflammation known as healing by second intention with poor scar formation. Some authors/texts also suggest another form of tissue healing known as “**Healing by Tertiary Intention**”.<sup>[5]</sup> This type of tissue healing takes place in contaminated or untidy wounds where the wound is initially left open and the edges are later approximated when healing conditions are favourable.

Periodontal tissues represent a unique system in the human body where epithelial, soft and mineralized connective tissues come together to form a junction, referred to as the dentogingival junction. Periodontitis is a multifactorial disease that causes destruction of the tooth supporting structures resulting in tooth loss. Maintenance of the integrity of this junction is therefore critical for the preservation of underlying bone and periodontal ligament.

Conventional periodontal therapy involves instrumentation of the inflamed periodontal hard and soft tissues. Mucogingival Surgeries are the surgical procedures performed to correct or eliminate the anatomic, developmental or traumatic deformities of the gingiva or alveolar mucosa (AAP, 1996). Consequence of all such therapeutic approach depends largely on the cellular and molecular events associated with wound healing. Therefore, a thorough understanding of events associated with wound healing is a prerequisite for formulating the treatment plan. The first part of the review confers about the basics in wound biology. In the subsequent parts we would discuss about the growth factors and periodontal wound healing.

## II. Wound Healing

As per the classic description of wound healing, initially there is temporary repair characterized by the formation of a clot in the wounded tissues. Inflammatory cells followed by fibroblasts and endothelial cells then invade the clot to form a granulation tissue, while the epithelial cells migrate to cover the denuded surfaces (or form a junction at the tooth interface). Finally, maturation of the healing tissue matrix is seen along with contraction or scarring. It is important to mention that these various phases of wound healing overlap somewhat in time.

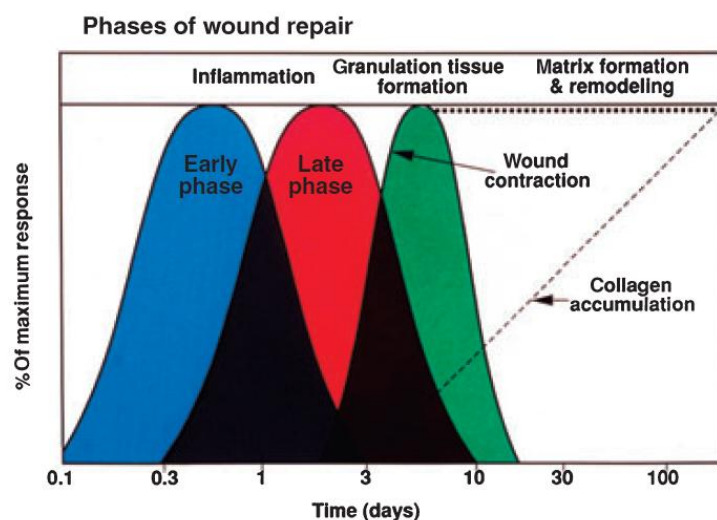


Fig 1: Phases of Epidermal Incisional Wound Healing<sup>[8]</sup>

Although the wound-healing process varies among different tissue types, there are more similarities than differences between them. In this discussion, skin is considered as a representative tissue type. There are also different types of skin wounds (Tidy & Untidy Wounds, Acute & Chronic Wounds etc) and different types of wounds involve different phases of the healing process to varying degrees, although the phases themselves remain the same. Wound healing is commonly described as taking place into three or four phases:<sup>[4-6]</sup>

1. **The Inflammatory Phase** - Haemostasis occurs and an acute inflammatory infiltrate ensues
2. **The Proliferative Phase** - Characterized by fibroplasia, granulation, contraction and epithelialisation
3. **The Remodelling Phase** - Described as scar maturation

#### 1) The Inflammatory Phase:

All significant traumas create a vascular injury and thereby initiate the molecular and cellular responses that establish haemostasis. The healing process cannot proceed until haemostasis is accomplished. Primary contributors to haemostasis include **vasoconstriction, platelet aggregation, and fibrin deposition** resulting from the coagulation cascades. The end product of the haemostatic process is clot formation. Clots are primarily composed of fibrin mesh and aggregated platelets along with embedded blood cells.<sup>[7]</sup> This process prevents further fluid and electrolyte loss from the wound site and limits contamination from the outside environment. Fibrin is the mesh material in the provisional wound matrix onto which fibroblasts and other cells migrate as the healing process proceeds. Meanwhile inflammatory cells move to the area of injury under the effect of chemokine signalling and inflammation ensues.

##### 1(a). Vasoconstriction:

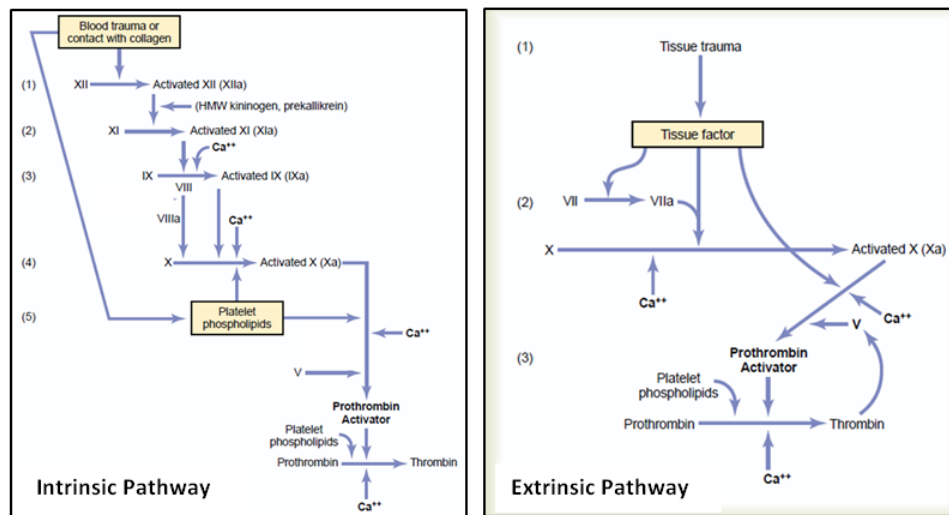
Vasoconstriction is initiated by the release of vasoactive amines, which occur when the dermis is penetrated. Epinephrine is released into the peripheral circulation, whereas stimulation of the sympathetic nervous system results in local norepinephrine release. Injured cells secrete prostaglandins, such as thromboxane, that contribute further to vasoconstriction.

##### 1(b). Platelet aggregation:

Platelet aggregation is stimulated by exposure to tissue factors released by damaged cells. Platelets adhere to the vascular sub-endothelium and to each other in a process involving fibrinogen and von Willebrand factor.<sup>[8]</sup> As platelets aggregate and adhere, they release the contents of alpha granules, dense bodies, and lysosomes within their cytoplasm.<sup>[9]</sup> Alpha granules contain a variety of immunomodulatory and proteinaceous factors that are involved in both the early and late phases of healing. Specifically, these factors include Albumin, Fibrinogen, Fibronectin<sup>[10]</sup>, IgG, and Coagulation Factors V and VIII, as well as Platelet-Derived Growth Factor (PDGF), Transforming Growth Factors  $\alpha$  and  $\beta$  (TGF- $\alpha$  and TGF- $\beta$ ), Fibroblast Growth Factor-2 (FGF-2), and Platelet-Derived Epidermal Growth Factors (EGFs), and Endothelial Cell Growth Factors.<sup>[11]</sup> Of these factors, PDGF, TGF- $\beta$ , and FGF-2 are the most important. Dense bodies contain necessary fuel-providing compounds (calcium, serotonin, ADP, and ATP) that contribute to the healing process.

**1(c). Coagulation Cascade:**

The coagulation cascades are composed of intrinsic and extrinsic components that are individually triggered. The intrinsic coagulation cascade is initiated by activation of factor XII, which occurs when blood is exposed to foreign surfaces. The more critical extrinsic coagulation cascade is initiated by exposure to a “tissue factor” that binds factor VII or factor VIIa. The actions of the intrinsic and extrinsic pathways result in the production of thrombin, which catalyzes the conversion of fibrinogen to fibrin. Thrombin itself stimulates increased vascular permeability in addition to facilitating the extravascular migration of inflammatory cells.<sup>[12]</sup> Fibrin forms the meshwork that stabilizes the platelet plug. Fig 2 depicts the intrinsic & extrinsic clotting pathway while Table 2 summarizes differences between the two.<sup>[13]</sup>



**Fig 2:** Intrinsic & Extrinsic Pathway for formation of Thrombin<sup>[13]</sup>

**Table 2:** The differences between Intrinsic and Extrinsic Clotting Pathway.<sup>[13]</sup>

Intrinsic Pathway	Extrinsic Pathway
Initiated by trauma to Tissue	Initiated by trauma to Blood Cells or Exposure to Collagen
Ca++ is not required in 1st two steps	Ca++ is required at all the steps
Independent of amount of Tissue Factor released	Depends on the amount of Tissue Factor released
Slower to Proceed	May be Explosive
Requires 1-6 minutes	Clotting can occur in 15 seconds

**Inflammation:**

Inflammation is defined as, “A reaction to injury of the living microcirculation and related tissues”<sup>[14]</sup> and is characterized five cardinal features: **Rubor** (redness); **Tumor** (swelling); **Calor** (heat); **Dolor** (pain) & **Functio laesa** (loss of function). Typically inflammation can progress through three stages: Immediate, Acute & Chronic. Leukocytes control all the three stages of inflammation (Table 3):

One of the primary functions of inflammation is to bring inflammatory cells to the injured area mediated via various chemokines<sup>[15]</sup>. These cells then destroy bacteria and eliminate debris from dying cells and damaged matrix so that the repair processes can proceed<sup>[16]</sup>.

The directed movement of leukocytes from blood into the local tissue by transendothelial migration is central to the inflammation. Leukocyte migration into the wounded area is stimulated by collagen, elastin breakdown products, complement factors, and immunomodulatory factors including Transforming Growth Factor-β (TGF-β), Tumor Necrosis Factor-α (TNF-α), Interleukin-1 (IL-1), Platelet Derived Growth Factors (PDGF), Leukotriene B4 & Platelet Factor IV.

Transendothelial migration occurs in the following sequential phases:<sup>[17]</sup>

- Step 1 :** Rolling
- Step 2 :** An insult to local tissue
- Step 3 :** Signalling the endothelium
- Step 4 :** Increased rolling
- Step 5 :** Signal for rolling arrest
- Step 6 :** Arrested rolling/ Strong adhesion
- Step 7 :** Zipper Phase

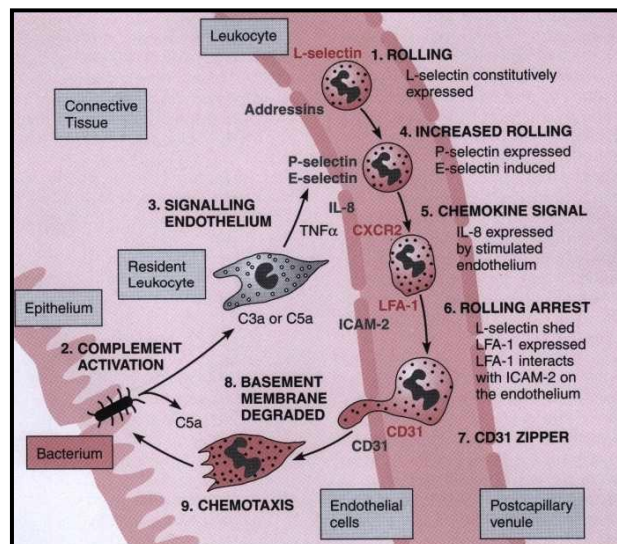
**Table 3:** Cells of the Immune System <sup>[17]</sup>:

Leukocytes	Normal Blood Levels (per mm <sup>3</sup> )	Notable properties (Cell Diameter In Blood)	Important Functions In Inflammation
<b>MYELOID CELLS</b>			
Neutrophil	4000 to 8000	Terminally differentiated I blood, granular cytoplasm(9-10 μm)	Phagocytic killing of microorganism
Monocyte	200 to 800	Immature in blood(9-10 μm)	Can differentiate to macrophages with diameters >20 μm Functions in phagocytosis and antigen processing and presentation
Peripheral dendritic cell	N/A	Immature in blood(9-10 μm)	Resident in parabasilar epithelium functions in processing and presentation of antigen
Eosinophil	50 TO 300	Terminally differentiated I blood, granular cytoplasm(9-10 μm)	Antiparasitic and antihelminthic activity, mediated by IgE
Basophil	0 TO 100	Terminally differentiated I blood, granular cytoplasm(9-10 μm)	Receptor profile suggests that cells may respond to bacterial and parasitic functions.
Mast cell	N/A	N/A	Resident of perivascular connective tissue Anaphylactic effects in response to C3a and C5a Antigen recognized by IgE
<b>LYMPHOID CELLS</b>			
CD4+ cells	400-1600	(8-10 μm)	Scanning antigen presented by professional antigen-presenting cells; in inflammation, this may result in clonal expansion of B cells or T cells.
CD8+ cells	200-800	(8-10 μm)	Scanning antigen presented by all cells; in inflammation, this may result in clonal expansion and killing of the cell presenting antigen.
B cells	200-800	(8-10 μm)	Binding soluble antigen, antigen processing and presentation; in inflammation, this may result in clonal expansion and antibody secretion.
Natural killer- (NK) cell	100-500	(8-15 μm)	Scanning cell antigens, targets cell killing if KAR scans antigen, no killing if KIR scans antigen.

Leukocytes use the lectin (a nonenzymatic carbohydrate-binding protein), designated L-selectin, to interact with carbohydrate molecules known as vascular addressins (e.g., sialomucin CD34) on the luminal surface of endothelial cells (Step 1, Fig 3), a process whereby the leukocyte essentially pauses to inspect the endothelium.

A local insult (Step 2, Fig 3) triggers the release of a variety of inflammatory signals [such as interleukin-1β (IL-1β), tumor necrosis factor-α (TNF-α)] from cells in the tissue, especially from resident leukocytes such as mast cells. Mast cells are crucial in initiating neutrophil recruitment against bacteria and responding to anaphylatoxins such as C3a and C5a (Step 3, Fig 3).

IL-1β, TNF-α, C5a, and lipopolysaccharides can stimulate endothelial cells to express P-selectin and E-selectin on their luminal surfaces. Either of these selectins can bind carbohydrate molecules found on the leukocyte, resulting in an increase in the time the leukocyte remains associated with the endothelium. This appears microscopically as an increase in number of leukocytes attached to the luminal surface of the endothelium (Step 4, Fig 3).



**Fig 3:** Inflammation is a result of interaction between complement, resident leukocytes, endothelium and recruited inflammatory leukocytes <sup>[17]</sup>

The stimulated endothelium also releases chemokines. Chemokines are small peptide cytokines, first recognized for their chemoattractant activities, which play a fundamental role as selective signals for leukocytes to exit the blood (Step 5, Fig 3). Because leukocytes differ with respect to their chemokine receptors, the

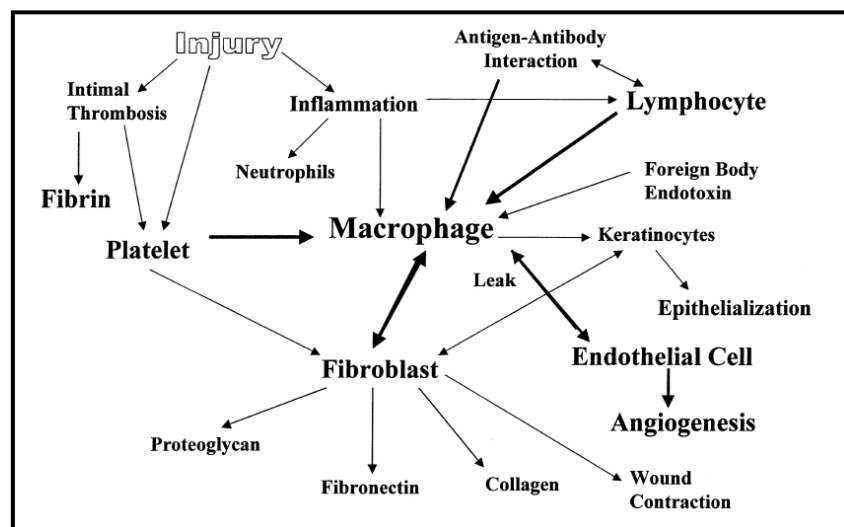
chemokines dictate which leukocytes (e.g., neutrophils, macrophages, lymphocytes, eosinophils, basophils) dominate the leukocyte infiltrate. Different stimuli can lead to expression of different chemokines.

Chemokines function as a signal for rolling arrest. As illustrated in Fig-3, the interaction of a chemokine, interleukin-8 (IL-8), with the leukocyte receptor CXCR2 causes the leukocyte to shed L-selectin and upregulate the integrin, leukocyte function-associated antigen-1 (LFA-1). Integrins are transmembrane adhesins, some of which have been adapted for use by the immune system. LFA-1 binds intercellular adhesion molecule-2 (ICAM-2), which is expressed constitutively by endothelium. This results in rolling arrest because the phagocyte becomes firmly associated with the endothelium (Step 6, Fig 3). Prolonged or severe disturbances of the endothelium can upregulate ICAM-1, which is a more efficient ligand for LFA-1.

CD31 (Platelet-Endothelial Cell Adhesion Molecule-1) is a 130-kd transmembrane glycoprotein present at the intercellular borders of endothelial cells facing into lumen and on all leukocytes. CD31 is a homophilic adhesion molecule and the guides leukocytes to the boundaries between endothelial cells (Step 7, Fig 3). Once the leukocyte locates the interendothelial junction, the endothelium “unzips” its CD31 and the leukocyte uses its own CD31 to rapidly “zip” between the endothelial cells. This zipper effect has been proposed as a mechanism of minimizing the leakage of fluid. As. Leukocytes accumulate briefly between the basement membrane and the endothelial cell. This pause may reflect a period of secretion of proteases to degrade the basement membrane which enables the leukocyte to enter the connective tissues.

After the transepithelial migration, the leukocytes are activated by chemostatic factors and initiate cellular wound debridement by phagocytosing bacteria and foreign material. In addition to phagocytosing debris, macrophages also contribute to extracellular breakdown by releasing matrix metalloproteinases (MMPs) such as collagenase and elastase into the wounded area [18] and release cytokines that mediate later aspects of the healing process.

The presence or absence of polymorphonuclearleukocytes will only alter the rate of wound infection [19]. The added function of cytokine production differentiates the activities of the two cell types and makes macrophages more essential. The role of the macrophage is complex in that this multipurpose cell is involved in many aspects of healing through the cytokines and immunomodulatory factors it produces (Fig. 4).



**Fig 4:** Macrophages are crucial to the various phases of acute wound healing and serve as central stimulator for different cell types involved in wound healing [20]

Macrophage-produced cytokines are involved in angiogenesis, fibroblast migration and proliferation, collagen production [21] and possibly wound contraction. Transforming Growth Factor-  $\beta$  (TGF- $\beta$ ), Interleukin -1 (IL-1), Insulin-like Growth Factor-1 (IGF-1), Fibroblast Growth Factor -2 (FGF-2), and Platelet Derived Growth Factor (PDGF) are several of the more critical macrophage- derived cytokines. Furthermore, macrophages also release nitric oxide, which may serve an antimicrobial function as well as other functions during the healing process [19].

Other inflammatory cell types include eosinophils and basophils and their complete role in inflammation remains to be delineated. As the healing process proceeds, inflammatory cells get trapped within clot. Neutrophils remaining within the wound become senescent and undergo apoptosis [22]. Apoptosis is characterized by the activation of endogenous calcium dependent endonucleases. Neutrophils are the first of the inflammatory cells to become apoptotic and are phagocytosed by macrophages [23]. Macrophages and

lymphocytes remain in the wound for approximately 7 days and then gradually diminish in number unless a noxious stimulant of further inflammation persists.

## 2. The Proliferative Phase:

The cellular milieu in wounds changes dramatically in the first week post acute injury. The initial fibrin–fibronectin matrix is heavily populated by inflammatory cells, whereas fibroblasts and endothelial cells will predominate as healing progresses. Cytokine continues to be a part of the process as its release contributes to **Fibroplasia, Granulation, and Epithelialization**<sup>[24]</sup>. Usually these phases often interplay in an overlapping manner. Although much is known about the signals that stimulate the predominant activities during this phase of healing, less is known about the signals that bring these activities to a controlled end. Negative feedback mechanisms that deactivate cells after they have completed their work are also essential for normal healing.

### 2(a). Fibroplasia:

The proliferative phase begins with activation of fibroblasts by the growth factors released by macrophages that populate the initial fibrin–fibrinogen matrix. Fibroblasts are ubiquitous cells found in virtually all tissues, and are defined as adherent cells that have a capacity to synthesize and remodel the collagen-rich Extracellular Matrix (ECM)<sup>[25, 26]</sup>. Fibroblasts also play a key role in pathologies associated with wound healing, including chronic, non healing wounds, keloid or hypertrophic scars and organ fibrosis<sup>[27, 28]</sup>.

Factors that stimulate fibroblast migration include PDGF<sup>[29]</sup>, TGF- $\beta$ <sup>[30]</sup>, and EGF<sup>[31]</sup>. Cellular migration requires cell membrane-bound integrins to be bound to fibronectin in the extracellular matrix<sup>[32]</sup>. A migrating cell then develops lamellopodia that extend outward until another binding site is detected in the matrix<sup>[33]</sup>. By releasing the primary binding site and pulling itself toward the second site, the cell migrates, using the new site as an anchor<sup>[34]</sup>. The ability of fibroblasts to migrate may be impeded by residual debris in the wound environment. To facilitate migration through such debris, fibroblasts secrete several proteolytic enzymes including MMP-1, gelatinase (MMP-2), and stromelysins (MMP-3)<sup>[35, 36]</sup> under the influence of TGF- $\beta$ <sup>[37, 38]</sup>.

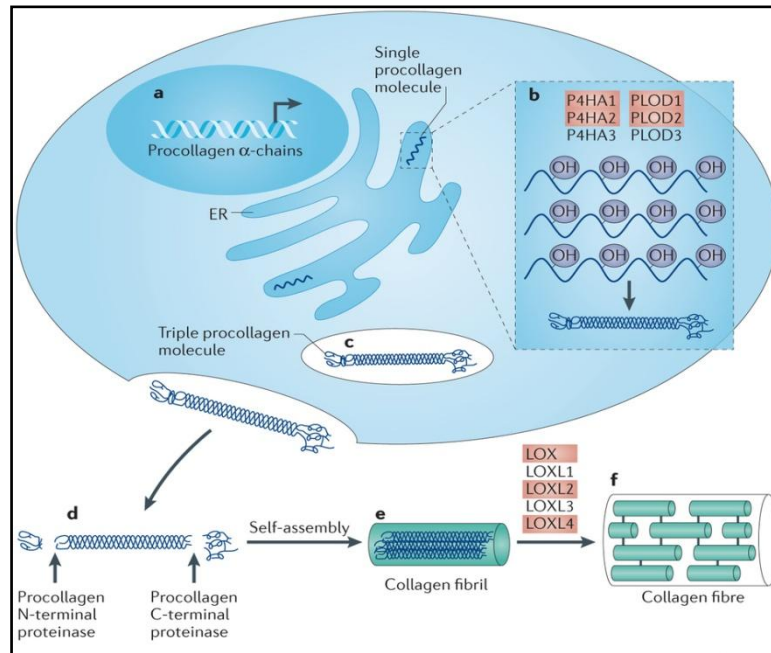
Once the fibroblasts migrate into the wound, they become active and increase protein synthesis and become the prominent cell type by 3 to 5 days in clean, noninfected wounds. After cell division and proliferation, fibroblasts begin synthesis and secretion of extracellular matrix products. The initial wound matrix is provisional and is composed of fibrin, glycosaminoglycan (GAG) & hyaluronic acid<sup>[6]</sup>. Concomitantly, collagens types I and III are deposited by fibroblasts onto the fibronectin and GAG scaffold in a disorganized array. The collagen superfamily contains at least 27 types of collagen that together constitute the most abundant proteins found in the body<sup>[39]</sup>.

Type I collagen predominates and makes up to 80% - 90% of the collagen seen in intact dermis. The remaining 10% - 20% is Type III collagen. In contrast, granulation tissue that forms soon after injury contains 30% type III collagen. Accelerated type III collagen synthesis is correlated with fibronectin secretion after injury<sup>[40]</sup>. Type II collagen is seen almost exclusively in cartilage, whereas type IV collagen is found in basement membranes. Type V collagen is found in blood vessels, whereas type VII collagen forms the anchoring fibrils of epidermal basement membrane<sup>[41]</sup>.

Collagen synthesis is stimulated by TGF- $\beta$ , PDGF & EGF<sup>[40]</sup>. Collagen synthesis is also affected by characteristics of the patient and the wound including age, tension, pressure, and stress<sup>[42]</sup>. Collagen synthesis continues at a maximal rate for 2 to 4 weeks and subsequently begins to slow. Healing aberrations are often the result of aberrations in collagen deposition. Conversely, keloid formation results from excessive collagen synthesis<sup>[43]</sup>.

Collagen undergoes many posttranslational steps intracellularly prior to its extracellular secretion in the form of triple helical procollagen (Fig – 5). A critical step involved is the hydroxylation of proline and lysine moieties that requires specific enzymes and cofactors - oxygen, vitamin C, ferrous iron, and a ketoglutarate. Deficiencies in vitamin C or suppression of enzymatic activity by corticosteroids can lead to underhydroxylated collagen that is incapable of generating strong cross-links.

Proteoglycans consist of a protein core covalently linked to one or more glycosaminoglycans and are synthesized by fibroblasts after injury. Their concentration in injured tissue gradually increases with time in a manner paralleling collagen. Proteoglycans binds to proteins and alter their orientation in a manner that influences their activity. **Dermatan Sulfate** is a proteoglycan that orients collagen molecules in a manner that facilitates fibril formation. **Hyaluronan**, another proteoglycan, contributes to skin's viscoelastic properties and acts as a potent modulator of cellular migration<sup>[44]</sup>. **Elastin**, an another component of wound matrix that provides elasticity to normal skin is not synthesized in response to injury and is the reason for increased stiffness and decreased elasticity of scar as compared with normal dermis.



**Fig 5:** Intracellular (a–c) & Extracellular (d–f) biosynthesis of collagen. **a-** synthesis of procollagen polypeptides from any of 42 distinct collagen gene transcripts, **b-** post-translation modification within the cisternae of the endoplasmic reticulum (ER) by prolyl 4-hydroxylase(P4HA) and procollagen-lysine 2-oxyglutarate 5-dioxygenase (PLOD) isoforms, **c-** The triple helical procollagen transported from the ER to the extracellular space via the Golgi, **d-** Two metalloproteinases, Procollagen N-terminal proteinase & Procollagen C-terminal proteinase, cleave the non-helical terminals, **e-** mature collagen proteins spontaneously aggregate to form a collagen fibril, **f-** Collagen cross linking, catalysed by Lysyl Oxidase (LOX) family members. <sup>[45]</sup>

Open wounds (trauma, burns or when closed wounds get infected) are characterized by synthesis of proteins and wound contraction that begin to predominate 4 to 5 days after wounding. Wound contraction is characterized by a predominance of myofibroblasts at the wound periphery. Myofibroblasts are modified fibroblasts that were initially described by Gabbiani et al (1971) <sup>[46]</sup>.

The defining characteristics of myofibroblasts include actin-rich microfilaments in the cytoplasm, a multilobulated nucleus, and abundant rough endoplasmic reticulum that can only be discerned by electron microscopy. Based on the presence of cytoskeletal markers, myofibroblasts have been classified into 4 types as: Type V, VD, VA & VAD (V- Vimentin; D- Desmin; A- Actin). Myofibroblasts appear 4 to 6 days after initial injury and are commonly seen in the wound during the ensuing 2 to 3 weeks. Their disappearance is suspected to be via apoptosis. Although Gabbiani et al postulated that these cells were the “motor” that contracted a wound, more recent work with collagen lattices has suggested that fibroblasts in the central portion of the wound may be more critical to the contraction process <sup>[47]</sup>.

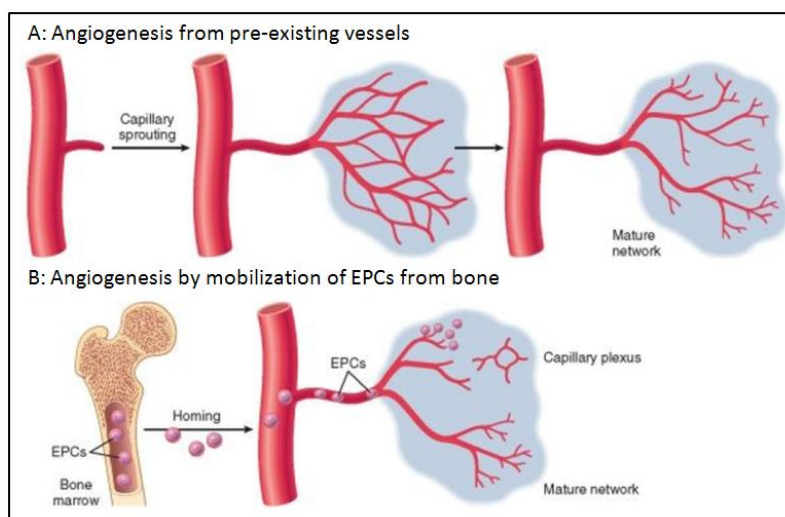
TGF-β and possibly other cytokines are involved in the wound contraction process. Wound contraction is sometimes not a desirable healing event. Wound contraction across joints can produce contractures that significantly limit function. In cases in which contraction inhibition is preferred, skin grafting, especially with thicker grafts, is used to limit contraction. Splints can also limit undesirable contraction in certain anatomic locations if utilized for prolonged periods.

**2(b). Granulation:**

New connective tissue begins to form approximately 2–4 days after wounding, and it is called granulation tissue due to its granular beefy red appearance (i.e., “proud flesh”). It consists mainly of components of the blood clot, fibroblasts and their progenitor cells that have homed into the area, new loose and primitive connective tissue ECM produced by wound fibroblasts, new and forming blood vessels and inflammatory cells.

Angiogenesis or Neovascularisation is a fundamental process to healing and becomes active from 2<sup>nd</sup> day after wounding <sup>[48]</sup>. Factors in the wound milieu that contribute to angiogenesis include high lactate levels, acidic pH, and decreased oxygen tension <sup>[49]</sup>. The severe degree of hypoxia in granulation tissue most likely results from both disruptions of the native vasculature and increased oxygen consumption by large number of proliferating cells. Angiogenesis involves the branching and extension of adjacent pre-existing vessels, but it can also occur by recruitment of Endothelial Progenitor Cells (EPCs) from the bone marrow <sup>[50]</sup>.





**Fig 6:** A- Angiogenesis from pre-existing vessels and endothelial cells to form capillary sprouts. **B** - Angiogenesis by migrated and differentiated EPCs that form a mature network by linking to existing vessels <sup>[50]</sup>

During angiogenesis, endothelial sprouts derive from intact capillaries at the wound periphery <sup>[51]</sup>. The sprouts grow through cellular migration and proliferation. Eventually, the endothelial sprout comes into contact with a sprout derived from a different capillary, and they interconnect generating a new capillary.

The angiogenic process is regulated mainly by FGF-2 <sup>[52]</sup> and VEGF <sup>[53]</sup>. Cytokine concentrations diminish as the wounded area becomes revascularized, and this flux in angiogenic cytokines may facilitate maturation of the vascular system. The composition of the primitive ECM in the granulation tissue has certain similarities with connective tissue during foetal development, and functionally it serves as a scaffold that contains cells and molecules that are necessary for subsequent tissue maturation into normal connective tissue <sup>[6, 54, 55]</sup>.

### 2 (c). Epithelialisation:

Following acute injury, reconstruction of injured epithelium is crucial for re-establishment of the barrier functions of the skin. Reconstruction of injured epithelium begins almost immediately after wounding. Incisional skin injuries, with a minimal epithelial gap, are typically re-epithelialized within 24 to 48 hours after initial injury <sup>[56]</sup>, although larger wounds can take much longer to regenerate a neo-epithelium. During the first 24 hours after injury, basal cells present at the wound edge elongate and begin to migrate across the denuded wound surface. If the initial injury does not destroy epithelial appendages such as hair follicles and sweat glands, these structures also contribute migratory epithelial cells to the healing process. These cells migrate across the wounded area essentially as a monolayer.

Approximately 24 hours after the initiation of cellular migration, basal cells at the wound edge begin to proliferate, contributing additional cells to the healing monolayer. The migration of epithelial cells continues until overlap is achieved with other epithelial cells migrating from different directions. At that point, ‘‘contact inhibition’’ results in cessation of cellular migration. The processes of cellular migration and proliferation occur under the control of various cytokines.

Epithelial cell migration requires the development of actin filaments within the cytoplasm of migratory cells and the disappearance of desmosomes and hemidesmosomes that link them to one another and to the basement membrane, respectively. These processes are dependent on changes in integrins expressed on the cell membranes <sup>[57]</sup>. If the epidermal basement membrane is intact, cells simply migrate over it. In wounds in which it has been destroyed, the cells initially begin to migrate over the fibrin–fibronectin provisional matrix <sup>[58, 59]</sup>. As they migrate across the matrix, however, epithelial cells regenerate a new basement membrane. Re-establishment of a basement membrane under the migrating cells involves the secretion of tenascin, vitronectin, and type I and V collagens <sup>[60]</sup>.

When contact inhibition is achieved, hemidesmosomes re-form between the cells and basement membrane, and tenascin and vitronectin secretion diminishes. The cells become more basaloid <sup>[61]</sup>, and further cellular proliferation generates a multilaminated neoepidermis covered by keratin. The neoepidermis is similar to the native epidermis, although it is slightly thinner, the basement membrane is flatter, and rete pegs that normally penetrate the dermis are absent.

### 3. The Remodelling Phase:

Scar remodelling begins to predominate approximately 21 days after injury. The rate of collagen synthesis diminishes and reaches coincidence with the rate of collagen breakdown. The downregulation of collagen synthesis is mediated by  $\gamma$ -interferon [62], TNF- $\alpha$  [63], and collagen matrix itself [21]. Matrix metalloproteinases (MMPs) are a family of at least 25 enzymes that break down different extracellular matrices and are intimately involved with collagen breakdown during the remodelling process. They are produced by a variety of cell types, and different cells generally synthesize different enzymes. The MMP activity within tissues is regulated by tissue inhibitors of metalloproteinases (TIMPs) [64]. The balance of MMPs and TIMPs within tissues is critical to wound remodelling and is regulated by cytokines.

The nature of the wound matrix changes with scar remodelling. Immature scar contains a disorganized array of fine collagen fibers, which is gradually replaced by thicker fibers arranged in an orientation paralleling skin stresses. In addition, the number of cross-links both within and between collagen molecules gradually increases. Normal skin shows a basket like weave pattern that is never completely reproduced with scar remodelling. Although seemingly not as complex as other aspects of the healing process, remodelling is essential to the formation of a strong wound.

The remodelling process is associated with a substantial increase in wound-breaking strength. Wound strength 1 week after injury is 3% of normal dermis. After 3 weeks, when the remodelling phase begins to predominate, the wound will have only approximately 20% the strength of normal dermis. At 3 months, however, the wound will have 80% the strength of normal dermis, with the significant increase in strength resulting from the contribution of remodelling. Remodelling will continue for up to 12 months after a wound is created, although scars never regain the strength of normal dermis.

### III. Conclusion

Thus we can say that wound healing takes place by an intricate interplay of various biomolecules under the influence of signals generated by injured cells. To sum up, all the events of wound healing has been described diagrammatically from Figure – 7 to Figure – 11 [65]:

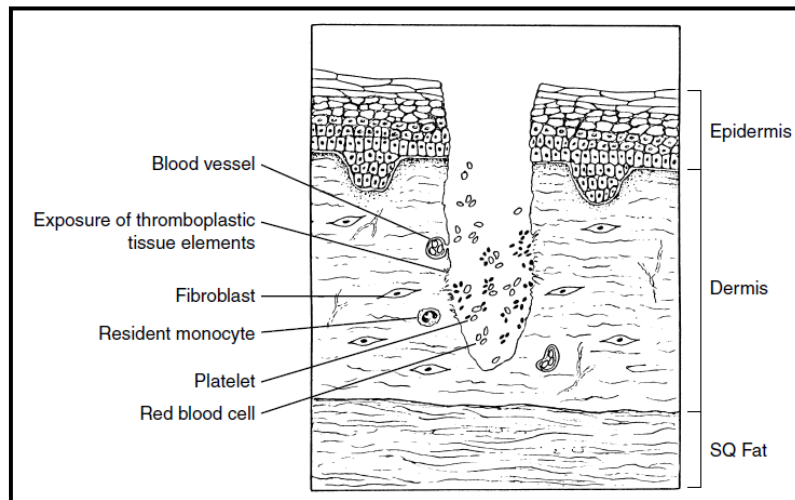
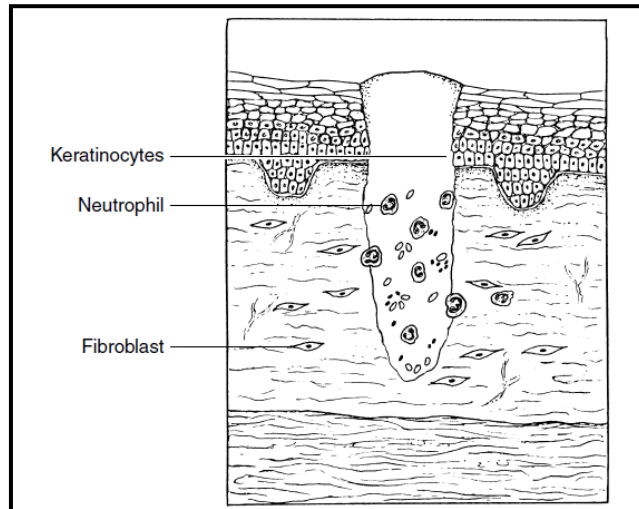
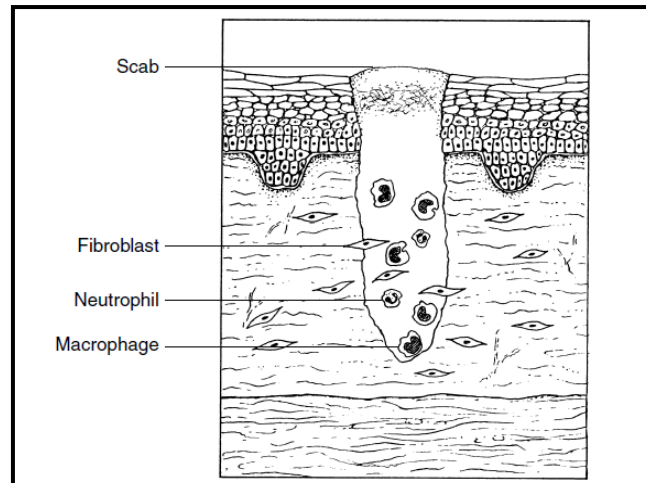


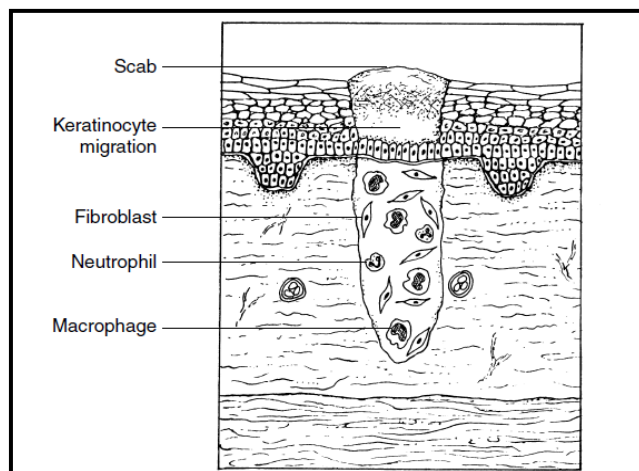
Fig – 7: Immediately after tissue injury, haemostasis is achieved by platelet degranulation and exposure of the tissue thromboplastic agents



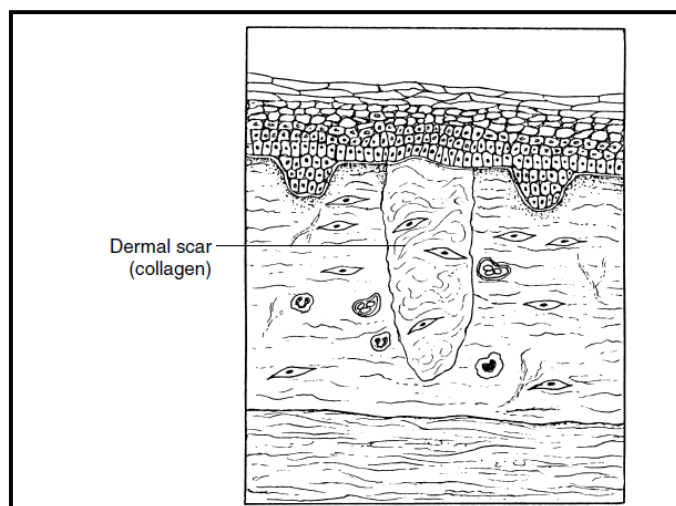
**Fig – 8:** Within 24 hours, a neutrophils efflux into the wound occurs. The neutrophils scavenge debris, bacteria and secrete cytokines for monocyte and lymphocyte attraction and activation. Keratinocytes begin migration when a provisional matrix is present.



**Fig – 9:** At 2 to 3 days after injury, the macrophages becomes the predominant inflammatory cell type in clean, non infected wounds. These cells then regulate the repair process by secretion of a myriad of growth factors, including types that induce fibroblast and endothelial cell migration and proliferation.



**Fig – 10:** Fibroblasts are activated and present by the wound by 3 to 5 days after injury. These cells secrete matrix components and growth factors that continue to stimulate healing. Keratinocyte migration begins over the new matrix. Migration starts from the wound edges as well as from epidermal cell nests at sweat glands and hair follicles in the centre of the wound.



**Fig – 11:** Scar formation is the outcome of healing in postnatal skin. Scar is composed of densely packed, disorganised collagen fibre bundles. Remodelling occurs up to 1 to 2 years after injury and consists of further collagen cross – linking and regression of capillaries which account for the softening of scar and its colour change from red to white.

### References

- [1]. Christgau M. Wound Management and Postoperative Care. *Perio – Periodontal Practices Today*. 2004; 1 (4): 293-310
- [2]. Saraf S, Parihar R. Sushruta: The first Plastic Surgeon in 600 B.C.. *The Internet Journal of Plastic Surgery*. 2006;4: 2.
- [3]. Zinn J, Swofford V. Quality Improvement Initiative: Classifying and Documenting Surgical Wounds. *Wound Care Advisor*. 2014; 3(1): e32-38
- [4]. Mangram AJ, Horan TC, Pearson ML, Silver LC, Jarvis WR. Guideline for Prevention of Surgical Site Infection. 1999; 20(4): 247-278
- [5]. Williams NS, Bulstrode CJK, O’Connell PR. *Bailey & Love’s Short Practice of Surgery*. 26<sup>th</sup> Edition. Taylor & Francis, 2013, Page No 25-32
- [6]. Clark RAF. Wound Repair. Overview and General Considerations. *The molecular and cellular biology of wound repair*. 2<sup>nd</sup> edn. New York, NY: Plenum Press. 1996; 3: 50
- [7]. Lawrence WT. Physiology of the acute wound. *Clin Plas Surg* 1998;25(3):321– 40
- [8]. Cines DB, Pollack ES, Buck CA, et al. Endothelial cells in physiology and in the pathophysiology of vascular disorders. *Blood* 1998; 91: 3527–3561
- [9]. White JD, Gerrard JM. Ultrastructural features of abnormal platelets: a review. *Am J Pathol* 1976;83:589– 632
- [10]. Hynes RO. Fibronectins. *Sci Am* 1986;254:42–61
- [11]. Deuel TF, Senior RM, Huang JS, et al. Chemotaxis of monocytes and neutrophils to platelet-derived growth factor. *J Clin Invest* 1982;69:1046–9
- [12]. Stiernberg J, Redin WR, Warner WS, et al. The role of thrombin and thrombin receptor activating peptide (TRAP-508) in initiation of tissue repair. *Thromb Haemost* 1993; 70: 158–62
- [13]. Guyton AC, Hall JE. *Textbook of Medical Physiology*. 11<sup>th</sup> Edition. Elsevier Saunders, 2006, Page No 457-468
- [14]. Spector WG, Willoughby DA: The Inflammatory Response. *Bacteriological Reviews* 1963, 27:117-149
- [15]. Kloth LC, McCulloch JM, Feedar JA. Wound healing. In: Kloth LC, McCulloch JM, Feedar JA, editors. *Wound healing: alternatives in management*. Philadelphia: FA Davis Company; 1990. p. 3– 13.
- [16]. Majno G, Shea SM, Leventhal M. Endothelial contraction induced by histamine type mediators: an electron microscopic study. *J Cell Biol* 1969;42:647–72
- [17]. Newman M G, Takei H, Klokkevold P R, Carranza F A. *Carranza’s Clinical Periodontology*. 10<sup>th</sup> Edition. India: Elsevier; 2006
- [18]. Werb Z, Banda MJ, Jones PA. Degradation of connective tissue matrices by macrophages: proteolysis of elastin, glycoproteins and collagen by proteinases isolated from macrophages. *J Exp Med* 1980;152:1340– 52
- [19]. Malawista SE, Montgomery RR, van Blaricom G. Evidence for reactive nitrogen intermediates in killing of staphylococci by human neutrophil cytoplasts. A new microbicidal pathway for polymorphonuclear leukocytes. *J Clin Invest* 1992;90:631–6
- [20]. Monaco JL, Lawrence WT. Acute wound healing an overview. *Clin Plast Surg*. 2003 Jan; 30(1): 1-12
- [21]. Madden JW, Peacock Jr EE. Studies on the biology of collagen during wound healing: rate of collagen synthesis and deposition in cutaneous wounds of the rat. *Surgery* 1968;64:288– 94
- [22]. Simpson DM, Ross R. The neutrophilic leukocyte in wound repair: a study with antineutrophil serum. *J Clin Invest* 1972;51:2009–23
- [23]. Newman SL, Henson JE, Henson PM. Phagocytosis of senescent neutrophils by human monocyte derived macrophages and rabbit inflammatory macrophages. *J Exp Med* 1982;156:430– 42
- [24]. Fauci AS. Resistance to HIV-1 infection: its in the genes. *Nat Med* 1996;2:966– 7
- [25]. Darby IA, Hewitson TD. Fibroblast differentiation in wound healing and fibrosis. *Int Rev Cytol* 2007; 257: 143–179
- [26]. Sorrell JM, Caplan AI. Fibroblasts—a diverse population at the center of it all. *Int Rev Cell Mol Biol* 2009; 276: 161–214
- [27]. Guyot C, Lepreux S, Combe C, Doudnikoff E, Bioulac-Sage P, Balabaud C, Desmoulière A. Hepatic fibrosis and cirrhosis: the (myo)fibroblastic cell subpopulations involved. *Int J Biochem Cell Biol* 2006; 38: 135–151
- [28]. Toriseva M, Kähäri VM. Proteinases in cutaneous wound healing. *Cell Mol Life Sci* 2009; 66: 203–224
- [29]. Seppä` H, Grotendorst GR, Seppä` S, et al. Platelet-derived growth factor in chemotactic for fibroblasts. *J Cell Biol* 1982;92:584– 8
- [30]. Postlethwaite AE, Keski-Oja L, Moses HL, et al. Stimulation of the chemotactic migration of human fibroblasts by transforming growth factor-β. *J Exp Med* 1987; 165: 251– 6

- [31]. Westermark B, Blomquist W. Stimulation of fibroblast migration by epidermal growth factor. *Cell Biol Int Rep* 1980;4:649–54
- [32]. Grzesiak HH, Piershbacher MD. Shifts in concentrations of magnesium and calcium in early porcine and rat wound fluids activate the cell migratory response. *J Clin Invest* 1995;95:227–33
- [33]. Reed MJ, Puolakkainen P, Lane TF, et al. Differential expression of SPARC and thrombospondin 1 in wound repair: immunolocalization and in situ hybridization. *J Histochem Cytochem* 1993;41: 1467–77
- [34]. Carter SB. Cell movement and cell spreading: a passive or an active process? *Nature* 1970;255:858–9
- [35]. Parks WC. Matrix metalloproteinases in repair. *Wound Repair Reg* 1999;7:423–33
- [36]. Parsons SL, Watson SA, Brown PD, et al. Matrix metalloproteinases. *Br J Surg* 1997;84:160–6
- [37]. Assoian RK, Sporn MB. Type beta transforming growth factor in human platelets: release during degranulation and action on vascular smooth muscle cells. *J Cell Biol* 1986;102:1217–23
- [38]. Werb Z, Tremble P, Damsky CH. Regulation of extracellular matrix degradation by cell–extracellular matrix interactions. *Cell Differ Dev* 1990;32:299–306
- [39]. Nanci A. *Ten Cate's Oral Histology Development, Structure and Function*. 8<sup>th</sup> Edition. India: Elsevier; 2012
- [40]. Ignatz RA, Massague J. Transforming growth factor beta stimulates the expression of fibronectin and collagen and their incorporation into the extracellular matrix. *J Biol Chem* 1986;261:4337–45
- [41]. Hering TM, Marchant RE, Anderson JM. Type V collagen during granulation tissue development. *Exp Mol Pathol* 1983;39:219–29
- [42]. Caterson B, Lowther DA. Changes in the metabolism of the proteoglycans from sheep articular cartilage in response to mechanical stress. *Biochim Biophys Acta* 1978;540:412–22
- [43]. Ketchum LD, Smith J, Robinson DW, et al. Treatment of hypertrophic scars, colloids and scar contractor by triamcinolone acetamide. *Plast Reconstr Surg* 1966; 38:209–18
- [44]. Hassel JR, Kimura JH, Hascall VC. Proteoglycan core protein families. *Ann Rev Biochem* 1986; 55: 539–67
- [45]. Gilkes DM, Semenza GL, Wirtz D. Hypoxia and the extracellular matrix: drivers of tumour metastasis. *Nat Rev Cancer* 2014 Jun;14(6):430-9
- [46]. Gabbianni G, Ryan GB, Majno G. Presence of modified fibroblasts in granulation tissue and their possible role in wound contraction. *Experientia* 1971;27: 549–50
- [47]. Erlich HP. The role of connective tissue matrix in wound healing. In: Hunt TK, editor. *Growth factors and other aspects of wound healing: biological and clinical implications*. Alan R Liss, Inc.; 1988. p. 243–58
- [48]. Grotendorst GR, Pencev D, Martin GR, et al. Molecular mediators of tissue repair. In: Hunt TK, Heppenstall RB, Pines E, et al, editors. *Soft and hard tissue repair: biological and clinical aspects*. New York: Praeger; 1984. p. 20
- [49]. Witte MB, Barbul A. *Wound healing: general principles of wound healing*. *Surg Clin N Am* 1997; 77: 509–28
- [50]. Robbins and Cotran. *Pathological Basis of Disease*, 8<sup>th</sup> Ed (2010)
- [51]. Folkman J, Klagsbrun M. Angiogenic factors. *Science* 1987; 235: 442–7
- [52]. Gospodarowicz D, Neufeld G, Schweigerer L. Fibroblast growth factor: structural and biologic properties. *J Cell Physiol* 1987;5(Suppl 15):15–26
- [53]. Gospodarowicz D, Abraham J, Schilling J. Isolation and characterization of a vascular endothelial cell mitogen produced by pituitary-derived follicular stellate cells. *Proc Natl Acad Sci USA* 1989;86: 7311–5
- [54]. Gurtner GC, Werner S, Barrandon Y, Longaker MT. Wound repair and regeneration. *Nature* 2008; 453: 314–321
- [55]. Larson BJ, Longaker MT, Lorenz HP. Scarless foetal wound healing: a basic science review. *Plast Reconstr Surg* 2010; 126: 1172–1180
- [56]. Nanney LB, Magid M, Stoscheck CM, et al. Comparison of epidermal growth factor binding and receptor distribution in normal human epidermis and epidermal appendages. *J Invest Dermatol* 1984;83: 385–93
- [57]. Cavani A, Zambruno G, Marconi A, et al. Distinctive integrin expression in the newly formed epidermis during wound healing in humans. *J Invest Dermatol* 1993;101:600–4
- [58]. Clark RA, Lanigan JM, DellaPelle P, et al. Fibronectin and fibrin provide a provisional matrix for epidermal cell migration during wound re-epithelialization. *J Invest Dermatol* 1982; 79: 264–9
- [59]. Wysocki AB, Grinnell F. Fibronectin profiles in normal and chronic wound fluid. *Lab Invest* 1990; 63: 825–31
- [60]. Mackie EJ, Halfter W, Liverani D. Induction of Tenascin in healing wounds. *J Cell Biol* 1988;107:2757–67
- [61]. Odland G, Ross R. Human growth repair: epidermal regeneration. *J Cell Biol* 1968;39: 135–51
- [62]. Granstein RD, Murphy GF, Margolis RJ, et al. Gamma interferon inhibits collagen synthesis in vivo in the mouse. *J Clin Invest* 1987; 79: 1254–8
- [63]. Buck M, Houglum K, Chojkier M. Tumor necrosis factor-alpha inhibits collagen alpha 1(I) gene expression and wound healing in a murine model of cachexia. *Am J Pathol* 1996;149:195–204
- [64]. Brew K, Kinakarpandian J, Nagase H. Tissue inhibitors of metalloproteinases: evolution, structure and function. *Biochim Biophys Acta* 2000;1477:267–83
- [65]. Lorenz HP, Longaker MT. *Wounds: Biology, Pathology and Management*. In: Norton JA, ed. by. *Essential Practice of Surgery: Basic Science & Clinical Evidence*. New York: Springer; 2003. p. 77–88