

Thoracoabdominopagus- A Case Report

Manohar R¹, Savitha H C², Dakshayini C³

¹(Assistant Professor, Department of OBG, Mandya Institute of Medical Sciences, Mandya, India)

²(Associate Professor, Department of OBG, Mandya Institute of Medical Sciences, Mandya, India)

³(Junior Resident, Department of OBG, Mandya Institute of Medical Sciences, Mandya, India)

Abstract: Conjoined twinning is rare, occurring in about 1% of monozygotic twins with an estimated incidence ranging from 1:30,000 to 1:2,00,000 live births and 1 in 650 to 900 twin deliveries. Hereby we present a case report on thoracoabdominopagus at 22 weeks admitted for termination of pregnancy.

Key Words: Abdominopagus, conjoined, monozygotic, monoamniotic, twins, thoracopagus

I. Introduction

Conjoined twinning is rare, occurring in about 1% of monozygotic twins with an estimated incidence ranging from 1:30,000 to 1:2,00,000 live births and 1 in 650 to 900 twin deliveries. An increased incidence of 1:14,000 to 1:25,000 is described in various parts of south east Asia and Africa. There is a reported female preponderance of 3:1.

II. Case Presentation

Smt. XX 35 year old lady with G2P1L1 with 22 weeks of gestation with previous LSCS was admitted to the hospital as her anomaly scan showed conjoined twins (Thoracoabdominopagus). Her married life was 9 yrs. She had undergone Emergency LSCS (Indication – PROM with failed induction) at a private hospital and it was a male baby, 6 yrs, alive and healthy. She had a regular ANC at a private hospital and had USG done at 8th week and was found to have single live foetus (twins not detected). Her first trimester was uneventful. Her anomaly scan at 21st week in a different Ultrasonographic center revealed-

- Monozygotic monoamniotic conjoined twin live intrauterine gestation, thoracopagus type.
- Single cardia noted.
- Talipes deformity on right and rudimentary lower limb on left side.

Repeat Ultrasonography was done at higher centre which showed- **THORACOABDOMINOPAGUS**

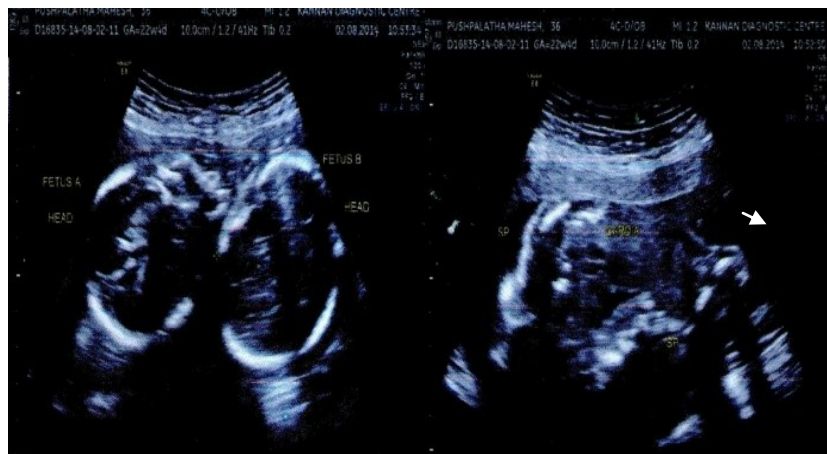

Fig 1. Both fetal heads at same levels Fig 2. Both fetal spine with cardia at same level

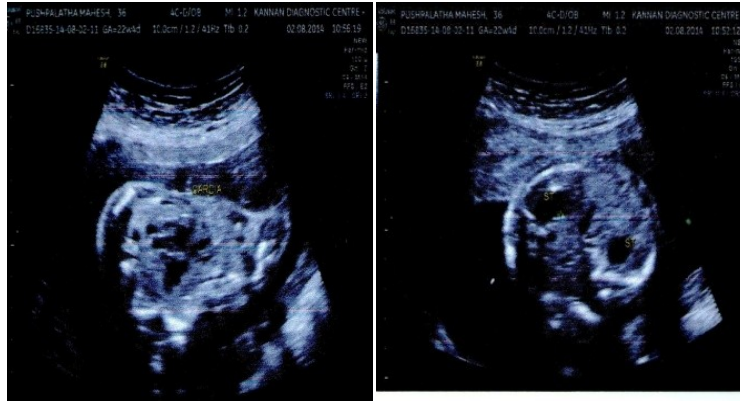


Fig 3.Both twins sharing a Single cardia Fig 4.Both fetal stomach at the same level

Routine blood investigations were found to be normal. After explaining the risks and complications of Conjoined twins (Thoracoabdominopagus), patient and her attenders were willing for termination of pregnancy. After admission, on taking risk consent for induction of abortion, induction was done with Extra amniotic Ethacridine lactate instillation following foley's bulb insertion. She was treated with Inj. cefotaxime 1g IV BD ATD and Inj Metronidazole 100ml IV TID. Foleys bulb was expelled after 12hrs of insertion and patient had moderate uterine contractions of 3/10 min /25-30 secs. On per-vaginal examination : Cervix was soft, central , 80% effaced , Os -3cm dilated , membranes bulging and presenting part above brim. Inj. Oxytocin 10 IU in 10 RL at 10 drops/min was started and titrated accordingly for 2 hrs till she had good uterine contractions of 4/10 min / 40 -45 secs. After 2hrs, Per-Vaginal findings were- Cervix-soft, 80% effaced, os 3 cm dilated. Membranes were accidentally ruptured at the time of examination and clear liquor was drained. After few minutes patient complained of severe pain at the operated site and had bleeding PV (fresh bleeding about 50ml). Her pulse rate was 100bpm , BP was 100/60mmHg and scar tenderness was present. So clinical suspicion of Rupture uterus was made and patient was posted for Emergency laparotomy after explaining the risk to patient attenders and after arranging 1 unit of blood.

Per operative findings were-

- Omental adhesions to the peritoneum and to the lower uterine segment.
- Lower uterine segment was well formed.
- Bladder densely adherent to lower uterine segment

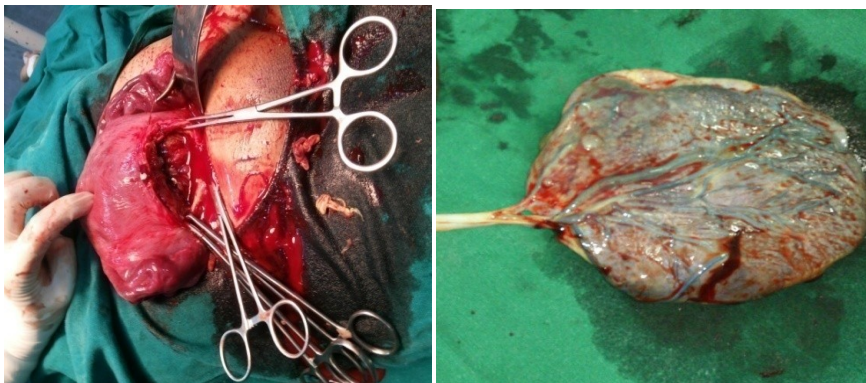


Fig 5.Hysterotomy(transverse lower segment) Fig 6. Battle dore placenta

Extraction of an alive conjoined female twins of Thoracoabdominopagus type with single umbilical cord and single Battledore placenta was done. Both female babies weighed about 750 grams and died after 10 minutes after

- Uterus was intact and about 50gms of retroplacental clot was present
- Conjoint twins shared three upper limbs (one rudimentary) and three lower limbs (one rudimentary)

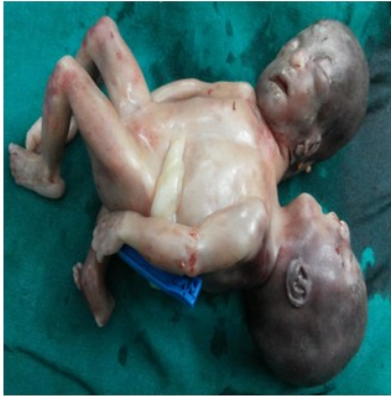

Fig 7. Conjoined twins (thoracoabdominopagus)

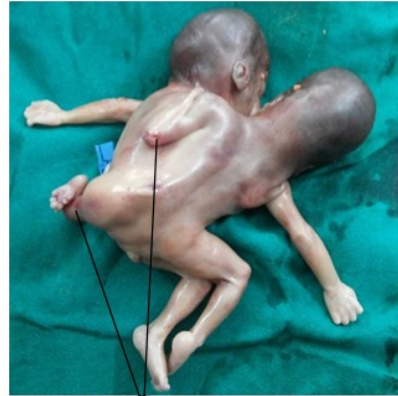

Fig 8 Rudimentary upper and lower limb

Intraoperative and postoperative period was uneventful.

III. Discussion

Conjoined twinning is rare, occurring in about 1% of monozygotic twins with an estimated incidence ranging from 1:30,000 to 1:2,000,000 live births and 1 in 650 to 900 twin deliveries. An increased incidence of 1:14,000 to 1:25,000 is described in various parts of south east Asia and Africa. There is a reported female preponderance of 3:1[1]

Two different theories have been suggested on the formation of conjoined twins. According to the “fission” theory 13-15 days after the fertilization embryonic disc has an incomplete separation, whereas in the “fusion” theory, two separate monozygotic embryonic discs undergo a secondary association[2].

The classification of conjoined twins is based on the site of union. The suffix “pagus” is commonly used to mean “fastened”. Thoracopagus has a shared thorax and 90% have a shared heart. Ileopagus is connected at the time of the iliac bone. Asymmetric and parasitic conjoined twins are rarer anomalies of monozygotic monoamniotic twins, consisting of an incomplete twin attached to the fully developed body of the co-twin[3].

When monoamniotic twin pregnancy is determined by ultrasonography, the fetuses should be carefully examined for conjoinment aspects. Similar positioning of the twins, lack of independent movements, non-detaching fetus bodies during positional changes, a single umbilical cord containing more than three blood vessels, excessive flexion of fetal spinal column, lack of position changes in the twins among examinations performed at different intervals will be helpful for diagnosing conjoined twins.[4]

Prognosis, obstetric management and treatment planning are determined by the degree of fusion and sharing of organs.[5]

Detailed evaluation of degree of union and number of shared organs is required to predict the viability and prognosis of the fetuses. Magnetic resonance imaging and computed tomography both provide excellent anatomic and bone detail, demonstrating organ position, shared viscera, and limited vascular anatomy but the consensus appears to be that optimal evaluation is obtained with a combination of ultrasound and magnetic resonance imaging where the prognosis is poor, early diagnosis enables the proper counselling of the family and gives parents the option of termination. In this particular case, diagnosis of conjoined twins was done at routine anomaly scan and induction was tried as literature favours good success rate up to 22-24 weeks. However as the patient was a case of previous LSCS and had bleeding per vagina after rupture of the membranes, suspicion of ruptured uterus led to Emergency Laparotomy.

IV. Conclusion

Conjoined twins are rare and early diagnosis by skilled sonologist can be very useful for counselling for termination of pregnancy as it carries high morbidity and mortality. CT and MRI can also be very useful in diagnosing conjoined twins.

References

- [1]. Saunitra A. Inamdar, Shruthi S. Goel, Vaidehi S. Subhedar –A thoracopagus conjoined twins with myelomeningocele: an unusual case. -International journal of Reproduction, Conception, Obstetrics and Gynecology. 2012 dec;1(1):61-63.
- [2]. Spencer R theoretical and analytical embryology of conjoined twins; part 1 embryogenesis. Clin anat. 2000;13:36-53.
- [3]. Aysegul Okuzoglu, Ozlem Moraloglu, Ayla Aktulay, Yapik Engin-Ustun, Sevgi Celen, Leyla Mollalahmutoglu. - Conjoined twins: A Case Report of Thoraco-abdominopagus-Ankara universitesi Tip Fakultesi Mecmuasi 2011, 64(3).
- [4]. Chandima P Suriyarachchi-Surgical experience with conjoined twins. -Sri Lanka Journal of child health, 2010;39:64-66.
- [5]. Kiran Trivedi, D. Darukshan Anjum-Thoracocephalopagus twin presented as a case of ruptured uterus. - Sen C, Celik E, Vural A, Kepkep K. Antenatal diagnosis and prognosis of conjoined twins a case report. J Perinat Med 2003;31:427-430.