

External Ophthalmomyiasis In Urban Area: A Case Report

Jihad Chaakouk , Younesse Hidan, Mohamed Reda Bentouhami, Adil Mchachi,
Leila Benhmidoune, Rayad Rachid, Mohamed El Belhadji.

Department Of Adult Ophthalmology, Faculty Of Medicine And Pharmacy, Hassan Ii University-Casablanca,
Hospital 20 August 1953,Ibn Rochd Uhc, Morocco.

Abstract :

Introduction : Ophthalmomyiasis is an ocular myiasis caused by parasitism of humans by fly larvae, most often due to *Oestrus ovis*, which parasitizes the nasal passages of sheep, very common condition among shepherds. Diagnosis and treatment are easy. In the absence of treatment, there is a risk of internal ophthalmomyiasis.

Materiels and methods : thirty year old patient who presented to emergency room for itching and red right eye following eye contact with a fly.

Discussion : Human ophthalmomyiasis is cosmopolitan, mainly found in rural areas among population living in direct contact with ungulates, sheep and goats. Contamination of humans occurs accidentally by depositing larvae by the female fly in the eye during spring to autumn. Diagnosis is easy by slit lamp, treatment is based on mechanical elimination of larvae combined with antibiotic prophylaxis. In the absence of treatment, there is a risk of internal ophthalmomyiasis with panuveitis and retinal detachment.

Conclusion : External ophthalmomyiasis is a very common condition among shepherds. Its frequency outside pastoral areas is relatively rare. Prevention is essential, particularly in developing countries, with education of population at risk.

Date of Submission: 09-02-2024

Date of acceptance: 19-02-2024

I.Introduction:

Ophthalmomyiasis is an ocular myiasis caused by parasitism of humans by fly larvae, most often due to *Oestrus ovis*, which parasitizes the nasal passages of sheep [1].

Ocular involvement occurs in approximately 5% of cases of human myiasis. Cases of external ophthalmomyiasis have been reported in various parts of the world mainly in rural areas but it is not exceptional in urban areas [2].

The prognosis of external ophthalmomyiasis is generally good after adequate treatment unless it transforms into internal ophthalmomyiasis, which is a serious condition that can compromise the visual prognosis [3].

II.Observation :

We report the case of a 30-year-old patient with no notable pathological history, who presented to the emergency room with a red and painful right eye with foreign body sensation, intense itching and tearing **following eye contact with a fly**, 24 hours before admission.

The inspection reveals conjunctival hyperemia, visual acuity is preserved, the slit lamp examination **finds 3 small mobile and photophobic translucent larvae, at the cornea (fig 1) and conjunctiva (fig 2-A 2-B)**, the fluorescein test is negative.

The rest of the ophthalmological examination is perfectly normal, **eliminating internal damage**, as well as the examination of the left eye.

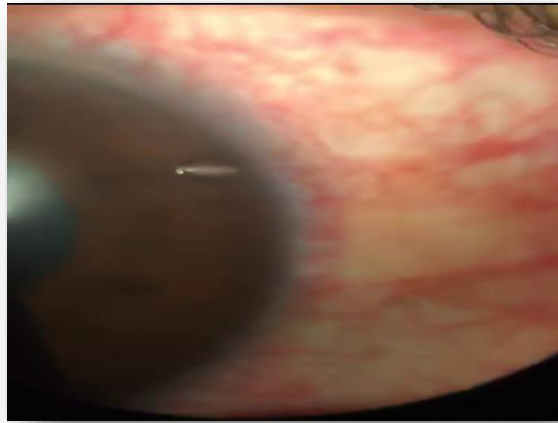


Figure 1 : slit lamp image magnification x25

larvae at the cornea

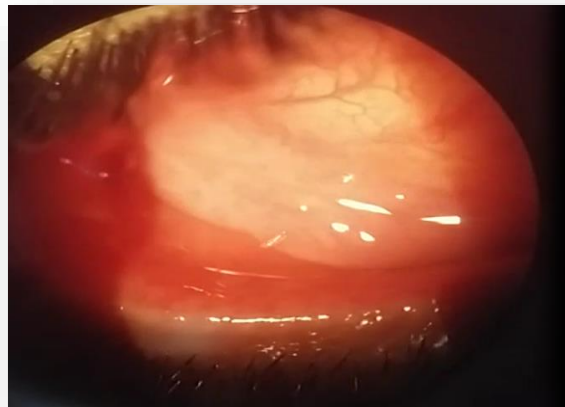


Figure 2-A : slit lamp image magnification x10

Larvae at the conjunctiva



Figure 2-B : magnification x40

We proceeded by **mechanical extraction** of the larvae associated with washing the eyes and **lacrymal passages** abundantly with saline after topical anesthesia followed by topical treatment of antibiotics (based on macrolide), corticosteroids and lubricant agents.

The evolution was marked by the regression of functional and physical signs after 24 hours.

III. Discussion :

Human ophthalmomyiasis is cosmopolitan, but seems more frequent in mediterranean countries and the near-east, it is mainly found in rural areas among population living in direct contact with ungulates, sheep and goats [4], unlike our patient who lives far from any breeding areas. The estrus ovis is a fly whose larval development necessarily takes place on intermediate hosts (sheeps and goats) [5]. Contamination of humans occurs accidentally by depositing larvae by the female fly in the eye during spring to autumn [4]. Our patient consulted in october (autumn).

The clinical signs of ophthalmomyiasis are summarized by the signs of acute conjunctivitis. The interrogation note direct eye contact with a fly, which was the case with our patient. Diagnosis is generally easy using the slip lamp.

Treatment is based on mechanical elimination of larvae combined with antibiotic prophylaxis to prevent a secondary infection.

In the absence of treatment, there is **a risk of internal ophthalmomyiasis, with risque of panuveitis and retinal detachment**[6].

IV. Conclusion :

External ophthalmomyiasis is a very common condition among shepherds. Its frequency outside pastoral areas is relatively rare.

Treatment consists of the extraction of these larvae combined with a saline solution and local antibiotic prophylaxis.

Prevention is essential, particularly in developing countries, with education of population at risk for rapid and early treatment of this zoonosis.

References :

- [1]. Ducourneau D. Les Myiases Oculaires. *Med Trop*, 1981;41:511-4.
- [2]. Mc Ziemianski, Lee Ky, Fn Sabates. Ophthalmomyiase Interne. *Arch Ophtalmol*. 1980; 98 : 1588-1589.
- [3]. Gupta Vp, Baveja Uk. Ophthalmomyiasis Externa Provoquee Par Le Botole Nasal Du Mouton Oestrus Ovis. *Indian J Ophthalmol*. 1988; 36 :41-42.
- [4]. Dorchies Ph. Physiopathologie Comparee De La Myiase A Oestrus Ovis (Linne 1761) Chez L'homme Et Chez Les Animaux. *Bull Acad Nat Med*, 1977;181:673-84.
- [5]. Rodhain F, Perez C. Les Dipteres Myiasigenes In : *Precis D'Entomologie Medical Et Veterinaire*. Paris : Maloine Ed ; 1985. P. 249-65
- [6]. R.Khoumiri, L.Gaboune, A.Sayouti, A.Moutaouakil. Ophthalmomyiase Interne : A Propos De Deux Cas. *J Fr Ophtalmol.*, 2008 ; 31, 3, 299-302