

# Clinical Trials On Stem Cell Therapy In Dermatology: Where Are We Today?

Ranju Choudhary<sup>1</sup>, Rakesh Sharma<sup>2</sup>

Departments Of Dermatology<sup>1</sup> And Biochemistry<sup>2</sup>,

SMMH Government Medical College, Saharanpur, Pilkhahi 247232 Saharanpur, India

## Abstract:

Adipose derived mesenchymal stem cells undergo multipotential differentiation to biotransform into variety of tissues such as adipocytes, smooth muscle cells, osteocytes, chondrocytes, glia, neurons, myeloid and erythroid hematopoietic cells for their wider dermatological use in treatment of autoimmune disease, wound healing and skin neoplasms. Clinical trials indicate their limited use due to several challenges and complications. A lot of skin tissue engineering issues on mechanisms, molecular pathways still need investigations to develop full-proof safe adipose cell derived skin transplantation interventional treatment. The present feasibility report reviews clinical trials and explores challenges with possible solutions in different skin diseases in the light of previous clinical approved trials completed so far. The review on limitations, challenges and solutions will facilitate the purpose of stem cell therapy in clinical intervention for clinical researchers, academic physicians, industrial and clinical scientists in dermatology.

**Key Words:** Dermatology clinical trials, Adipose derived stem cells, Skin diseases, Adipose derived Stem Cell transplantation

Date of Submission: 05-02-2025

Date of Acceptance: 15-02-2025

## I. Introduction

The dermis and interfollicular epidermis represent large reservoir of mesenchymal adult stem cells with plasticity and ability of repair and regeneration. The dermis, epidermis and hair follicle are three major *in vivo* MRI visible skin structures [1]. Adipose-derived mesenchymal stem cells (ASCs) are available with self-renewal, differentiation and plasticity or transdifferentiation properties [2,3]. They undergo multipotential differentiation into adipocytes, smooth muscle cells, osteocytes, chondrocytes, glia, neurons, myeloid and erythroid hematopoietic cells for treatment of untreatable graft-versus-host disease, autoimmune induced diseases, systemic lupus erythematosus, scleromyxedema, alopecia, Merkel cell carcinoma, pemphigus vulgaris, psoriasis, epidermolysis bullosa, wound healing and skin neoplasms in dermatology clinics with some success [4-9]. These ASCs are derived from autologous fat without any ethical issue for transplantation use. Over years, several case reports indicated unavoidable complications and multiple lacunae after stem cell transplantation during follow up of disease status [7,10]. These complications are post-transplant induced tumorigenesis, dysfunctions of signaling pathways leading to impaired differentiation, proliferation and infections secondary to graft failure. To avoid all these complications need guidelines on time of intervention, optimized conditioning regimens, post-intervention care and cost-effectiveness before taking up clinical studies or trials for a safe public use [11].

The present status of ongoing clinical trials on embryonic cells and stem cell derived products approved by FDA serves the purpose of public awareness and limited utility of available stem cell therapy options to treat rare skin diseases otherwise uncured by routine medical treatment as shown in tables 1 and 2. The PubMed, Medline search and review of key words dermatology, stem cell therapy trials, autologous, allogenic showed articles as tabulated in Table 1 based on randomized controlled trials [12]. Other case studies, review articles also serve the purpose of stem cell intervention for clinical researchers, academic physicians, industrial and clinical scientists in dermatology. Other existing guidelines are European Group for Blood and Bone Marrow Transplantation (EBMT), British Society of Blood and Bone Marrow Transplantation (BSBMT), American Society of Blood and Bone Marrow Transplantation (ASBMT), Indian Council Medical Research.

## Adipose Derived Stem Cells in Clinic Use

Few completed clinical trials are reported on official website <https://clinicaltrials.gov/> with key word adipose derived stem cell treatment in skin diseases. Out of these 19 trials, only 8 trials are completed and 7 trials in progress shown with challenges in treatment and need of stem cell therapy with NCT codes in Table 1.

**Table 1.** List of clinical trials showing challenges using stem cell therapy in dermatology.

Condition	Number	Study Phase	Study design	Study type	NCT code /Reference	Challenges in Management
Ischemia with O <sub>2</sub> insufficiency, angiopathy (Diabetic foot ulcer)	1	Phase 1	Multicentric randomized controlled trial of Allogenic ASCs; MRC	PriMatrix, dermal repair scaffold Interventional	NCT02394886	To reduce pressure toward area
Depressed scar	1	Phase 2 Phase 3	Autologous ASCs	Interventional adipocell ANTG adip injected SC	NCT00992147	Failure of casts, roots
Androgenic alopecia	2	Phase 3	Allogenic ASCs; MRC	Interventional SVF, PRP Stem cells, lipofilling	NCT01255212	Unstable alopecia immune rejection
Skin rejuvenation for burn skin loss	1	Phase 2	Autologous ASCs- Keratinocytes; RC	Interventional SVF split skin graft liposuction	NCT013993072 0,28	Nonmelanoma neoplasia skin cancer
Facial rejuvenation		Phase 3		Interventional Intradermal injection	NCT08739530	Adverse events, vitals, facial recontouring
Lipodystrophy	1	Phase 2	Autologous ASCs	Liposuction of antra cells	NCT01828723	Adverse events
Vitiligo	2	Phase 1	Autologous ESCs	Interventional ESCs; intralesion injection	13	Unstable vitiligo
Skin scar, Cutis laxa	1	Phase 3	Autologous ASCs	Laser therapy	NCT00992147	Scar
Facial fat grafting for wrinkles, aging	1	Phase 3	Autologous ASCs	Lipoatrophy, SVF	NCT08739530	Monitoring reoccurrence
Wound healing	1	Phase 1	Autologous MSCs	Interventional pilot study	14	Reoccurrence
Blistering dismutation COL7A1 collagen (Dystrophic epidermolysis bullosa)	3	Phase 2	Allogenic MSCs, fibroblasts; RC	Intradermal direct injections for wound healing	15,16,17	Aggressive sq. cell carcinoma
Atopic dermatitis	1	Phase 2	Umbilical cord SCs	Interventional injection	18	Immunological rejection
Limb ischemia in diabetes	3	Phase 1	Autologous ASCs, double blind PC	Interventional & safety; injection in femoral vein	NCT01257776 NCT016633761 9,20,21	Non-vascularized
Deep burn	1	Phase 1	Bone marrow SCs	Prospective case control	22	Infection, infiltration, stasis
Biopsy, PASI >10 Graft-vs-host disease	2	Phase 1,II	Autologous MSCs	Interventional	23,24	Steroid resistance
Inflammatory autoimmunity (Psoriasis vulgaris and arthritis)	1	Case report	Autologous ASCs; umbilical cord MSCs	Interventional iv injection MSCs	NCT03765987, 25	induration
Systemic Lupus Erythematosus	2	Pilot studies	Umbilical cord SCs Allogenic MSCs	Multicenter study Pilot study apheresis procedure	NCT007675226 27	autoreactive
Thromboangiitis	1	Phase 2	Autologous ASCs	Interventional vascostem	NCT01302015	Necrosis in leg

obliterans(Buerger's disease)				IRNL		
Occlusion of vessels(Romberg disease)	1	Phase 2	Autologous ASCs	Interventional ANT/Gadip injection	NCT00992147	Reoccurrence

NCT: Grant number code; SVF: Stromal vascular fraction; MRC: Multicentric Randomized Controlled; DBPC: Double blind placebo controlled

Principles of allogenic hematopoietic stem cell therapy were described in five steps including stem cell mobilization, harvesting and collecting stem cells, conditioning of recipient, stem cell infusions, recovery [12]. Clinical trials suggest the stem cell therapy good outcome in systemic sclerosis, SLE, pemphigus; promising results in psoriasis, vitiligo; poor evidence in wound healing scleroderma, alopecia, melanoma; discouraging results in epidermolysis bullosa and Merkel cell carcinoma [12].

### **Criteria of clinical evaluation and stem cell transplantation treatment: How much possible of post-transplant complications and management?**

Monitoring follow-up and monitoring over 3 months to years is required in chronic or acute skin diseases. Management of recurring acute infection(s) or tumorigenesis or impaired proliferation takes care of recovery process in short time while in chronic cases it may require over 2-3 years for reconstructed skin collagen and extracellular matrix. Regulation of metabolites, electrolytes, fluids and glucose homeostasis is crucial during rejuvenation. For example, diabetic control plays major role during rejuvenation of tissue and recovery from diabetic foot ulcer and ischemia. Proven stem cell therapy of skin disease treatments and post-recovery management is presented in Table 2.

**Table 2:** Follow-up of stem cell post-transplanted benefits and post-recovery management of infections, sepsis and healing. References [14-25] are cited in Table 1 for clinical evaluation, follow-up and management of following diseases.

Skin diseases: Clinical evaluation	Follow-up and monitoring criteria	Management and post-recovery measures
Diabetic foot ulcer: dissolved soft foot, ischemia	Follow-up for 3 months for collagenesis and immediate action of impaired glucose homeostasis and lab tests	Management of infection(s) over 2-3 years and reconstructed collagen and extracellular matrix
Depressed scar: Dark pigmented collagen-elastin non-repairable skin scar	Follow-up for 3 months after dermabrasion therapy for natural skin contour changes at scar site	Monitoring recovery rate of normal pigmentation weekly, infection/healing control, tyrosinase levels
Androgenic alopecia: dead hair follicle, roots	Follow-up for hair regrowth, hair root vascularization with local spray oils	Monitoring hair root follicle in anagen phase infection, healing control, immune rejection, neoplasia, non melanoma
Skin deep burns: loss of deep tissues, blisters postules, skin layer loss	Follow-up for 2-3 weeks after therapy for rejuvenating skin, no inflammation	Monitoring fresh skin growth, managing infections, dryness
Facial rejuvenation: face	Shaping of bone ossification, matrix	Shielding the facial appearance
Lipodystrophy: Obesity	Liposuction and follow-up for 6 months	Managing diet control, slim foods
Vitiligo: white depigmented macula	Koebernization/repigmentation and monthly follow-up	Management of depigmentation size change
Skin scar: Cutis laxa	Regrowing fresh skin tissue at scar site	Manage infection/healing control
Aging skin: wrinkles	Facial fat grafting, monthly follow-up	Applying creams, managing skin
Dystrophic epidermolysis-sis bullosa: fragile skin	Follow-up of 3 months for fragility, trauma, friction, cracks, blisters	Managing skin cracks, blisters with creams, moisturizers, antibiotics
Atopic dermatitis: eczema, itching, irritation	Follow-up of 3 months for watching relief and irritation	Managing with PUVA, steroids, antiseptic, moisturizers, if slow cure
Limb ischemia: pruritis, lichenification residues blood flow ulcers	Dissolving clot, spasm, sore and follow-up post-therapy tissue reconstruction six-monthly	Managing with medication, wound treatment, lipid control, life style, target limb amputation
Deep burn: blisters, scars	Follow-up subsided scars in zones of stasis, blisters, pain	Manage edema, fluids, sepsis, infection, granulation of tissue, inflammation
Graft-vs-host disease: rash, cramps, dry eyes	Follow-up of short breath, dry mouth, muscle weakness, tight joints, swelling	Managing with steroids, antibiotics, NSAIDs, immunosuppressants
Psoriasis vulgaris: scales red, itchy skin patches	Follow-up any remission, recycles of skin scales, cracks, burning, swelling	Managing life style, postules, red rashes, joint pain, infections, if any
Systemic Lupus Erythromatosus: fatigue	Follow-up of joint swelling, ulcer, pain, rash, clotting, anemia, problems	Conditioning treatment to eliminate WBC cyclophosphamide, prednisone anti-inflammatory corticosteroids, creams, antimalarials
Buerger's disease: thrombi, gangrene	Follow-up of tingling, pain, trademill, inflammation, pale, red or blue tints	Managing claudication, smoking, spinal cord stimulation, TBPI, TcO2, ABPI, PFWD scores
Romberg disease:	Follow-up the repaired tissue or reoccurring	Manage and prevent any wasted skin tissue

hemifacial atrophy	progress of disease	
--------------------	---------------------	--

#### Engineered adipose-derived stem cells action inside body

To overcome complications, different implant methods of engineered ASCs for tissue specific differentiation are available towards adipogenesis, osteogenesis, chondrogenesis, myogenesis of endothelial cells. These ASCs are biofabricated and engineered by growing them inside porous 3D scaffolds made of: hyaluronic acid (for chondrogenesis); chitosan (for neurogenesis, hepatogenesis); polycaprolactone nanofibers (for cardiomyogenesis); poly lactide-co-glycolide (for chondrogenesis); silk fibroin (for adipogenesis); and nano graphene oxide, laponite silicate (for osteogenesis, neurogenesis). Inside skin 3D-post transplantation scaffolds, ASCs behave depending on three factors: growth factors, miRNAs and extracellular signal related kinase pathways [7].

1. Growth factors are such as fibroblast GF-2 for endotheliogenesis, osteogenesis, chondrogenesis; vascular endothelial GF for capillary formation; platelet derived GF-BB for angiogenesis; bone morphogenic protein for osteogenesis and chondrogenesis; TGF- $\beta$ 1 for proliferation.

2. Recently gene expressing non-coding segments of microRNA(miR-196a, miR-26a, miR-138 for osteogenesis; miR-27and miR-21 for adipogenesis; miR-194 for chondrogenesis) in ASCs showed up or down regulation role to target proteins required in self-renewal, multipotential differentiation of adipoblasts. Good example is miR-194 upregulation of sox-5 protein inhibited chondrogenesis and *vice versa* [12].

3. Extracellular signal related kinase ERK pathways regulate ASC proliferation and differentiation [13]. These kinases belong to mitogen activated protein kinase family of MAP-Kinase or serine-threonine kinase. External hormones, molecular and physical stimuli act on ASC target receptors and activate MAP kinases to dephosphorylate to regulate downstream events leading to different types of differentiations. Different ERK phosphorylation stimulators or inhibitors are: PD98059 in osteogenesis inhibition, dexamethasone in adipogenesis stimulator. TGF- $\beta$ 1signaling activates SMAD proteins to increase chondrogenesis for self-renewal [14]. Presently, several MAP Kinases are known to reduce or control cancers of skin, liver, brain, prostate, squamous head and neck cancer, thyroid and breast [8].

At present, long term safety issue is still a big challenge in applying ASC transplantation for reconstructive or regenerative medicine. It needs: 1.More systematic studies on long-term biomaterial biocompatibility; 2.Better tissue engineering methods to develop 3D scaffolds; 3.Long-term in vivo experiments to confirm the status of differentiation.

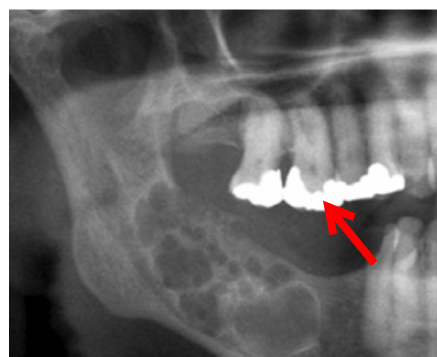
#### Stem cell clinical trials support in skin disease treatments

For medical treatment, 37 clinical trials are completely approved for breast reconstruction, fistula, liver cirrhosis, cardiovascular, vascular, urinary, osteoarthritis, Buerger's disease, brain injury, cerebellar ataxia, spinal cord injury, limb ischemia, obesity, rheumatoid arthritis, sepsis, Romberg disease, scar. However, only some of these are approved beyond phase 3 in dermatology (see the Table 2). For understanding the stem cell study design, criteria and protocol, two examples are given below.

Case 1. A 55 years old man had a third 10 cm ameloblastoma recurrence in parametaphyseal area of mandible. A tissue engineered 3D construct was used for culturing and harvesting ASCs.

Method: The 3D scaffold was fabricated of 60% porous  $\beta$ -tricalcium phosphate 1.4-2.8 mm sized granules plus recombinant human bone morphogenetic protein-2 having adipocytes (harvested from abdominal wall) in cultures of DMEM plus 15% serum for 21 days. In post-harvested ASC cells, differentiation showed osteogenesis by surface marker expression. Before seeding differentiated cells, ASCs attached to 3D-TCP scaffolds were incubated for 48 hours in basal medium 12 mg recombinant human bone morphogenetic protein-2 medium [15]. These ASCs encapsulated inside scaffolds were attached to titanium mesh near the reconstruction plate over mandible gap.

Outcome: It served as dental implant successful reconstruction as shown in Figure 1



**Figure 1:** A Dental Implant Is Shown With Gum Reconstruction Plate And Maxillary Filling Over Mandible Gap.

Case 2. A simple protocol design of stem cell therapy: Example of vitiligo

A protocol of vitiligo stem cell treatment by autologous melanocytes and keratinocytes in suspension

**Personal history** of age, sex, history of family, habits, behavior, diet, life style, physiological, physical signs, symptoms of body with skin features

**Enrollment** of inclusion criteria (Body surface area with vitiligo >60%) without h/o pregnancy, UV, cream

**Induction phase** in selected 12 square pigmented 2 x 2 cm test regions on back, lab tests

**Treatment phase** allocated to receive autologous stem cells in suspension or in 3D scaffold containing  $7 \times 10^6$  per dL 95% viable cells

**Follow up** of observation and analysis of repigmentation after 30 months for any erythema, ecchymosis, edema, pain, keloid etc.

**Monitoring and Management of complications** by timely care of any complication, infection, diet or life style modification, prevention and prophylaxis care.

Other clinical protocols may be developed appropriately for stem cell therapy.

## II. Discussion

The success of clinical trials in stem cell therapy of skin diseases still suffers from poor guidelines, poor regulatory definitions, post-transplantation reoccurring infections, complications, non-compliance of drug interactions, impaired homeostasis. The unknown behavior of in vivo transplanted stem cells further increases the events of auto-graft rejections, side-effects and more chances of tumorigenesis, proliferation and unwanted differentiation of grafted stem cells. In fact, more investigations are needed with thoroughly understood mechanisms of transplanted stem cell behavior inside tissue in specific environments.

Possibly, very few phase 3 clinical trials are approved for clinical practice in dermatology as it is evident in above tables reflecting the limited use of stem cell therapy with minimum promise. The major success is cited in pemphigus, systemic sclerosis, systemic lupus erythematosis, psoriasis, epidermolysis bullosa, wound healing, vitiligo, scleromyxedema, alopecia, melanoma, Merkel cell carcinoma [15-24].

The reason of slow pace in clinical research is partly due to identifying new challenges in management and post-recovery follow up of careful record of stem cell therapy consequences. The tables indicate the difficult scene of clinical trials on intervention and follow-up of recovery. Moreover, present day scenario leaves the public with poor impression of "use at own risk and face the scene of no option left". Hopefully, industries, cell and tissue banks, pharma industries will contribute effectively to manufacture the right needed stem cell banks to offer opportunities to public as option of rare disease treatments in near future [25]. On other side of regulatory government bodies, it is utmost present need of clear scientific and legal unanimous guidelines and regulatory framework of rules to minimize the public hazards and mishappenings[26].

In India, Indian Council of Medical Research has given National Guidelines for Stem Cell Research, 2017, and Department of Biotechnology (DBT) framed guidelines on screening, stem cell categorization, stem cell manipulation, stem cell manufacturing and criteria for stem cells procurement and banking, therapeutic uses, publicity and marketing advertisements [27]. At present, Ministry of Health and Family Welfare permitted 60 centers to offer stem cell therapy in India including Western railway hospital, Vadodara, IKDRC, Ahmedabad and New Civil Hospital, Surat [27]. Major challenges identified in clinical trials still are ethical considerations (consents, confidentiality, possible transmission disease screening and transplant procedure risks); legalization of unproven stem cell therapies for recommendation and implementation; graft rejection in allografting; in-culture induced pluripotent stem cell tumorigenicity; no quality control of stem cell processing; individual patient specific conditioning regimens, intervention timing; and cost-effectiveness [28].

## III. Conclusion

Presently available clinical trials indicate the possibility of timely given stem cell treatment to treat rare inherited skin diseases when traditional and conventional treatment methods fail to show results. However, clinical practice is far from routine due to either incomplete results limited to clinical trials in phase 1 or 2 and rarely phase 3 and 4. Such uncertainty of clinical trials or misrepresented experimental studies, case reports or observations leads to no conclusion. More and more use and experience of clinical trial results will ensure the utility of trials in dermatology in near future.

### Conflict of interest

Authors have no conflict of interest.

## References

- [1] Herzog EL, Chai L, Krause DS. Plasticity Of Marrow-Derived Stem Cells. *Blood* 2003; 102: 3483-93.

- [2] Monti M, Perotti C, Del Fonte C, Cervio M, Redi CA. Fondazione IRCCS Policlinico San Matteo, Pavia (Italia) Stem Cells: Sources And Therapies. *Biol Res.* 2012;45:207-214.
- [3] Prodingier CM, Reichelt J, Bauer JW, Laimer M, Current And Future Perspectives Of Stem Cell Therapy In Dermatology. *Ann Dermatol* 2027; 29: 667-87.
- [4] Ulloa-Montoya F, Verfaillie CM, Hu WS. Culture Systems For Pluripotent Stem Cells. *J Biosci Bioeng* 2005;100:12-27.
- [5] Choi HR, Byun SY, Kwon SH, Park KC. Niche Interactions In Epidermal Stem Cells. *World J Stem Cells* 2015; 7: 495-501.
- [6] Mohammadi S, Malek Mohammadi A, Nikbakht M Et Al. Optimizing Stem Cells Mobilization Strategies To Ameliorate Patient Outcomes: A Review Of Guidelines And Recommendations. *Int J Hematol Oncol Stem C Ells Res.* 2027; 11: 78-88.
- [7] Hsu YS, Cushing MM. Autologous Stem Cell Mobilization And Collection. *Hematol Oncol Clin N America.* 2016; 30: 573-589.
- [8] Suslova IM, Theodoropoulos DS, Cullen NA Et Al. Pemphigus Vulgaris Treated With Allogeneic Hematopoietic Stem Cell Transplantation Following Non-Myeloablative Conditioning. *Eur Rev Med Pharmacol Sci.* 2010; 14:785-788.
- [9] Swart JF, Delemarre EM, Van Wijk F, Boelens JJ Et Al. Hematopoietic Stem Cell Transplantation For Autoimmune Diseases. *Nat Rev Rheumatol.* 2017; 13: 244-256.
- [10] Nash RA, Mcsweeney PA, Crofford LJ, Abidi M Et Al. High Dose Immunosuppressive Therapy And Autologous Hematopoietic Cell Transplantation For Severe Systemic Sclerosis: Long –Term Follow Up Of The US Multicenter Pilot Study. *Blood* 2007;110: 1388-1396.
- [11] Elmaadawi IH, Mohamed BM, Ibrahim ZA, Abdou SM, El Attar YA, Youssef A, Et Al. Stem Cell Therapy As A Novel Therapeutic Intervention For Resistant Cases Of Alopecia Areata And Androgenetic Alopecia. *J Dermatolog Treat* 2018;29:431-40.
- [12]. Khanpur S, Gupta S, Gunaabalaji DR. Stem cell therapy in dermatology. *Indian J Dermatol Venereal Leprol* 2021. Doi: 10.25259/IJDVL1920.
- [13]. Menaa F. Latest approved therapies for metastatic melanoma: What comes next? *J Skin Cancer* 2013;2013:735282.
- [14]. Houben R, Wischhusen J, Menaa F, Synwoldt P, Schrama D, Brückner EB, et al. Melanoma stem cells: Targets for successful therapy? *J Dtsch Dermatol Ges* 2008;6:541-6.
- [15]. Owczarczyk-Saczonek A, Krajewska-Włodarczyk M, Kruszevska A, Placek W, Maksymowicz W, Wojtkiewicz J. Stem cells as potential candidates for psoriasis cell-replacement therapy. *Int J Mol Sci* 2017; 18:2182.
- [16]. Xu J. Therapeutic applications of mesenchymal stem cells for systemic lupus erythematosus. *Adv Exp Med Bioi* 2018;1089:73-85.
- [17]. Alchi B, Jayne D, Labopin M, Demin A, Sergeevicheva V, Alexander T, et al. Autologous haematopoietic stem cell transplantation for systemic lupus erythematosus: Data from the European Group for Blood and Marrow Transplantation registry. *Lupus* 2013;22:245-53.
- [18]. Leng XM, Jiang Y, Zhou DB, Tian XP, Li TS, Wang SJ, et al. Good outcome of severe lupus patients with high-dose immunosuppressive therapy and autologous peripheral blood stem cell transplantation: A10-year follow-up study. *Clin Exp Rheumatol* 2017;35:494-9.
- [19]. Burt RK, Han X, Gozdzia P, Yaung K, Morgan A, Clendenen A, et al. Five year follow-up after autologous peripheral blood hematopoietic stem cell transplantation for refractory, chronic, corticosteroid dependent systemic lupus erythematosus: Effect of conditioning regimen on outcome. *Bone Marrow Transplant* 2018;53:692-700.
- [20]. El-Darouti M, Fawzy M, Amin I, Abdel Hay R, Hegazy R, Gabr H, et al. Treatment of [dystrophic epidermolysis bullosa with bone marrow non-hematopoietic stem cells: A randomized controlled trial. *Dermatol Ther* 2016;29: 96-100.
- [21]. Lu D, Chen B, Liang Z, Deng W, Jiang Y, Li S, et al. Comparison of bone marrow mesenchymal stem cells with bone marrow-derived mononuclear cells for treatment of diabetic critical limb ischemia and foot ulcer: A double-blind, randomized, controlled trial. *Diabetes Res Clin Pract* 2011;92:26-36.
- [22]. Fisch SC, Gimeno ML, Phan JD, Simerman AA, Dumesic DA, Perone MJ, et al. Pluripotent nontumorigenic multilineage differentiating stress enduring cells (Muse cells): A seven-year retrospective. *Stem Cell Res Ther* 2017;8:227.
- [23]. Shin H, Ryu HH, Kwon O, Park BS, Jo SJ. Clinical use of conditioned media of adipose tissue-derived stem cells in female pattern hair loss: A retrospective case series study. *Int J. Dermatol* 2015;54:730-5.
- [24]. Menaa F. Viral etiology of merkel cell carcinoma: Implications in diagnosis, prognosis, therapy and prevention. *Int J Clin Dermatol Res* 2015;3:1-2.
- [25]. Indian Council of Medical Research. National Guidelines for Stem Cell Research; 2017. <http://www.icmr.nic.in/guidelines>.
- [26]. Sabha L. Government of India, Ministry of Health and Family Welfare, Lok Sabha, Unstarred Question No. 3448. Published Online; 2017.
- [27]. Tiwari SS, Desai PN. Unproven stem cell therapies in India: Regulatory challenges and proposed paths forward. *Cell Stem Cell.* 2018;23: 649-52.
- [28]. Sharma R. Stem Cells and Tissue Engineering in Medical Practice: Ethical and Regulatory Policies. *Current Drug Targets.* 20(4): 388 – 398. DOI: 10.2174/1389450119666180831095830.