

Orthodontic approach to gemination: a clinical case report

Araceli García Peña¹, Daniel Cerrillo Lara², Rubén David Pérez Figueroa³,
Mario Herrera Gracia⁴, Fernando Aguilar Pérez⁵, Iván Zúñiga Herrera⁶.

¹(Orthodontic Specialty/ Universidad Autónoma de Baja California, México)

²(Orthodontic Specialty / Universidad Autónoma de Baja California, México)

³(Orthodontic Specialty/ Universidad Autónoma de Baja California, México)

⁴(Orthodontic Specialty / Universidad Autónoma de Baja California, México)

⁵(Orthodontic Specialty / Universidad Autónoma de Yucatán, México)

⁶(Orthodontic Specialty / Universidad Autónoma de Yucatán, México)

Abstract:

Background: Dental gemination is an abnormality of size and shape that occurs when a dental germ attempts to divide in two by invagination, resulting in the incomplete formation of two teeth. This dental anomaly causes discrepancies in the arch and interdigitation, producing deviation of the midline, crowding, late eruption of other teeth, some form of malocclusion in the dentition, among others.

Case Report: 16-year-old female patient with a geminated lower right incisor, asymptomatic that requires multidisciplinary treatment to achieve functional and aesthetic harmony of her teeth.

Discussion: The approach for this clinical case was more conservative than previous studies by opting for Finkelstein's second option, accompanied by a root canal treatment and interproximal enamel reduction (IPR). A posterior restorative treatment on the tooth with gemination is suggested to improve the aesthetics of the tooth and cover the exposed dentin tissue.

Results: The geminated tooth was integrated into the arch with an ideal anatomy, the shape of the arches are more uniform, and the dental crowding was released. A functional occlusion molar and canine class I were obtained and by incorporating the geminated tooth with an ideal anatomy avoiding dental extractions.

Conclusion: There are few registered cases carried with orthodontics, despite this the orthodontist must be able to identify the anomaly and by knowing the options to solve the problems that may be present to be able to plan an effective treatment.

Key Word: Orthodontics, gemination, dental anomaly.

Date of Submission: 20-08-2022

Date of Acceptance: 04-09-2022

I. Introduction

Different dental anomalies are found randomly when performing different diagnostic studies by the orthodontist prior to start the orthodontic treatment¹⁻³.

Gemination is an abnormality of size and shape that originates when a tooth germ attempts to divide in two by invagination, resulting in the incomplete formation of two teeth. It can be a partial or total invagination as well as involve the dentin and/or enamel or even the dental pulp. Twinned teeth usually have a single root with a wide root canal⁴⁻⁶.

This dental anomaly causes discrepancies in the arch and interdigitation, producing midline deviation, dental crowding, late eruption of other teeth, some form of dental malocclusion, among others. It usually manifests itself to a greater extent in the incisor teeth, mainly the upper ones, however, there are cases that occur in other teeth, including molars and premolars³⁻⁵.

Gemination and fusion are dental anomalies that have similar clinical and radiographic characteristics and they may result from the deviation of the development of the ectodermal and mesodermal linings during morphological differentiation of the dental bud, making them difficult to differentiate from each other and both are referred as "twin teeth" or "double teeth"^{1, 2, 4, 5, 7}.

The exact etiology of the "double tooth" is unknown, however, it may be associated with some syndromes such as achondroplasia and chondroectodermal dysplasia, in addition there is evidence that this condition has a familial tendency and may be due to a variety of genetic, environmental factors, traumas, vitamin deficiency or systemic diseases³⁻⁸.

Gemination and fusion have a very limited prevalence in orthodontic cases, with 0.23% and 0.07%, for fusion and gemination, respectively. According to studies, the prevalence of gemination is more common in the deciduous dentition, with 0.1% in the permanent dentition and 0.2% in both dentitions. In patients who present it in a primary dentition, it is common for them to manifest this anomaly in their permanent dentition^{4,5,9}. Geminate teeth are mostly unilateral^{5,6}.

The morphology of the double tooth is not esthetically pleasing because deep defects are produced, in the form of a groove or fissure, at the junction between the two affected teeth. Usually, double teeth are asymptomatic and if they are esthetically acceptable, they do not require treatment, however, when such condition causes aesthetic and/or functional problems, due to the extension of these fissures or grooves subgingivally makes the tooth susceptible to the accumulation of dental bacterial plaque, causing cavities and periodontal problems, endodontic complications, asymmetries and malocclusions, then therapy is unavoidable^{5,6,10}.

Gemination has different treatment approaches including "not treat it", interproximal enamel reduction (IPR), surgical separation followed by aesthetic recontouring, and endodontic therapy of the remaining portion of the tooth and orthodontics. Another option to consider for the treatment of this anomaly is the extraction of the tooth with the posterior prosthetic approach^{10,11}. In cases that require approaches from different areas to solve aesthetic and/or functional problems, multidisciplinary treatment for these anomalies is essential. Orthodontics plays a significant role in this aspect because it is the specialty that allows the correction and management of occlusal and aesthetic alterations^{9,12}.

II. Material And Methods: Case Report

A 16-year-old female patient went to the Orthodontics clinic stating as a reason for consultation: "I want to align my teeth." In the anamnesis, the parents denied previous orthodontic treatment, as well as any type of systemic disease or medical treatment that could interfere with the procedure.

The extraoral clinical analysis showed a mesomorph patient with apparent facial asymmetry, mesofacial and convex profile; an obtuse nasolabial and mentolabial angle, as well as a forced lip seal.

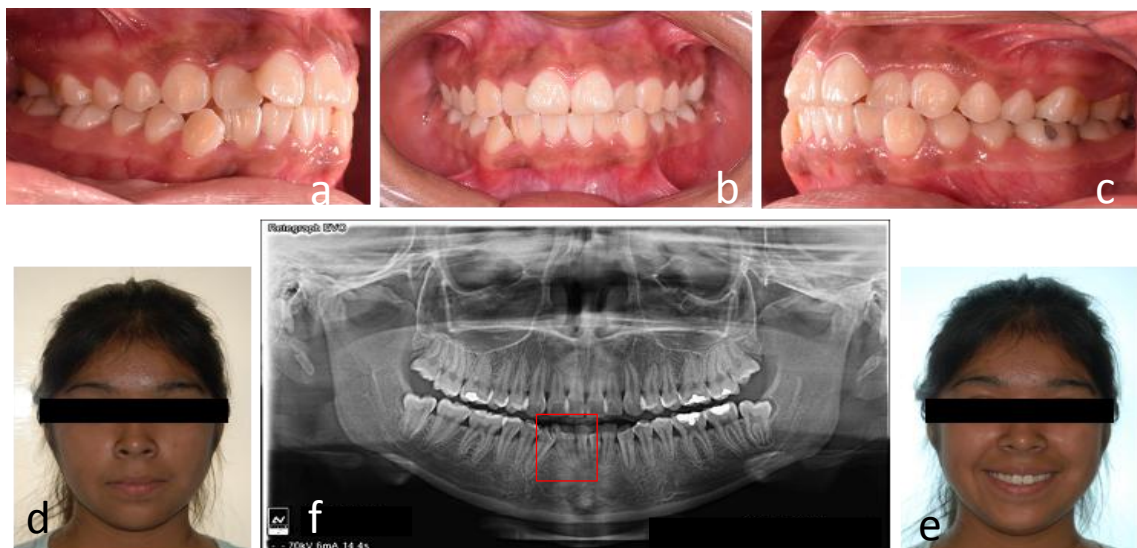


Figure 1. Facial photographs. Intraoral photographs. Initial panoramic x-ray.

In the intraoral clinical analysis, intraoral photographs and study models showed an ovoid upper and lower arch, a permanent dentition, a thin periodontal biotype, moderate anterior, upper and lower dental crowding, a bilateral molar and canine class I relationship, mismatched dental midlines, vertical and horizontal overbite within the norm (Figure 1).

The lower right lateral incisor presents dental gemination, according to Mader's rule, which is misaligned and asymptomatic. The mesiodistal diameter of the vestibular face of the clinical crown exceeds the normal width, showing a marked inciso-gingival groove in the center of the tooth, which doesn't have cavities or previous restorative treatment. Free of pathological data at the periodontal level and with physiological dental mobility; pulp vitality tests were positive and not increased. The differential diagnosis is established with a fused tooth; when doing the dental count, no supernumerary teeth were observed and all the teeth were present in the mouth, therefore, the diagnosis of a geminate tooth was established as the main cause of crowding in the

lower dental arch. In the periapical intraoral radiograph, a single root was observed, no radiolucency is associated with that tooth and the lamina dura was intact.

According to the cephalometric analysis, the patient presented a skeletal class II with a vertical growth pattern, as well as upper and lower incisors and proinclined.

	Norm	Patient
SNA	82° ± 2°	92°
SNB	80° ± 2°	85°
ANB	2° ± 2°	7°
SND	76° ± 2°	78°
Segment SL	51mm ± 2	48mm
Segment SL	22mm ± 2	20mm
Ang Go-GN/SN	32° ± 2°	33°
Plane Ocl/SN	14° ± 2°	14°
Ang Is/NA	22° ± 2°	16°
Distance Is/NA	4mm ± 2	3mm
Is/ ENA-ENP	70° ± 2°	115°
Ang Is/SN	103° ± 2°	108°
Ang Is/NB	25° ± 2°	38°
Distance Ii/NB	4mm ± 2	9mm
Ii/ Go-Gn	90° ± 2°	100°
Interincisal angle	131° ± 2°	119°

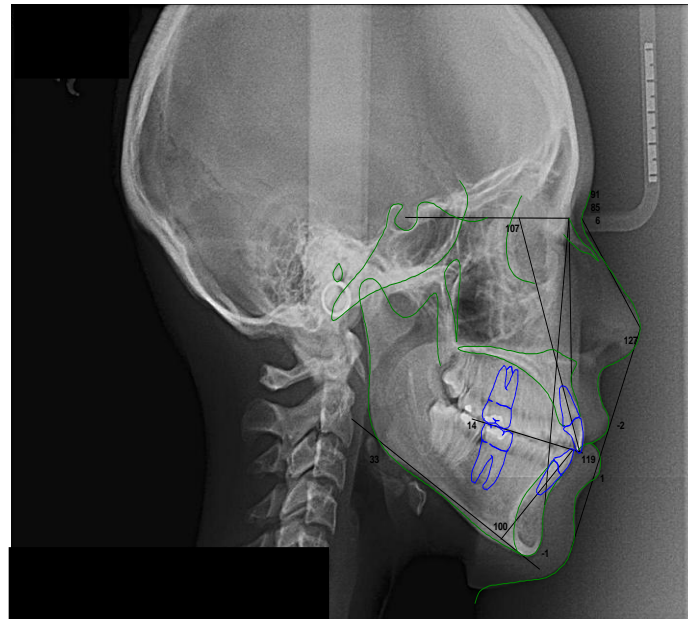


Table 1.Lateral cephalogram analysis summary.**Figure 2.** Lateral cephalogram.

The orthopantomography revealed 28 permanent teeth present in the mouth, with the presence of the upper and lower third molars, the lower right lateral incisor with an apparent double tooth anomaly, height of the symmetric branches and asymmetric condyles, in addition to a uniform bone density with a crown root ratio 1:2. No apparent pathologies are observed.

Case Report Location:The study was made in the orthodontic specialty program, at Universidad Autónoma de Baja California, Campus Tijuana, México.

Treatment Plan

Upper and lower fixed appliances (MBT Slot 0.018"). Alignment and leveling. Upper and lower conformation with sequence of arches. Create a gap to include the tooth with gemination and perform interproximal reduction of the mesiodistal width to integrate it into the dental arch. Harmonization of arches. Root torque. Removable upper appliance retention. Restore geminate tooth.

Treatment objectives

The objectives of the treatment were to preserve the tooth with gemination through the multidisciplinary treatment of orthodontics, endodontics, and prosthodontics to improve the dental discrepancy and the facial profile without the need for dental extractions.

Case evolution

The treatment consisted in the placement of a fixed appliances MBT (0.018") for alignment and leveling. An open spring was placed to create a gap for the tooth. Interproximal enamel reduction (IPR) was performed to compensate for the dental disproportion, as well as to give a similar anatomy to her counterpart. The patient was referred to the endodontic specialty for root canal treatment.

The interproximal enamel reduction (IPR) was made in the upper arch, occlusal stops were placed on molars with the aim of intruding these pieces and achieving an anti-clockwise rotation of the mandible, which

would help us to improve the patient's profile. The arches continued to be harmonized, the proclination of the lower incisors was improved, torque was given and then the appliances were removed, and the retention phase was entered after the orthodontic treatment with removable appliances.

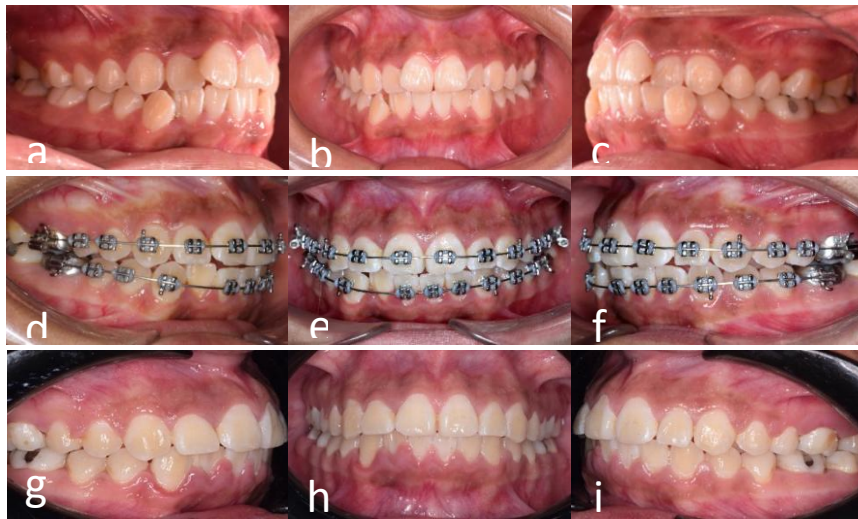

Figure 4. Intraoral photographs. a, b and c initial photographs. d, e and f treatment progression photographs. g, h, and I final photographs.

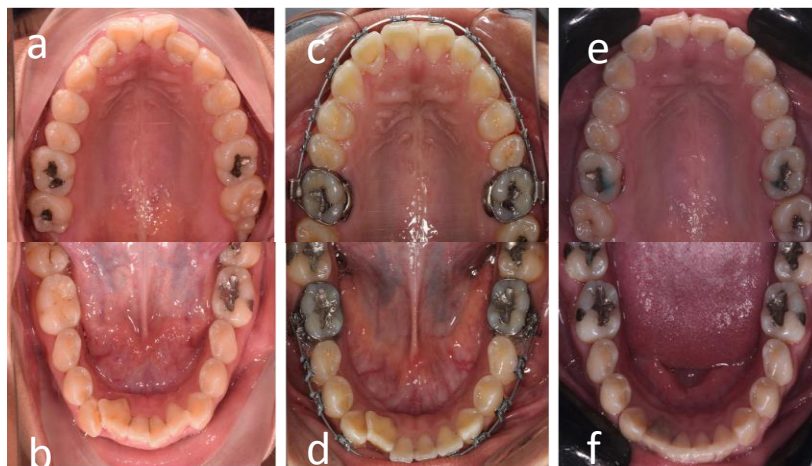


Figure 5. Occlusal intraoral photographs. a and b initial photographs. c and d treatment progression photographs. e and f final photographs.

III. Result

As a result of the treatment, the tooth with gemination was integrated into the mandibular arch, the shape of the arches is more uniform and the dental crowding was released. The definitive restoration of the tooth that presented gemination was recommended to the patient and was referred to the prosthodontist to manage the treatment alternatives due to the interproximal enamel reduction that was necessary to achieve the success of the treatment. We obtained a functional occlusion, molar and canine class I, incorporating the double tooth with an ideal anatomy avoiding extractions.

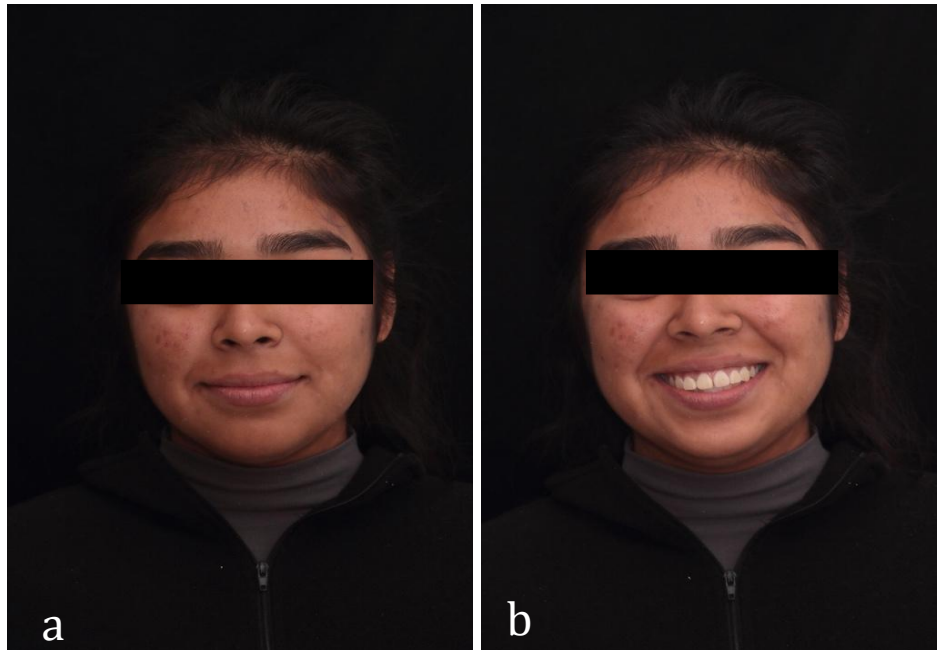


Figure 6. Final facial photographs.

IV. Discussion

According to Oliveira et al., the aesthetic and functional implications of geminated teeth usually require a multidisciplinary restorative, endodontics, periodontal and orthodontic approach¹⁵.

The Mader's "Two tooth rule" is very useful to diagnose and see the differences between fusion and gemination tells us that we can use the term fusion, when the teeth in the arch are less in number after counting the fused teeth as one, while, if the abnormal tooth is counted as one and the number of teeth in the dental arch is normal, it is most likely a gemination or fusion between normal and supernumerary teeth⁴. The present case was diagnosed as gemination, because this anomaly is characterized by presenting a normal number of teeth.

In a retrospective investigation of 8 cases with dental fusion or gemination, Finkelstein found 4 different ways to perform orthodontic treatment, from just aligning and leveling the arches without altering the dental anatomy, interproximal enamel reduction of the mesiodistal dimension of the affected tooth, extraction of the adjoining tooth and keep the anomalous tooth intact: as the fourth alternative, a surgical odontosection⁶.

Regularly a tooth with gemination with an increased mesiodistal dimension, decreases the interarch space; therefore, the clinician is forced to recover the normal measurements of the tooth in question, reducing the dental width. Root canal treatment is usually necessary to avoid sensitivity because the pulp chamber is also enlarged. Once the endodontics is finished, an interproximal enamel reduction (IPR) is performed to eliminate dental asymmetry and with orthodontics it is possible to place the tooth in an adequate position in order to eliminate or avoid occlusal problems. In the permanent dentition, surgical separation of the teeth is possible, with subsequent orthodontic alignment and restoration to reshape the crown. If it is not possible to remodel or reduce a double tooth with a single canal, extraction may be the alternative, and then proceed to orthodontic and/or prosthetic treatment^{9,14}.

Currently there are few cases registered in scientific research involving orthodontic treatment in patients with dental gemination, due to the low incidence of this anomaly and the possible complications that orthodontic treatment may present, as a consequence of the roots of these teeth offer resistance to movement in the body, however, thanks to the great similarity between gemination and dental fusion, the procedure to restore function and aesthetics is identical in both cases⁹.

In 2021, a case was recorded by El Backly, which presented gemination in an upper central incisor tooth. When performing a cone-beam computed tomography (CBCT) study, separate pulp chambers and roots were shown, so the diagnosis implies a fusion to a supernumerary tooth. The treatment that was carried out was based on a root canal treatment on the upper central incisor tooth and extraction through a surgical odontosection of the fused supernumerary. After healing, orthodontic treatment was performed to improve aesthetics, both dental and facial, resolving functional details of occlusion¹¹.

The cases of Bargale and Kim presented a gemination or fusion in the anterior sector, so the aesthetics of the patient was compromised. Due to the conditions of both cases during the diagnosis, the need for a surgical approach for an odontosection and extraction of the dental surplus was raised. A similar procedure was

performed by El Backly, however, due to the communication of the pulp chamber, a root canal treatment was performed prior to the surgical procedure for the odontosection^{11, 15, 16, 17}.

The approach of the present clinical case was treated in a more conservative way than previous studies, opting for the second option proposed by the author Finkelstein, coupled with root canal treatment to avoid irreversible pulpitis at the time of performing interproximal reduction, thus avoiding forms the odontosection as in the cases presented by El Backly, Bargale and Kim. A prosthetic or restorative treatment is also suggested on the tooth with gemination, both to improve the aesthetics of the lower left lateral incisor tooth with dental gemination, and to cover the exposure of dentin tissue and reduce the propensity for the development of future carious lesions^{11, 16, 17}.

V. Conclusion

Dental gemination is one of the least frequent anomalies in daily practice and consequently there are few registered cases treated with orthodontics; despite this, the orthodontist must be able to identify the anomaly, know the options to solve the problems that may arise and plan an effective treatment. The manifestations of double teeth can be detrimental to occlusion, but for patients it has a negative aesthetic effect, mainly when it affects the anterior segment, which motivates the patient to seek orthodontic treatment.

Through orthodontic treatment in conjunction with root canal treatment and its final restoration, an appropriate occlusal, functional and aesthetic stability is obtained for patients with this type of anomaly.

References

- [1]. Baron C, Houchmand-Cuny M, Enkel B, Lopez-Cazaux S. Prevalence of dental anomalies in French orthodontic patients: A retrospective study. Arch Pédiatrie [Internet]. octubre de 2018;25(7):426–30. Disponible en: <https://doi.org/10.1016/j.arcped.2018.07.002>
- [2]. Alotaibi SF, Almufleh R, Alshamrani H, Salama F. Bilateral Fusion of Primary Mandibular Lateral Incisors and Canines: A Case Report. J Clin DIAGNOSTIC Res [Internet]. 2020;10–3. Disponible en: https://jcdcr.net/article_fulltext.asp?issn=0973-709x&year=2020&volume=14&issue=1&page=ZD10&issn=0973-709x&id=13460
- [3]. Montasser MA, Taha M. Prevalence and distribution of dental anomalies in orthodontic patients. Orthodontics (Chic) [Internet]. 2012;13(1):52–9. Disponible en: <http://www.ncbi.nlm.nih.gov/pubmed/22567616>
- [4]. Khan SQ, Agha D, Zafar S, Ashraf b. Double tooth: report of two unique clinical cases. Pakistan Oral Dent J. 2016;36(2):259–63.
- [5]. Bolaños, V., Rojas F. Diente germinado: reporte de un caso y revisión de literatura. UCR. 2013; Vol (15):75–80.
- [6]. Finkelstein T, Shapira Y, Bechor N, Shpack N. Fused and Geminated Permanent Maxillary Central Incisors: Prevalence, Treatment Options, and Outcome in Orthodontic Patients. J Dent Child (Chic) [Internet]. 2015;82(3):147–52. Disponible en: <http://www.ncbi.nlm.nih.gov/pubmed/26731250>
- [7]. Akay g, Ispir ng, Haroğlu d, Güngör k, Alkurt mt. Frequency and Distribution of Fusion and Gemination in Permanent Dentition: Clinical and Radiological Study. Türkiye Klin J Dent Sci [Internet]. 2020;26(3):348–53. Disponible en: <https://www.turkiyeklinikleri.com/article/en-frequency-and-distribution-of-fusion-and-gemination-in-permanent-dentition-clinical-and-radiological-study-86754.html>
- [8]. Dwijendra KS, Parikh V, George SS, Kukunuru GT, Chowdary GN. Association of Dental Anomalies with Different Types of Malocclusions in Pretreatment Orthodontic Patients. J Int oral Heal JIOH [Internet]. 2015;7(6):61–4. Disponible en: <http://www.ncbi.nlm.nih.gov/pubmed/26124602> <http://www.pubmedcentral.nih.gov/articlerender.fcgi?artid=PMC4479776>
- [9]. Sharma S, Singh N, Bharti A, Bharat N, Jumar S, Kumar, D. Gemination of mandibular central incisor: A rare case report. IJERMDC. 2015; 2(2): 7-9.
- [10]. Mazaheri H, Mosharraf R. Unilateral gemination of a maxillary first premolar: a case report. Int J Dent Clin. 2015;7(1):43–4.
- [11]. El Backly RM, Kotry GS, Moussa H. Multidisciplinary management of a fused maxillary incisor: Case report with 5-year follow-up. Clin Case Reports. 2021;9(2):775–86.
- [12]. Yuzawa m, Akimoto y, Omata h, Nakamura t, Kaneko k, Yamamoto h. Fusion of a maxillary central incisor with a supernumerary tooth. J Nihon Univ Sch Dent [Internet]. 1985;27(4):252–4. Disponible en: <http://joi.jlc.jst.go.jp/JST.Journalarchive/josnusd1959/27.252?from=CrossRef>
- [13]. Oliveira, T, Prado D, Ferreira A, Dominguez G. Treatment of concomitant geminated and fused maxillary central incisors: A 5-year follow-up. Elsevier. 2019; Vol (324)169-178.
- [14]. Soin A, Sharma G, Soin G, Raina A, Mutneja P, Nagpal A. Multiple Geminated Supernumerary Premolars: A Rare Case Report. Case Rep Dent [Internet]. 2015; 2015:1–4. Disponible en: <http://www.hindawi.com/journals/crid/2015/726458/>
- [15]. Bargale S, Kiran S, BVR A, Sikligar S. Integrated Surgical and Orthodontic Treatment: A Twinned Teeth Dilemma. Adv Hum Biol. 2015;5(1):43–7.
- [16]. Kim EC, Symington O, Kulkarni G. Conservative Management of Fused and Geminated Permanent Anterior Teeth. J Dent Child (Chic) [Internet]. el 15 de septiembre de 2019;86(3):164–8. Disponible en: <http://www.ncbi.nlm.nih.gov/pubmed/31645259>
- [17]. Stanford ND, Hosni S, Morris T. Orthodontic management of a dental concrescence: a case report. J Orthod [Internet]. el 3 de julio de 2017;44(3):209–15. Disponible en: <https://www.tandfonline.com/doi/full/10.1080/14653125.2017.1357877>
- [18]. Pereira RP, Ravazzi R, Vieira Silva R, Nunes E, Rocha Gusmão JM, Flores Campos PS. Multidisciplinary Treatment of a Double First Mandibular Premolar. Iran Endod J [Internet]. 2017;12(4):512–5. Disponible en: <http://www.ncbi.nlm.nih.gov/pubmed/29225651>
- [19]. Jiménez M, Montero P, Saúco J, Segura J. Geminación y fusión: un desafío en la práctica clínica. Universidad de Sevilla. 2016;34(3):9-20.
- [20]. Le Gall, M., Philip, C., Aboudharam, G. Orthodontic treatment of bilateral geminated maxillary permanent incisors. Am J Orthod Dentofacial Orthop. 2011;139(5): 698–703.