

## Age And Gender Related Changes On Cerebellum Volume And Vermeil Area: MRI Based Study

Hiba Osman Mohmmed Sied Ahmed<sup>1</sup>, Caroline Edward Ayad<sup>1</sup>,

<sup>1</sup>Sudan University of Science and Technology-Khartoum-Sudan

Corresponding Author: Hiba Osman Mohmmed Sied Ahmed

**Abstract :** The cerebellum is one of important structure that found in posterior cranial fossa. The current study focused on the impact of age and gender on cerebellum volume and vermeil area in Sudanese population 100 healthy Sudanese subjects were included, their age ranged between 14 – 80 years old, 41% of them were males and 59 % were females . All were scanned using Magnetic Resonance Imaging (MRI) after applying the standard cerebellum protocol.

The study showed : the mean cerebellum volume was  $190.6 \pm 21.57 \text{ cm}^3$  with the maximum value was  $193.2 \text{ cm}^3 \pm 24.8$  and was found in the ages between (14-30) years old .The minimum value was  $186.5 \text{ cm}^3 \pm 19.58$  and was found in the ages between (47-63) years old . There is no significant relation between cerebellum volume and age where a significant relation was found with gender and at  $p=0.000$

The vermian minimum area was  $108.6 \pm 13.93 \text{ cm}^2$  in the ages between (31 – 46) years old and the maximum value was  $121.5 \text{ cm}^2 \pm 17.14$  in the ages between (64 - 80) years old .The area is greater in males than females with no significant relation found between vermian area , age and gender.

**Keywords:** Cerebellum, Vermian area, Volumetric studies, MRI

Date of Submission: 14-11-2018

Date of acceptance: 29-11-2018

### I. Introduction

The cerebellum is one of the important structures in the cranial fossa which occupies the posterior part. It contains more than 50% of all neurons in the brain. It is organized in manner than the cerebrum [1] Recently, researches have emphasized the role the cerebellum is likely to play in cognitive processing, next to its well-studied contributions to motor skills [2,3] It is therefore important to study determinants of cerebellar volume in a population. Most structural magnetic resonance (MR) imaging studied only the entire brain [4]. Studies that specifically assessed the cerebellum showed inconsistent results but other one reported that cerebellar volume remains relatively stable with aging [5,6] .Whereas others found strong effects regarding the impact of age on cerebellar atrophy [7,8]. A histological study of the cerebellum showed that smaller weight and volume were found, and fewer neurons were counted in the cerebellum of older persons than in those of younger persons [9]. Sex differences in gross cerebellar neuroanatomy have been reported in several studies [10-11]. Moderate shrinkage of the cerebellar hemispheres and the vermis has been noted in post-mortem studies [15, 16] and in some in vivo investigations [10-11, 12-13]. However, other volumetric studies based on MR imaging yielded no effects of age on the size of the cerebellum [14, 15] or showed non-significant trends [13]. Hayakawa et al. [16] found no significant difference in the midsagittal area of either the pons or cerebellar vermis between the 21-40 and 51-60 age groups.

The awareness of normal neuroanatomic variability is important for understanding any pathologic change . MRI studies have correlated midbrain morphology with symptomatology in several disorders, including Parkinson disease [17] and Wilson disease [18], suggesting that morphometric data may indirectly reflect underlying neurochemical or pathologic process. Coffman et al. [19] found no differences between schizophrenics and controls, whereas Nasrallah et al. [20] reported that schizophrenics have larger cerebellar structures than controls. However, a number of MRI studies could not confirm the vermal atrophy in schizophrenic patients [21-22].

The data on age-related changes of the cerebellar vermis in normal subjects will facilitate further investigation of the relation between cerebellar vermis changes and the neuromotor decline with normal aging and in different gender

Establishing normative data can be used to compare the findings in patients with neurologic disorders ,as well ,this study may support the findings of morphometrical sex differences and age-related changes as there are discrepancies in the results concerning the age-related changes in the cerebellar vermis remains speculative, though some authors suggest a selective vulnerability of specific posterior fossa structures to the effects of aging

and sex. The Questions to be answered :what is the impact of age and gender on the cerebellum volume and vermeil area of the Sudanese subjects

## II. Materials And Methods

### 2.1 Area, Duration and Sample:

This is descriptive analytical study .It was performed in Khartoum state, Yastabshiroon Hospital – Radiology Department, MRI section. The study was obtained during the period extended from 2014-2017. The study was performed on 100 patients .41 were males and 59were females with different ages at range (14-80)years ,mean age was  $42.36 \pm 17.87$  years old (Min=14.00 , Max=80.00years). The ages between 14-30 years constituting 27 cases, ages between 31-46 were 29 subjects, and ages between 47-63 years were 28, while 64-80 years old were 16, .All patients have undergone MRI brain exam complaining of headache, and their final diagnoses is normal. Any patient has problem to perform MRI brain such as patients with metallic foreign body in brain or brain clips or abnormalities at any part of cerebellum or cerebrum were excluded

### 2.2 MRI machine.

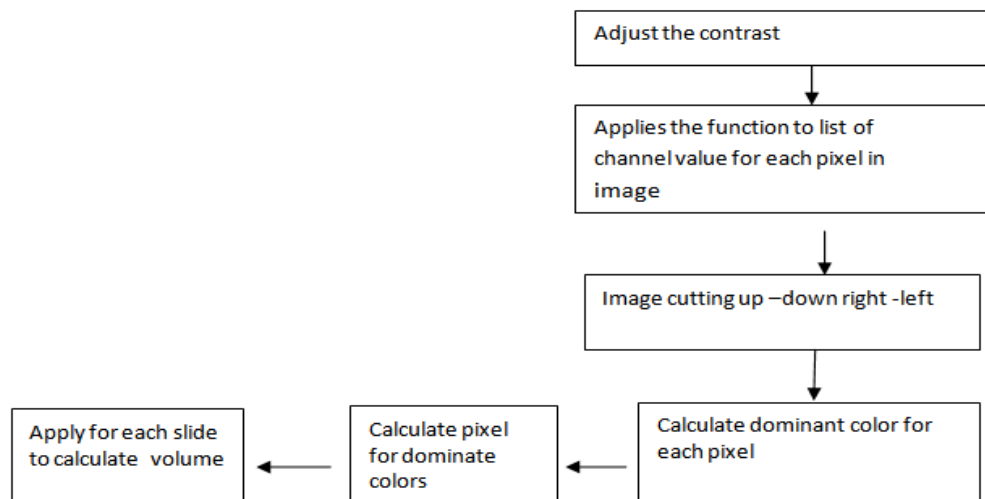
This machine is open machine and manufactured in America in 2005 and assembly in China, GE exit 0.2 Tesla .The RF Range in examination from (512-192) MHZ .The slice thickness used in MRI brain was 5mm. The matrix was 256x256. Field of view was medium.

### 2.3 The scanning technique used and protocols:

Three planes were taken: axial (T1, T2, T1 flair), sagittal T1 and coronal T2 section as routine .The measurements were done in: axial T2 FSE. Firstly: patients were prepared to enter the MRI room by removing any metallic substance outside his /her body. In the cases where anesthesia is needed, it was applied. The sequence of the exam was explained clearly for all of the patients. Secondly: the head coil was applied, then the foam pads and ear plugs to ensure the immobilization and comfortable of patients. Two control lines were applied; one is axial and the another is sagittal , the first coronal and sagittal crosses the nasion area ,the second coronal pass just at the external orbital line level , then the scan start from vertex till the base of skull.

### 2.4 Method of measuring the volume.

In this measurement, an advanced soft ware program (Wolfram Mathematica)[ 23 ] was used for image analysis , interpretation and application .applying the following steps:



### 2.5 Ethical concerns:

Verbal consent was firstly obtained from all potential participants. The aims, benefits of the present study were explained to all participants in details. Medical, history of all study subjects posing as (sample) were thoroughly reviewed directly from participants themselves and those with conditions that may in any way, alter the findings of the current study were excluded.

**III. Results**

**Table No (1):** Age class, frequency and percentage

| Age Classification | Frequency | Percentage |
|--------------------|-----------|------------|
| 14 -30 year        | 27        | 27%        |
| 31 - 46 year       | 29        | 29%        |
| 47 - 63 year       | 28        | 28%        |
| 64 - 80 year       | 16        | 16%        |
| Total              | 100       | 100%       |

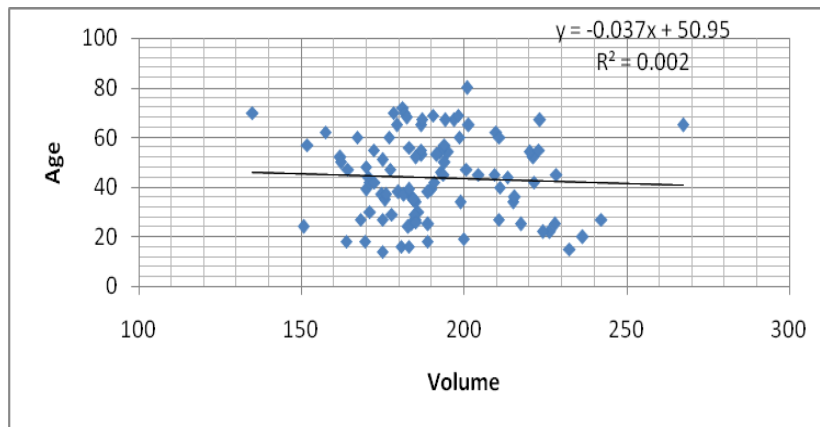
**Table No (2):** Gender ,Frequency and Percentage

| Gender | Frequency | Percentage |
|--------|-----------|------------|
| Male   | 41        | 41%        |
| Female | 59        | 59%        |
| Total  | 100       | 100%       |

**Table No (3):** Age class, Mean Cerebellum volume and P-value

| Age Classes  | Mean cerebellum volume ±STDV | P- Value |
|--------------|------------------------------|----------|
| 14-30 year   | 193.2±24.81                  | 0.672    |
| 31 - 46 year | 190.9±17.03                  |          |
| 47 - 63 year | 186.5±19.58                  |          |
| 64 - 80 year | 192.8±26.88                  |          |

\*\* Significant at 0.01 Level



**Figure(1):** show the relation between age and cerebellum volume

**Table No (4):** the mean cerebellum volume for both genders and p=value

| Gender | Mean(SD)    | P- Value |
|--------|-------------|----------|
| Female | 184.1±19.22 | 0.000**  |
| Male   | 199.9±21.57 |          |

\*\* Significant at 0.01 Level

**Table No (5):** Age class, mean Vermis area and p- value

| Age Class    | Mean Vermis area ±STDV | P- Value |
|--------------|------------------------|----------|
| 14-30 year   | 112.8±18.95            | 0.203    |
| 31 - 46 year | 108.6±13.93            |          |
| 47 - 63 year | 112.2±24.61            |          |
| 64 - 80 year | 121.5±17.14            |          |

\*\* Significant at 0.01 Level

**Table No (6):** the mean Vermis area for both genders and p=value

| Gender | Mean Vermis area ±STDV | P- Value |
|--------|------------------------|----------|
| Female | 111.1±19.73            | 0.281    |
| Male   | 115.4±18.88            |          |

\*\* Significant at 0.01 Level

#### IV. Discussion

The current study highlighted the knowledge regarding the norms of Sudanese cerebellum volume and vermian area. The frequency and percentage of the age and gender were presented in **tables (1,2)**

The results showed that the volume recording high value on the age group (14-30) years old with mean  $193.2 \text{ cm}^3 \pm 24.81$  and then the volume declined with increasing age then started to increase in the age (64-80) years old however this changes were not significantly correlated with age at P-value .672

this was presented in table (3) and figure(1) that showed that the volume decline by constant value as 0.037 when the age increased starting from 50.95 years old. Previous study justified that the histological findings of the aging cerebellum shows general atrophy, as the age-related loss of Purkinje cells is uniformly distributed across the vermian lobules and the cerebellar hemispheres [24].

Another study has mentioned that the topography of the cerebellum blood supply may influence the cerebellum to differential aging. The cerebellar hemispheres are supplied by the branches of the posterior inferior cerebellar artery which originates in the vertebral artery, whereas the blood supply for the age-invariant superior vermis comes from the superior cerebellar artery, which branches of the basilar artery. [29,30] The vertebral system receives a small volume of blood in the age-related vertebral insufficiency [31], the cerebellar structures that are the most remote from the source may be at the greatest risk. This may be one of the causes of changes that observed in the cerebellum readings volume. On the other hand, one study mentioned that in contrast, the cerebellum shows no significant age related declines in blood flow, oxygen consumption, and glucose metabolism [16, 27] and another found no relationship between posterior fossa structures and aging [32,33] Others were reported a significant-associated shrinkage of the cerebellar volume in men after the age of 70 years [34]. Shah et al. [31] reported that the dimension of the posterior cerebellar vermis does not significantly change with age. Another reported higher subjective rating of vermian atrophy by age and the trend towards atrophy is probably related to loss of Purkinje cells in the vermis [24].

**Table (3)** showed the relation between the volume and gender which positive propagation in males than females : mean  $199.9 \text{ cm}^3 \pm 21.57$  but for female recorded mean volume equal  $184.1 \text{ cm}^3 \pm 19.22$  the difference between the two genders is significant at p-value.000. Some researchers speculated that sexual dimorphism in cerebellar size can be attributed to the effects of sex hormones [13, 14]. Escalona et al. [9] observed that women have a significantly smaller cerebellar volume than men, but indicated no aging effect on cerebellar volume in either gender. Another study justifies the reduction of cerebellum volume in females rather than males due to reduction of white matter volume in women more than men [34]. **Table (4)** showed the mean cerebellum volume for both genders with significant difference at  $p=0.000$ . **Table (5)** showed the vermian area, in the young ages; the vermian mean area was  $112.8 \pm 18.95 \text{ cm}^2$  in the age range (14 - 30) years old but started to decrease when the age increases. The maximum reading in adult was  $121.5 \text{ cm}^2 \pm 17.14$  in the ages between (64 - 80) years old.

**Table (6)** showed the classification of vermian area according to gender. The area increases in males rather than females with mean  $115.4 \text{ cm}^2 \pm 18.88$ . The females recorded mean value equal to  $111.1 \pm 19.73$ , many studies have justified that issue. [25, 26, 27, 28]. Others were reported a significant-associated shrinkage of the cerebellar vermis in men after the age of 70 years [34]. Shah et al. [32] reported that the dimension of the posterior cerebellar vermis does not significantly change with age. Although, our results showed non-significant-associated decrease in the cerebellar vermis with age. This result is in agreement with a previous studies [9-22]. Luft et al. [10] suggested that women might show steeper age-related decline in the area of the vermis than do the males.

#### V. Conclusion

Norms of Sudanese Cerebellum volume and vermian area were established. There are increasing of cerebellum volume in young ages and then the volume decreased with increasing age. The cerebellum volume is larger in males than females. The cerebellum vermian area increase in young ages and started to shrink with increasing age then return to increase in elderly subjects.

#### Acknowledgements

We sincerely thank the participants without whom the study would not have been feasible. The Sudan University of Science and Technology, College of Medical Radiological Science and Yastabshroon Hospital - Radiology Department –in which the study was obtained

#### References

- [1]. Kandel, E.R., Schwartz, J.H., Jessell, T.M., 2000. Principles of Neural Science, fourth ed. New York, McGraw-Hill ISBN 0-8385-7701-6.
- [2]. Schmahmann, J.D., 2010. The role of the cerebellum in cognition and emotion: personal reflections since 1982 on the dysmetria of thought hypothesis, and its historical evolution from theory to therapy. *Neuropsychol.Rev.* 20, 236–260

- [3]. Stoodley, C.J., 2011. The cerebellum and cognition: evidence from functional imaging studies. *Cerebellum*. DOI: 10.1007/s12311-011-0260-7.
- [4]. Ikrām, M.A., Vrooman, H.A., Vernooij, M.W., van der Lijn, F., Hofman, A., van der Lugt, A., Niessen, W.J., Breteler, M.M., 2008. Brain tissue volumes in the general elderly population. The Rotterdam Scan Study. *Neurobiol. Aging* 29, 882–890.
- [5]. Bergfield, K.L., Hanson, K.D., Chen, K., Teipel, S.J., Hampel, H., Rapoport, S.I., Moeller, J.R., Alexander, G.E., 2010. Age-related networks of regional covariance in MRI gray matter: reproducible multivariate patterns in healthy aging. *NeuroImage* 49, 1750–1759
- [6]. Rhyu, I.J., Cho, T.H., Lee, N.J., Uhm, C.S., Kim, H., Suh, Y.S., 1999. Magnetic resonance image-based cerebellar volumetry in healthy Korean adults. *Neurosci. Lett.* 270, 149–152.
- [7]. Pagani, E., Agosta, F., Rocca, M.A., Caputo, D., Filippi, M., 2008. Voxel based analysis derived from fractional anisotropy images of white matter volume changes with aging. *Neuroimage* 41, 657–667.
- [8]. Raz, N., Gunning-Dixon, F., Head, D., Williamson, A., Acker, J.D., 2001. Age and sex differences in the cerebellum and the ventral pons: a prospective MR study of healthy adults. *AJNR Am. J. Neuroradiol.* 22,1161–1167.
- [9]. Escalona PR, McDonald WM, Doraiswamy PM, Boyko OB, Husain MM, Figiel GS, Laskowitz D, Ellinwood EH Jr, Krishnan KR. In vivo stereological assessment of human cerebellar volume: effects of gender and age. *Am. J. Neuroradiol.* 1991 (12) 927-929
- [10]. Luft AR, Skalej M, Schultz JB, Welte D, Kolb R, Bürk K, Klockgether T, Voigt K. Patterns of age-related shrinkage in the cerebellum and brainstem observed in vivo using three-dimensional MRI volumetry. *Cereb. Cortex.* 1999 (9) 712-721.
- [11]. Raz N, Dupuis JH, Briggs SD, McGavran C, Acker JD. Differential effects of age and sex on the cerebellar hemispheres and the vermis: a prospective MR study. *Am. J. Neuroradiol.* 1998 (19) 65-71.
- [12]. Raz N. Aging of the brain and its impact on cognitive performance: integration of structural and functional findings. In: Craik FIM, Salthouse TA, eds. *Handbook of Aging and Cognition II*. Mahwah, NJ: Erlbaum; 2000; pp 1-90.
- [13]. Luft AR, Skalej M, Wette D, Voigt K, Klockgether T. Age and sex do not affect cerebellar volume in humans. *Am. J. Neuroradiol.* 1997 (18) 593-596.
- [14]. Rhyu IJ, Cho TH, Lee NJ, Uhm CS, Kim H, Suh YS. Magnetic resonance image-based cerebellar volumetry in healthy Korean adults. *Neurosci. Lett.* 1999 (270) 149-152.
- [15]. Salat D, Ward A, Kaye JA, Janowsky JS. Sex differences in the corpus callosum with aging. *Neurobiol. Aging.* 1997 (18) 191-197
- [16]. Hayakawa K, Konishi Y, Matsuda T, Kuriyama M, Konishi K, Yamashita K, Okumura R, Hamanaka D. Development and aging of brain midline structures: assesment with MR imaging. *Radiology.* 1989 (172) 171-177.
- [17]. Huber SJ, Chakeres DW, Paulson GW, Khanna R. Magnetic resonance imaging in Parkinson's disease. *Arch. Neurol.* 1990 (47) 735-737.
- [18]. [ Grimm G, Prayer L, Older W. Comparison of functional and structural brain disturbances in Wilson's disease. *Neurology.* 1991 (41) 272-276.
- [19]. Coffmann JA, Schwarzkopf SB, Olson SC, Nasrallah HA. Midsagittal cerebral anatomy by magnetic resonance imaging. The importance of slice position and thickness. *Schizophr. Res.* 1989 (2) 287-294.
- [20]. Nasrallah UM, Schwarzkopf SB, Olson SC, Coffman JA. Perinatal brain injury and cerebral vermal lobules I-X in schizophrenia. *Biol. Psychiatry.* 1991 (29) 567-274.
- [21]. Mathew RJ, Partain CL. Midsagittal sections of the cerebellar vermis and fourth ventricle obtained with magnetic resonance imaging of schizophrenic patients. *Am. J. Psychiatry.* 1985 (142) 970-971.
- [22]. Aylward E, Reiss A, Barta PE, Tien A, Han W, Lee J, Pearlson GD. Magnetic resonance imaging measurement of posterior fossa structures in schizophrenia. *Am. J. Psychiatry.* 1994 (151) 1448-1452.
- [23]. [Santanu K. Maiti ,A Basic Introduction on Math-Link in Mathematica, Theoretical Condensed Matter Physics Division Saha Institute of Nuclear Physics 1/AF, Bidhannagar, Kolkata-700 064, India].
- [24]. Ellis RS. (1920)Norms for some structural changes in human cerebellum from birth to old age. *J Comp Neurol*;32:1–33
- [25]. Naftali Raz, James H. Dupuis, Susan D. Briggs, Catherine McGavran, and James D. Acker (1998).Differential Effects of Age and Sex on the Cerebellar Hemispheres and the Vermis:A Prospective MR Study *AJNR Am J Neuroradiol* 19:65–71
- [26]. Courchesne E. (1987)A neurophysiological view of autism. In: Schopler E, Mesibov G, eds. *Neurobiological Issues in Autism*. New York, NY:Plenum;;285–384
- [27]. Raz N, Torres IJ, Briggs SD, et al. (1995)Selective neuroanatomical abnormalities in Down's syndrome and their cognitive correlates:evidence from MRI morphometry. *Neurology*;45:356–366
- [28]. Cieselski KT, Yanofsky R, Ludwig RN, et al. (1994)Hypoplasia of the cerebellar vermis and cognitive deficits in survivors of childhood leukemia. *Arch Neurol*;51:985–993
- [29]. Lister JR, Rhoton AL Jr, Matsushima T, Peace DA. (1982)Microsurgical anatomy of the posterior inferior cerebellar artery. *Neurosurgery*;10:170–199
- [30]. Hardy DG, Peace DA, Rhoton AL Jr. (1980) Microsurgical anatomy of the superior cerebellar artery. *Neurosurgery*;6:10–28
- [31]. Baloh RW. (1984)Neurotology of aging: vestibular system. In: Albert ML, ed. *Clinical Neurology of Aging*. New York, NY:Oxford University Press;;345–361
- [32]. Shah SA, Doraiswamy PM, Husain MM, Figiel GS, Boyko OB, McDonald WM, Ellinwood EH, Krishnan RR. Assessment of posterior fossa structures with midsagittal MRI: the effects of age. *Neurobiol. Aging.* 1991 (12) 371-374.
- [33]. Koller W, Glatt S, Fox J, Kaszniak AW, Wilson RS, Huckman MS. Cerebellar atrophy: relationship to aging and cerebral atrophy. *Neurology.* 1981 (31) 1486-1488.
- [34]. Oguro H, Okada K, Yamaguchi S, Kobayashi S. Sex differences in morphology of the brain stem and cerebellum with normal ageing. *Neuroradiology.* 1998 (40) 788-792.
- [35]. Andersen, B.B., Gundersen, H.J., Pakkenberg, B., 2003. Aging of the human cerebellum: a stereological study. *J. Comp. Neurol.* 466, 356–365.

Hiba Osman Mohmmad Sied Ahmed "Age And Gender Related Changes On Cerebellum Volume And Vermeil Area : MRI Based Study "IOSR Journal of Dental and Medical Sciences (IOSR-JDMS), vol. 17, no. 11, 2018, pp 16-20.