

Emergency Spinal Anesthesia in Prone Position: Case Report

Dr. Harish Kumar¹, Dr.Ladhu Lakra², Dr.Rajesh Chandra³,
Dr. Sumit Kumar Singh⁴

^{1,3,4}Junior Resident, Deptt. Of anesthesiology, RIMS, Ranchi

²Associate Professor, Deptt. Of anesthesiology, RIMS, Ranchi

I. Introduction

- Induction of spinal anaesthesia in a patient in the prone position is rarely performed today. As late as the 1960's the technique was applied for the induction of spinal anaesthesia for upper laparotomies, and a recent publication describes the technique for anorectal surgery (1).
- For procedures performed in the prone position, such as perirectal or lower lumbar disc surgery (1-3), as well as for radiological procedures (4), spinal anesthesia is administered frequently in lateral decubitus or sitting position.
- The following case report describes the administration of spinal anaesthesia in the prone position to a patient, with surgery ensuing in the same position.

II. Case Report

- An 18-year-old man presented in emergency surgery because of a traumatic thigh fracture with an **ironrod impacted in hip bone** passing medially and adjacent to femur on left side following road traffic accident. He was without medication.

Pac

General examination

- G.C-Good
- Co-operative and following verbal commands
- On examination, There was no evidence of injury to the head, spine, thorax. He was well hydrated. He had been fasting for one and half hours. When patient was shifted to the operating theatre he had positioned himself face-down on the table, as this was the only position where he was able to position himself and experienced only moderate pain.
- Pulse-97/min
- BP-130/80 mmhg
- Temperature-normal
- CVS-s1 s2 normal, no murmur
- RS-Air entry b/lequal, no added sound
- CNS-conscious, oriented
- no neurological deficit
- pupil b/lnsr
- plantar:b/l flexor

Local Examination

- A fracture hematoma was present in the thigh with an iron rod impacted in hip passing medially towards thigh.
- An x-ray of the thigh revealed a proximal femoral fracture with an overlap of fracture ends, with an **ironrod impacted in hip bone** passing medially and adjacent to femur on left side

Investigations

Investigations were advised

- Complete blood count including haemoglobin
- Sr. electrolyte
- Blood grouping and cross matching
- USG(FAST)
- Chest xray PA view
- CT scan

Advice

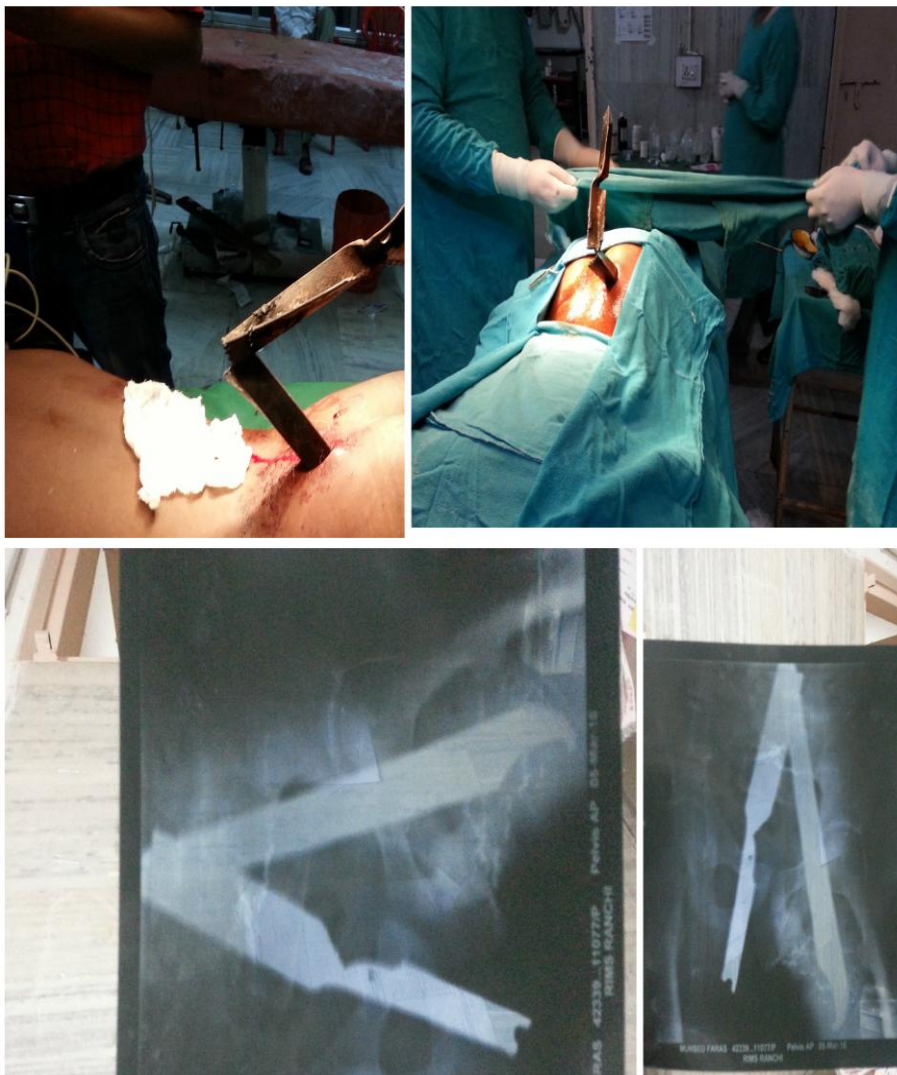- It was therefore decided to perform spinal anaesthesia in prone position. The patient's hips were lifted from the table so that three stacked pillows could be inserted under his thorax,abdomen and lower limb without discomfort. This resulted in a slightly relaxed position of the lumbar spine.

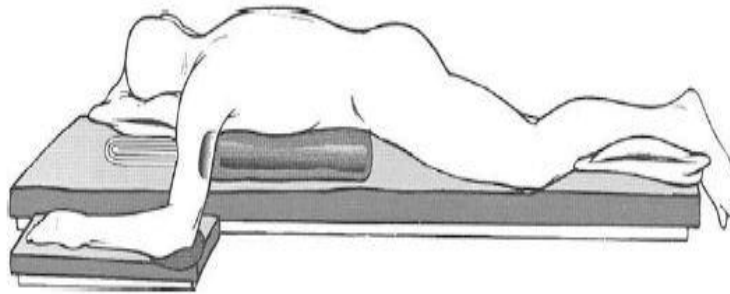
Pre-Op Preparation

- Two large-bore venous cannulae were placed, and infusion of 1000 ml Ringer's lactate was commenced. The position and shape of rod prevented any manoeuvre for supine positioning of patient. The prone position prevented the anaesthesiologist from obtaining adequate airway control for a rapid intubation sequence.
- Drugs: Inj. Glycopyrrolate 0.2mg
Inj.ranitidine 50mg
Inj.midazolam 1mg

Anesthesia

- Following commencement of a colloid solution (Haemacelinfusion),after proper dressing and draping and full aseptic precaution a 26-gauge quincke’s spinal needle was inserted in the L2-3 interspace with continuous aspiration using 3ml syringe. Clear cerebro-spinal fluid refluxed, and 4.0 ml of hyperbaric bupivacaine 0.5% was injected. Additionally, mephentermine 10mg i.v was given prophylactically against hypotension.
- The ensuing spinal anaesthesia had a maximum cephalad spread to the Th 10 dermatome, as estimated by thermalgesia, after 16 min. Surgery and recovery were uneventful.





III. Discussion

- The successful management of this case was initially regarded as requiring full control of the upper airways. Even after a significant amount of opioids and other manoeuvres, the necessary supine position could not be attained due to strong patient discomfort and positioning of impacted rod. Additional doses of opioid may have caused respiratory depression.
- Emergency spinal anesthesia in prone position and controlled ventilation of the patient in the prone position would have been very difficult to perform. It may have been possible to turn the patient into the supine position using ketamine analgesia with benzodiazepine sedation; however, this may also have caused respiratory depression. Another possible alternative may have been to conduct a femoral nerve block. This would greatly have facilitated x-ray, transport and change in position. Conducting the nerve block is, however, not possible in the prone position, but may have been considered upon admission, or preferably at the scene of injury. This is, however, not the issue, but the fact that he was successfully managed using a non-routine procedure for inducing spinal anaesthesia.
- Successful induction of spinal anaesthesia in a patient in the prone position requires a certain flexion of the lumbar spine by either; i) positioning the patient in the jack-knifed, prone position on a convex operating table or, ii) placing a pillow under the patient's hips. The downward inclination of the torso resulting from a jack-knife position excludes the use of a hyperbaric injectate solution, as it would result in uncontrolled cephalad spread of the block. In the present case, hyperbaric 5 mg/ml bupivacaine solution was used, which produced a maximum cephalad sensory block to the Th 10 dermatome. Other authors have used hypobaric (1), isobaric (2, 3) or hyperbaric (4)

Solutions for surgery /procedure in the prone position, but only in one of these was the patient prone during induction of the spinal anaesthesia (1). Low dermatome levels (Th 10 to L 5), and no adverse events were reported in these studies. Circulatory changes in the prone position have been investigated in a study comparing general versus spinal anaesthesia for lumbar disc surgery in the prone (genu-pectoral) position (2). The investigations showed that heart rate and blood pressure were reduced in the prone position under general anaesthesia, but not under spinal anaesthesia.

IV. Conclusion

- spinal anesthesia can be given in prone position in emergency situation with proper preparation and practice, by taking all precautions.

References

- [1]. Maroof M, Khan RM, Siddique M, Tariq M. Hypobaric spinal anaesthesia with bupivacaine (0.1%) gives selective sensory block for ano-rectal surgery. *Can J Anaesth* 1995; 42: 691-694.
- [2]. Becq MC, Verdin M, Riegel B, Fesard P, Moinardeu V, Delehay B et al. [Hemodynamic effects of genu-pectoral position during the surgery of lumbar disc herniation: spinal anesthesia versus general anesthesia]. *Aggressologie* 1994; 34
- [3]. Riegel B, Alibert F, Becq MC, Duckert I, Krivosic-Horber R. [Lumbar disc herniation with surgical option: general versus local anaesthesia. Round table.] *Aggressologie* 1994 34
- [4]. Tolksdorf W, Rohowsky R, Eberwein S. [The effects of flunitrazepam and benzocaine on the blood gases during transluminal aortography in spinal analgesia]. *Ansthesiologie Intensivtherapie Notfallmed* 1980 15: 407-411.
- [5].