

## Management of Malunited Panfacial Fracture With Calvarium Bone Graft – A Case Report

\*Dr. Tanmoy Ghorui<sup>1</sup>, Dr. Amit Ray<sup>2</sup>

<sup>1</sup>Senior Lecturer, Department of Oral & Maxillofacial Surgery, Guru Nanak Institute Of Dental Sciences & Research, Panihati, Kolkata, West Bengal, India

<sup>2</sup>Professor & Head, Department Of Oral & Maxillofacial Surgery, Guru Nanak Institute Of Dental Sciences & Research, Panihati, Kolkata, West Bengal, India

Corresponding Author: \*Dr. Tanmoy Ghorui

---

**Abstract:** The facial region has both functional and aesthetic units. Trauma to the facial region may corrupt any of these units, causing aesthetic as well as functional difficulties. The facial region also has an important role in the upper airway tract, and it must also be evaluated after facial injuries. Violent assaults, motor vehicle accidents and sports injuries may cause panfacial fractures that affect the lower, middle and upper part of the face. Post-traumatic deformities if not treated after healing, are among the most formidable challenges faced by the surgeons, apart from the psychological impact on the patients. Proper facial projection and height must be re-established with harmonious occlusion & Symmetry. This paper deals with a case report of the useful techniques for the correction of malunited panfacial fracture that we treated in two stages; firstly the refracture & reduction of the fracture fragments and secondly correction of residual orbital floor deformity by calvarium bone grafts.

**Keywords:** calvarium, infraorbital, mandible, orbital floor, panfacial fracture, zygomatic arch

---

Date of Submission: 06 -11-2017

Date of acceptance: 14-11-2017

---

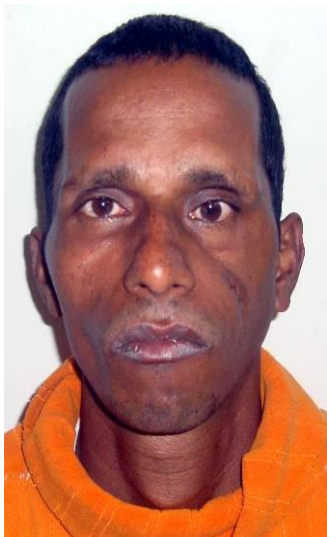### I. Introduction

Panfacial fracture is very common now a days but It is generally not treated in developing countries due to lack of infra structure. Panfacial fractures are simultaneous fractures involving cranium (upper third), mid-face and the mandible.<sup>7</sup> Panfacial fractures are those involving the mandible, maxilla, and zygomatic complex at the same time and usually accompanying naso-orbito-ethmoid (NOE) and frontal bone fractures.<sup>1,2</sup> They are often associated with soft tissue injuries and loss of bony structures that can lead to severe post traumatic deformities and disabilities like malocclusion, “dish” face deformity, enophthalmos.<sup>1,2</sup> If treatment is not carried out soon after the injury, facial bone fractures often mal-unite, soft tissues shrink and contract, and scarring occurs, all of which makes the delayed treatment very difficult.<sup>2</sup> Misdiagnosis, inadequate operation planning, lack of exposure, and insufficient bone grafting during the operation may cause secondary deformities such as flattening of the midface, ectropion, soft tissue dystopia, skeletonization of the frontal process of the zygoma, and temporal wasting. There is no clear classification for panfacial fractures in the literatures.<sup>2,3</sup> The goal of treatment, as with all facial fractures is to restore both the function and pre injury 3D facial contours. Various management schemes have been proposed including “bottom to top,” “top to bottom,” “inside-out,” or “outside-in.”<sup>2,3,4</sup> Many surgeons prefer the mandible as a foundation on which to reconstruct the occlusion first.<sup>2</sup> A mandible reconstructed properly will re-establish lower facial width and projection, and posterior facial height.<sup>2</sup> Nevertheless despite aggressive treatment some residual post traumatic deformity may persist which may warrant for second correction surgery.<sup>1</sup>

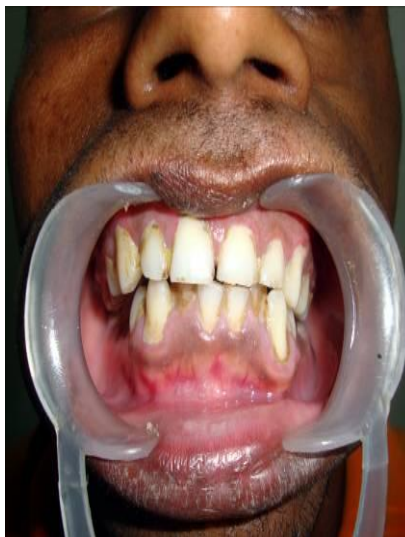### II. Case Report

A 42 year male patient reported with a chief complaint of facial asymmetry, difficulty in chewing, limited mouth opening & malocclusion for the last past 3 months. He had a history of RTA. On clinical examination (Fig.1, Fig.2), there were facial asymmetry with depressed malar prominence on the left side with scar marks, left eyeball shifted slightly downwards, no telecanthus & no hypertelorism, presence of enophthalmos, direct & consensual light reflex of both eyes were normal, no ptosis or proptosis, the competence lips, malocclusion with lingual tilting on right side and restricted mouth opening. Radiographic and 3-dimensional CT images (Fig.3) showed malunited fracture of the left zygomatic complex, incomplete Lefort I fracture and left subcondylar fracture of mandible.

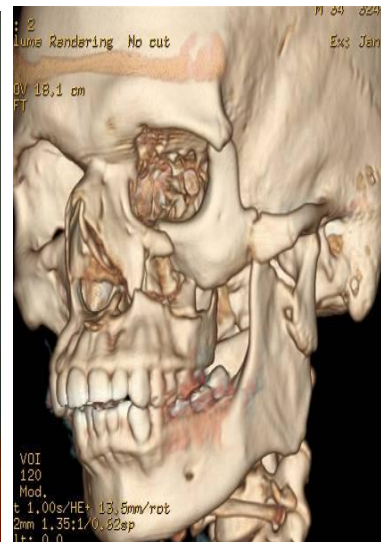
Fiber optic intubation was performed. Hemicoronal incision with preauricular extension was given (Fig.4). Incision was made through skin, subcutaneous tissue & galea, revealing the subgaleal plane of loose areolar connective tissue overlying the pericranium. With the raising of the anterior and posterior wound margins bleeding vessels were cauterized and hemostatic clips were sequentially applied. The plane of dissection strictly followed the superficial temporalis fascia downwards and forwards. The superficial layer of temporalis fascia was incised at the root of the arch, just in front of the ear, continuous anteriorly & superiorly at a 45 degree angle, joining the cross-forehead incision previously made through pericranium at the superior temporal line. Subperiosteal elevation was done which exposed the lateral surfaces of zygomatic arch, body & lateral orbital rim (Fig.5). Infraorbital rim was exposed via infraorbital skin crease incision. Incision was made through skin and orbicularis musculature. Muscle was elevated laterally from the orbital septum and a small slit was opened. Through this opening, the orbicularis muscle was undermined in the preseptal space. the muscle layer was separated from laterally to medially along the course of the muscle fibers leaving the orbital septum intact. dissection proceeded inferiorly in a preseptal suborbicular plane to reach infraorbital bony margin (Fig.5). Left subcondylar fracture area was exposed via retromandibular approach. Incision was typically 3 cm in length & parallel to the posterior border from a point just below the lobe of the ear inferior to a point just above the angle of the mandible. Exposure of the malunited subcondylar fracture area was done. After exposure, refracture of the fracture segments in the lateral orbital rim, zygomatic arch, infraorbital rim (including zygomaticomaxillary suture), & left subcondylar area were done. Mini plates were placed in the respective areas with a sequence of reduction from “top to down & outside side in” (Fig.6). Then the maxillomandibular fixation were done followed by reduction & fixation of mandibular condyle was done (Fig.6). Sutures were given in layers.



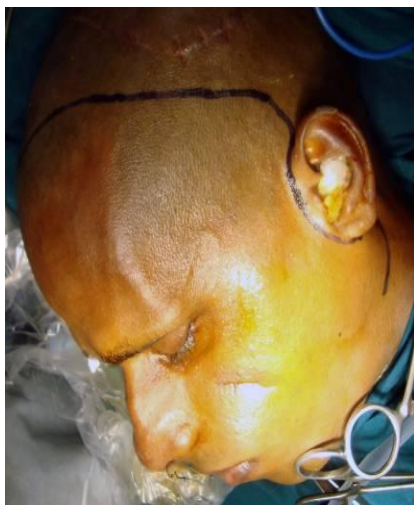**Fig.1:** Preoperative view



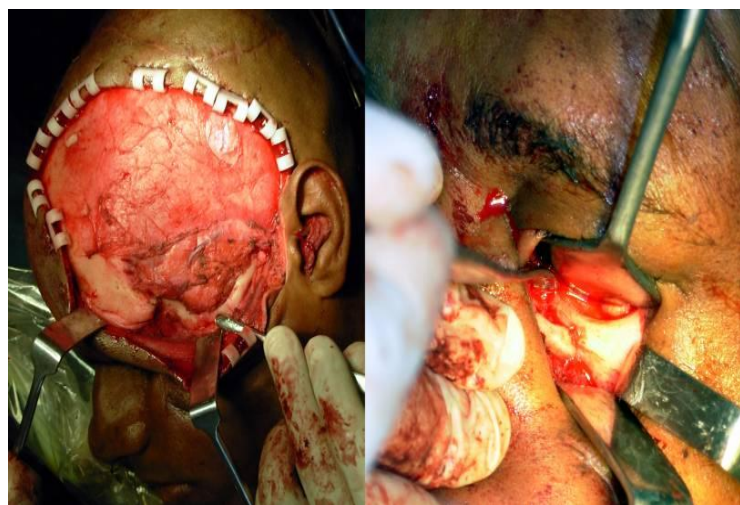
**Fig.2:** Preoperative occlusion



**Fig.3:** Preoperative 3D CT scan

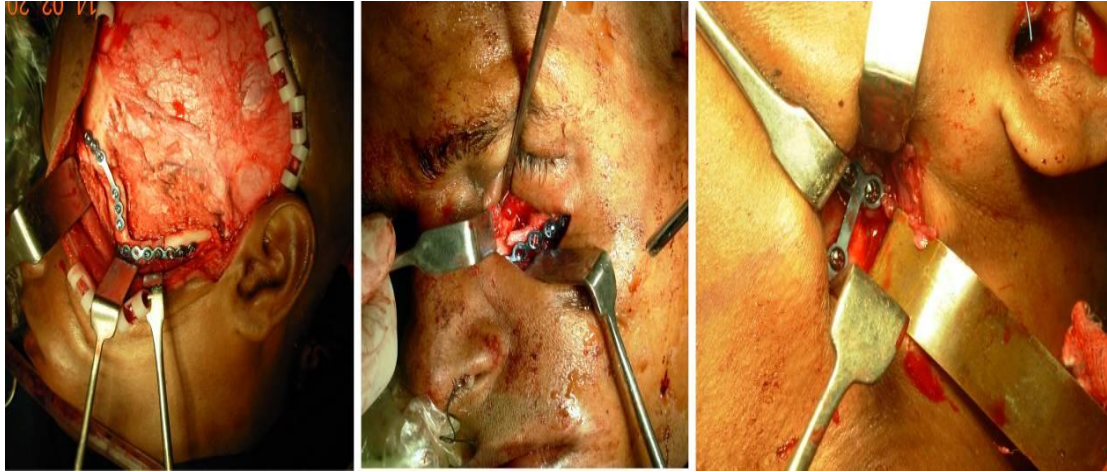

**Fig. 4:** Incision marking



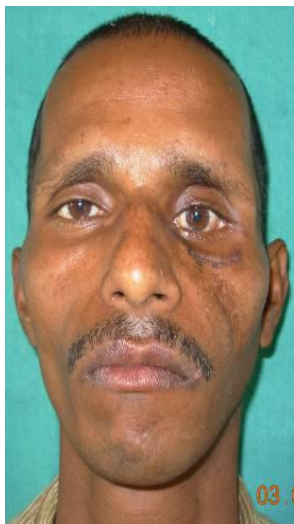**Fig.5 :** Exposure of fracture sites



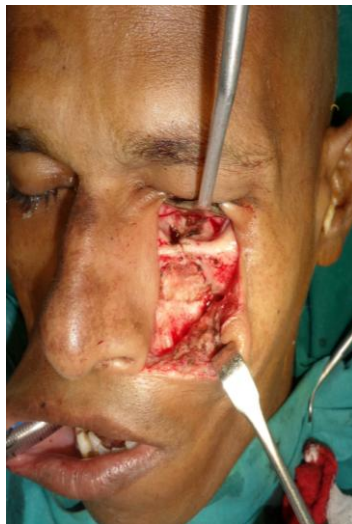

**Fig.6:** ORIF in respective areas

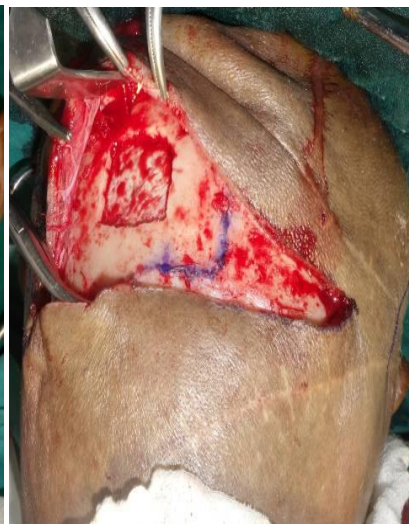After the treatment, enophthalmos, deformity of antero-lateral wall of maxilla remained (Fig.7). A second operation was planned with full thickness calvarium bone grafts under general anesthesia by oral intubation. The defect at the orbital floor & antero-lateral wall of maxilla were exposed via Weber Ferguson incision. Removal of miniplate from infra orbital rim was done (Fig.8). Calvarial bone was taken from the parietal side over the patient's nondominant hemisphere. Subperiosteal local anesthetic (lidocaine 2% Adrenaline 1: 2,00,000) was given. The cranium was exposed by a horizontal incision. The periosteum was reflected together with the galea and skin as a composite flap. The harvesting site was chosen away 2 cm from the superior sagittal suture line to prevent injury to the Superior sagittal sinus. A gutter was made down to the diploe by bar. Brisk bleeding signified that the entrance to the diploe. With a fine bar under copious irrigation with normal saline solution, strips of 3 by 3 cm were marked in situ which was the actual measurement for orbital floor reconstruction. The outer edge of the gutter was beveled to allow easy introduction of a curved osteotome with gentle tap (Fig.9). The second graft for antero-lateral wall of maxilla was harvested in same manner leaving a bridge of bone in the center of the defect to support the titanium mesh, avoiding an unpleasant depression at the donor site. A titanium mesh (1.5 mm system) was fixed with screws in the donor area (Fig.12). Scalp appositions were done with stapler. On the orbital floor the graft was secured with titanium mesh (1.5 mm system) (Fig.10, Fig.11). The antero-lateral wall of maxilla was reconstructed with other harvested calvarium graft with titanium(Ti) miniplates (Fig.11).



**Fig.7:** Residual deformity



**Fig.8:** Orbital floor exposure



**Fig.9:** Calvarium graft harvesting

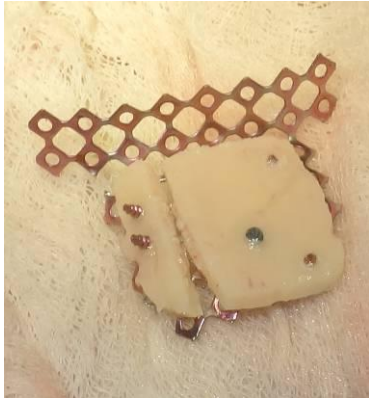


Fig.10: graft with Ti mesh

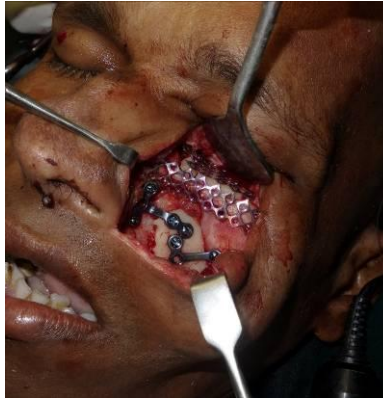

Fig.11: Placement of grafts

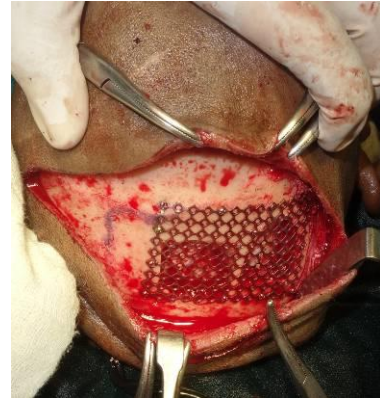

Fig.12: Ti mesh in donor area

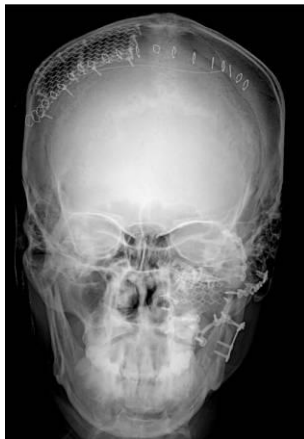

Fig.13: Post operative radiograph on next day

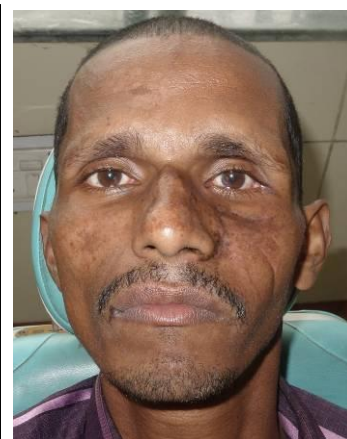
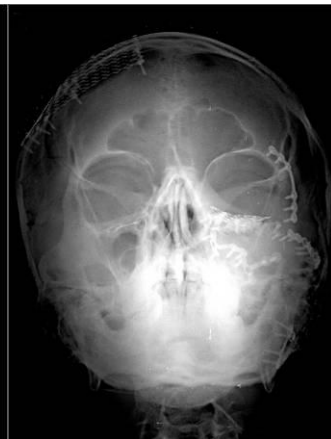
Fig.14: Post operative view

### III. Discussion

Severe craniofacial fractures vary with the vector, speed, and instrument of impact. Although general patterns of trauma have been described, each patient presents with a unique bony and soft-tissue injury.<sup>5</sup> An organized approach is therefore necessary. Proper restoration of the bony facial scaffold thus provides a stable support upon which the overlying soft tissue matrix may heal.<sup>5</sup> The management of Panfacial fracture is extremely complex, for proper sequencing of treatment there are lot of theories like “Bottom up & inside out” or “Top down & outside in”.<sup>2,3,4</sup> It is important to recognize the contributions of each component to critical dimensions of facial width, projection and height. Key contributors to central facial width are the naso-orbital-ethmoid complex, the palate, and the mandibular arch.<sup>6</sup> The frontal bar, zygomatic arches, malar eminences, and mandibular angles dictate lateral facial width. Projection, the reciprocal of width, is mediated through the frontal bar, frontonasomaxillary buttresses, zygomatic arches, and mandible from angle to symphysis. The frontal bone, midface buttresses, and mandibular angles and condyles contribute to facial height.<sup>5</sup> Gruss et al.<sup>8</sup> advised reduction of zygomatic arch and malar projection first to reestablish the “Outer facial frame” before NOE or “Inner facial frame” is reduced. Merville recommended “Top to Bottom” sequence if NOE was involved in panfacial fracture.<sup>9</sup> Tulio and Sesenna believed establishment of condyles together with mandibular arch is the appropriate first step.<sup>1,2</sup> When there are concomitant maxillary and mandibular arch fractures it is difficult to re-establish occlusion and 3D relationship of jaws. Manson and Glassman advised fixing palatal fracture first and then using the maxillary arch as a template for restoration of mandibular arch.<sup>1</sup> The fracture pattern where difficulties commonly arise are those occurring in symphysis and parasymphysis region associated with fracture of condyle(s) resulting in retrodisplacement of mandible with widening at angles. Under such conditions all fractures should be exposed prior to reduction and fixation of anyone of them. Pressure should be applied at gonial angles to close any lingual gap to establish lower facial width and achieve correct anterior projection.<sup>10</sup> The “Bottom up and inside out”<sup>11</sup> approach predates the use of rigid fixation but is still a valid approach. It establishes the mandible as foundation for setting the rest of face and includes ORIF of subcondylar fracture as well as the remainder mandible. The occlusion is set by placing the patient in maxillomandibular fixation; then the maxilla should be in proper position. Realignment of zygomatic buttress follows in this sequence; however, fixation at this point may lead to inaccuracies in upper midface position. Instead, a break in this sequence is usually preferred here. Zygomaticomaxillary Complex is reduced and fixated first. This allows for more



accurate repositioning of the upper midface before fixation at the zygomatic buttress. Maxilla is now fixated along zygomaticomaxillary buttress. Last, NOE fracture is reduced and stabilized.<sup>11</sup>

The opposite approach, top-down and outside-in, starts at the zygomatic region. The sphenozygomatic suture is reduced and fixated inside the orbit or along the lateral aspect of the orbit by reflecting temporalis muscle. The zygomatic arch is reduced and plated. If the arches are not properly reduced, underprojection of the midface can result. The NOE complex is positioned to the supraorbital rims, infraorbital rims, maxillary process of the frontal bones. Maxilla is addressed next using the position of zygomaticomaxillary buttress and piriform rim as guide. Maxillo-mandibular fixation can be established. Reduction and fixation of mandibular condyle/symphysis/ body/angle fractures are then performed.<sup>11</sup>

Neither one of these techniques will achieve optimal result in every situation, rather approach that goes from known to unknown is certainly more accurate. If there is calvarial injury sequencing should start caudally and proceed cranially to achieve optimal results. If there is remarkable comminution of mandible sequencing should start cranially to caudally. Thus maxillofacial surgeon must be comfortable with both approaches and use known landmarks to achieve optimal results.<sup>11</sup>

In the final stage of Panfacial trauma the orbital floors and nasal dorsums are reconstructed with bone grafts or alloplastic substitutes.<sup>1</sup> Regarding orbital reconstruction, calvarium has various advantages as it can be used as five different ways like full-thickness, split thickness, bone dust, bone chips & shavings. Frequently these types are used in combination. Other advantages are hidden scars, little or no postoperative pain & no obvious donor site deformity. The main disadvantage is its lack of malleability.<sup>12</sup>

#### **IV. Conclusion**

Diagnosis & management of panfacial fracture is extremely complex. But with the advent of modern imaging & improved surgeon's skill along with appropriate sequencing enable accurate restoration of facial form and function. For the optimum results timing of the surgery is very much important. For malunited panfacial fracture treatment planning is a challenging process.

#### **References**

- [1]. Usha Asnani et al. Panfacial Trauma - A Case Report. International journal of dental clinics 2010;2 (2): 35-38.
- [2]. Dongmei He et al. Panfacial Fractures: Analysis of 33 Cases Treated Late. American Association of Oral and Maxillofacial Surgeons. J Oral Maxillofac Surg 65:2459-2465, 2007.
- [3]. Lalitha Ramanujam et al. Panfacial fractures—A retrospective analysis at M.S. Ramaiah Group of Hospitals, Bangalore. Journal of Oral and Maxillofacial Surgery, Medicine, and Pathology 25 (2013) 333–340.
- [4]. William Curtis. Panfacial Fractures An Approach to Management. Oral Maxillofac Surg Clin North Am. 2013 Nov; 25(4):649-60.
- [5]. Michael A. Fritz, Md, peter j. Koltai, Md. Sequencing and organization of the repair of panfacial fractures operative techniques in otolaryngology-head and neck surgery, vol 13, no 4 (Dec), 2002: pp 261-264.
- [6]. Markowitz BL, Manson PN: Panfacial fractures: organization of treatment. Clin Plast Surg 16:105-114, 1989.
- [7]. Adamo Arthur K. Intraoperative airway management with pan-facial fractures: Alternative approach. J Craniomaxillofac Surg. 1996;2:30-5.
- [8]. Gruss JS, Phillips JH. Complex facial trauma: The evolving role of rigid fixation and immediate bone graft reconstruction. Clin Plast Surg .1989;16(1): 93-104.
- [9]. Merville L: Multiple dislocations of the facial skeleton. J Maxillofac Surg 2:187, 1974.
- [10]. Peter Ward Booth, Barry Eppley, Rainer Schmelzeisen., Textbook of Maxillofacial Trauma and Esthetic Facial Reconstruction, 247-254.
- [11]. B Michael Miloro, G.E. Ghalli, Peter E. Larsen, Peter D. Waite., Textbook of Peterson's principles of Oral & Maxillofacial Surgery, Third edition, Vol-1:599-600.
- [12]. Ilankovan V, Jackson It. Experience in the use of calvarial bone grafts in orbital reconstruction. Br J Oral Maxillofac Surg. 1992 Apr;30(2):92-6.

\*Dr. Tanmoy Ghorui. "Management of Malunited Panfacial Fracture With Calvarium Bone Graft – A Case Report." IOSR Journal of Dental and Medical Sciences (IOSR-JDMS) 16.11 (2017): 95-99