

## Treatment of Adult Femoral Shaft Fractures by Locking Compression Plate Osteosynthesis – A Prospective Study

Dr. Ashik A Bary<sup>1</sup>, Dr. Karma Uden Bhutia<sup>1</sup>, Prof. I Ibomcha Singh<sup>2</sup>,  
Prof. A Mahendra Singh<sup>2</sup>, Dr. Raghvendra Raghuvanshi<sup>1</sup>

1 Post Graduate Trainee, 2 professor, Department of Orthopaedics, Regional institute of medical sciences,  
Manipur University, Lamphelpat, Imphal, 795004, Manipur, India

**Abstract: Background:** There is much debate regarding the optimal treatment of shaft of femur fractures. Locking compression plating is a safe procedure for complex distal third fractures can be operated upon by direct visualisation without the use of IITV.

**Objectives:** The purpose of the study was to evaluate the anatomical and functional outcome of internal fixation with locking compression plate in adults with fracture shaft of femur.

**Methods:** This is a prospective study in which 30 patients with fracture shaft of femur, between the ages of 17 and 67 years who provided written informed consent to participate in the study were included, and were treated using locking compression plating technique from September 2012 to August 2014. Outcome measures included radiological and clinical union parameters, and functional outcome was assessed by Modified Sander's criteria.

**Results:** Clinical union was seen at a mean time of 16.1 weeks. The mean time to complete radiological union was 18.3 weeks. For supra-condylar fractures it was 14.1 and 17.1 weeks respectively. Based on assessment parameters, 27 patients(90%) had excellent to good, 3 patients(10%) had fair to poor outcome in the final result.

**Keywords:** Fracture shaft femur, locking compression plating, LCP femur.

### I. Introduction

The femur is the longest, strongest, and heaviest tubular bone in the human body and one of the principal load bearing bones in the lower extremity.<sup>[1-4]</sup> Fractures of the femoral shaft often result from high energy forces such as motor vehicle collisions.<sup>[5]</sup> Complications and injuries associated with mid-shaft femur fractures in the adult can be life-threatening and may include haemorrhage, internal organ injury, wound infection, fat embolism, and adult respiratory distress syndrome.<sup>[2,6]</sup> Femoral shaft fractures can also result in major physical impairment due to potential fracture shortening, mal-alignment, or prolonged immobilization of the extremity with casting or traction.<sup>[2]</sup>

### Winquist and Hansen Classification of Fracture Comminution <sup>[7]</sup>

Grade	Degree of Comminution
0	No comminution.
I	Small butterfly fragment or comminuted segment with at least 50% cortical contact remaining between the diaphyseal segments.
II	Large butterfly fragment or comminuted segment with <50% cortical contact between the diaphyseal segments.
III	Large butterfly fragment or comminuted segment with <50% cortical contact between the diaphyseal segments. Segmental.
IV	Complete cortical comminution such that there is no predicted cortical contact between the diaphyseal segments. Segmentally comminuted.

### Treatment

Operative stabilisation with any technique offers numerous advantages compared with non-operative methods and includes early patient mobilization and early functional rehabilitation of the injured extremity. There are various operative options for fracture shaft of femur like

- >Intramedullary nailing with open or closed technique.
- >Antegrade & Retrograde interlocking intramedullary nailing with/without reaming.
- >External fixation
- >Plate fixation

Several distinct advantages to plating do exist, including the ability to obtain an anatomic reduction in appropriate fracture patterns and the lack of additional trauma to remote locations such as the femoral neck, acetabulum, and distal femur.<sup>[8]</sup> Also almost any fractured of the femur can be successfully plated.<sup>[9]</sup>

## **II. Materials And Methods**

After due approval from the institution ethical committee and obtaining written informed consent of the individual patients, were taken. All patients with fractures shaft of femur who came to the department of orthopaedics from emergency services and Out-patient department(OPD), were admitted between September 2010 to august 2012.They were assessed by antero-posterior and lateral view X-rays of the affected limb. Routine Investigations were done in all patients.

The study was an intervention experimental without control, hospital based and patient with mental and physical inability to cooperate and presence of complicating medical condition and patient's who refuses to give consent for operation were excluded. Data collected were analysed by using descriptive statistics like mean and percentages.

### **Operative Technique**

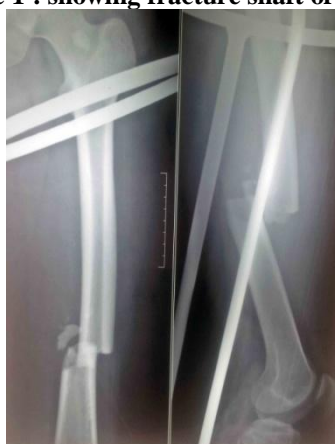Patients were positioned in supine slightly or lateral position with/without using a fracture table depending on the situation. After preparing and draping the limb, the fracture site was approached through a lateral incision and skin incision followed by splitting of the fascia lata and vastus lateralis until the lateral femoral cortex in line with incision. Open reduction of fracture was done and maintained by bone clamps. The appropriate chosen sized locking compression plate was placed into position and stabilized. Then fixation was achieved by insertion of variable numbers of locking screws. The skin wounds were closed over a negative suction drain. During immediate post operative period passive and active movements of the toes were encouraged. Patients received parenteral anti-biotics for five days.

Patients were followed up once a month for the first three months after surgery, then once in six weeks for the next three months and then at the end of study period. In each visit, clinical and radiological assessment of union and fracture callus quality were done in addition to functional limb assessment by Sander's criteria.<sup>[10]</sup> Gradual weight bearing was commenced with evaluation of clinical and radiological fracture progression at follow up visits.

## **III. Results**

The mean duration of operation was 69.25 minutes (range 54-93 minutes). All patients were subjected to open reduction and internal fixation by locking compression plate. Patients were followed up at 4, 8, 12, 16 and 20 weeks in the outpatients Department of Orthopaedics, RIMS. The mean age of the patients was 34.8 years with the range of 17 to 67 years. There were 24 males and 6 females. The study subjects comprised of higher percentage of male (80%) as compared to female (20%). The right limb was involved in 20 patients (66.7%) and left in 10 patients (33.3%). Majority of the study population who had fracture femur were due to Road Traffic Accident which accounted for 80% (24). 20% (6) had injury following fall. In 15 of the patients, mid diaphyseal part was affected, in 10 patients, the distal third was affected and in 5 patients the proximal third was affected. The time taken from injury to operation was in the range of 7 to 50 days with the mean duration being 12.5 days. Blood transfusion was resorted in 33% (10) of study subjects. Figure 1 showing fracture shaft of femur.

**Figure 1 : showing fracture shaft of femur.**

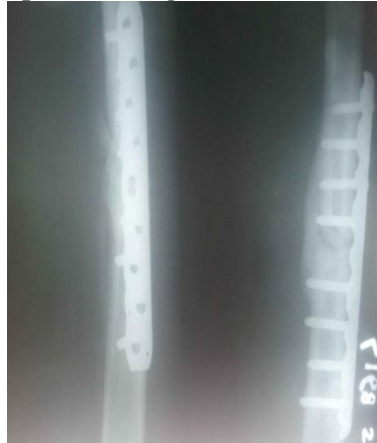

Clinical union was seen at a mean time of 16.1 weeks. The duration for supra-condylar fracture was 14.5 weeks and for mid-diaphysis it was 16.6 weeks. Radiologically, bridging callus was seen at 12-16 post operative weeks and mean time to complete radiological union was 18.3 weeks. For supra-condylar fracture it was 17.1 weeks and for mid-diaphysis 19 weeks. This is shown in table 1. Figure 2 showing complete radiological union with LCP in-situ.

**Table 1 : showing time of clinical and radiological bony union in weeks.**

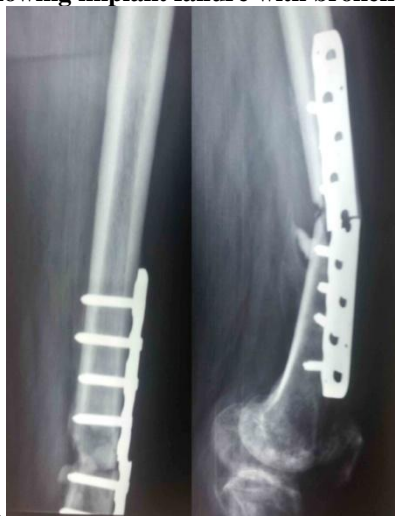Type of Union	Duration to union for supra-condylar fracture(weeks)	Duration to union for mid-diaphyseal fracture (weeks)	Mean duration to union (weeks)
Clinical union	14.5	16.6	16.1
Radiological union	17.1	19	18.3

**Figure 2 : showing complete radiological union with LCP in-situ at 17 weeks.**



There were no intra-operative or immediate postoperative complications. However, there were late complications in the form of two cases of broken implant which was seen in mid diaphysis fracture, one case of superficial infection and one case of screw loosening in distal third fracture. The broken implant cases had to be re-operated with removal of the implant and internal fixation with longer plate and fibular grafting was done. Others were treated conservatively as fracture was healing. Figure 3 showing implant failure with broken plate in-situ.

**Figure 3 : showing implant failure with broken plate in-situ**



Based on the assessment parameters (Modified Sanders)<sup>[10]</sup> used in this study, 27 patients (90%) had excellent to good, 3 patients (10%) had fair to poor outcome in the final result. This is illustrated in table 2 and figure 4. Figure 5 showing complete ROM knee.

**Table 2: Showing final result.**

Outcome	Number of patients	Percentage (%) (n=30)
Excellent	20	66.7
Good	7	23.33
Fair	2	6.7
Poor	1	3.3
Total	30	100.00

Figure 4 : showing final result.

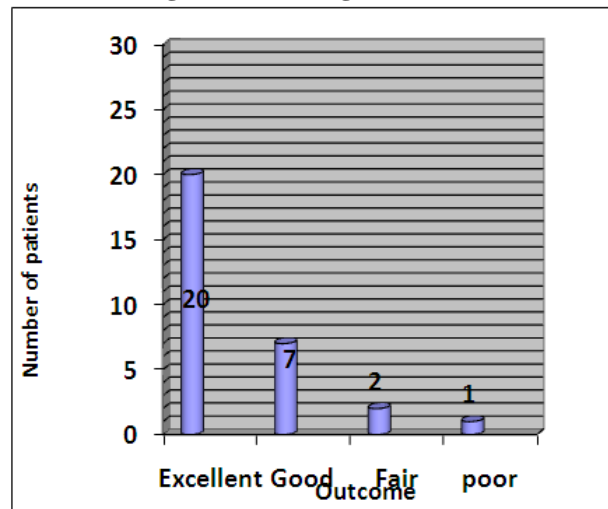


Figure 5 : showing complete range of motion of knee at 16 weeks



#### IV. Discussion

Thirty adult patients with fracture shaft of femur underwent open reduction and internal fixation with locking compression plate in the Department of Orthopaedics, RIMS, Imphal between September 2010 to August 2012.

Patients were between 17-67 years of age, with a mean age of 34.8 years. Similar reports by El Sayed A et al<sup>[11]</sup> in his study with mean age 31 years. The age group of 21-30 comprised the highest number of patients(43.33%). This is similar to findings of Valles et al<sup>[12]</sup> where the significant predominance was found in between ages of 20-29 yrs. There were 24 males and 6 female patients (M:F=4:1). Similar male preponderance was seen by other authors; BM Yuan<sup>[13]</sup> reported 18 males to 3 females (M:F=6:1). Associated injuries were seen in 9 of 30 patients (30%). This is close to reports by Su Qi et al<sup>[14]</sup> where associated injuries were seen in 23%. All associated injuries were appropriately managed with a favourable outcome. Road traffic accidents accounted for majority of fractures (80%), and fall from height accounted for remaining (20%). Similar findings by Su Qi et al<sup>[14]</sup> 70% and 30%. The right femur was involved in 20 (66.7%) patients and left in 10 (33.3%) patients. Valles et al<sup>[12]</sup> reported right sided involvement in 29 (55%), and left in 23 (45%) patients. The mean days to operation from the date of injury was 12.5 days (7 to 50 days). Almost similar findings by Ej Yeap et al<sup>[15]</sup> with the mean of 9.9 days. Open plating was done in all patients in the present series. The open method was chosen because this is the only set up available in our institution. Ej Yeap et al<sup>[15]</sup>, Su Qi et al<sup>[14]</sup> and Bae SH et al<sup>[16]</sup> have all used open methods. The mean operating time was 69.25 minutes (54 – 93 minutes). The mean duration of hospitalisation for all patients was 24.1 days (17-60 days). Ej Yeap et al<sup>[15]</sup> reported an average post operative hospitalisation of 17.2 days(8-34 days). The mean duration of follow up was 16.2 months (4-26 months). This finding is almost similar with findings by Kregor et al<sup>[17]</sup> followed up for a mean of 14 months (3-50 months). Intraoperative blood loss has been maintained in between 150 to 200 ml.

Clinical union was seen at a mean time of 16.1 weeks. JPS Walia et al<sup>[18]</sup> reported having clinical union between 12-16 weeks post op. Bae SH et al<sup>[16]</sup> reported mean time to union as 14.3 weeks. Radiologically, bridging callus was seen at 12-16 post operative weeks and mean time to complete radiological union was 18.3 weeks. Ej Yeap et al<sup>[15]</sup> reported mean 18 weeks (6-36 weeks).

Complications were encountered in the form of broken implant in 2 cases, loosening of screw in 1 case and minor skin infection in 1 case (13.33%). The broken plate cases were found to be due to non compliances on the part of patient and one of which was managed by removal of the plate and replacement with a new longer LCP with fibular bone grafting and subsequently united. Infection was treated by appropriate antibiotic after culture and sensitivity test. Others were managed subsequently by other methods as bone showed union at the time of reporting. The findings are almost similar with comparative study by Y Zhang<sup>[19]</sup> where complications were one case of screw loosening and one broken implant (n=19). Kregor et al<sup>[17]</sup> reported 13% complications (16 out of 119 patients).

Based on the assessment parameters (Modified Sanders)<sup>[10]</sup> used in this study, 27 patients (90%) had excellent to good, (10%) had fair to poor outcome in the final result. Bae SH et al<sup>[16]</sup> reported excellent to good outcome in 17 patients (81%), fair in 3 (14.2%) and failure in 1 (4.7%) patient, while Su Qi et al<sup>[14]</sup> reported overall satisfactory result of 90% using Sanders criteria. BM Yuan<sup>[13]</sup> reported 83% patients had excellent to good outcome.

## V. Conclusion

Femoral fractures in adult are common with the most common cause of fracture being road traffic accident. There are various treatment modalities for femoral shaft fractures with its own advantages and disadvantages. Femoral locking plate is an accepted method of treating femoral shaft fractures especially in osteoporotic and comminuted fractures. Though locking compression plate can be used in any parts of fracture shaft of femur, it is specially indicated in distal femoral fractures as most of the mid diaphyseal fractures can be treated by intramedullary nailing. Locking compression plating is a safe procedure for complex distal third femoral fractures as the fracture site can be operated upon by direct visualisation without the use of IITV especially in hospital where there is no proper instrument and equipment. With an excellent functional outcome, early clinical and radiological union, it can be done on a routine basis with a minimum of complications.

## References

- [1]. Moore KL, Agur AM. Clinically Oriented Anatomy. 6<sup>th</sup> ed. Baltimore: Williams & Wilkins; 2009.
- [2]. Bucholz R, Brumback R. Fractures of the shaft of the femur. In: Green D, Bucholz R, et al. Rockwood and Green's Fractures in Adults. 4<sup>th</sup> ed. Philadelphia: Lippincott-Raven; 1996. p. 1827.
- [3]. Platzer W. Locomotor system. In: Color Atlas of Human Anatomy. 6<sup>th</sup> ed. Stuttgart: Thieme Medical Publishers; 2009. Vol 1.
- [4]. Whittle AP, Wood GW II. Fractures of the lower extremity. In: Canale ST, editor. Campbell's Operative Orthopaedics. 10<sup>th</sup>. Mosby: St. Louis; 2003. p. 2825.
- [5]. Bucholz RW, Jones A. Fractures of the shaft of the femur. J Bone Joint Surg Am 1991; 73: 1561.
- [6]. Keel M, Trentz O. Pathophysiology of polytrauma. Injury 2005; 36: 691.
- [7]. Winquist RA, Hansen ST Jr. Comminuted fractures of the femoral shaft treated by intramedullary nailing. Orthop Clin North Am 1980; 11: 633-47.
- [8]. Gates DJ, Alms M, Cruz MM. Hinged cast and roller traction for fractured femur. A system of treatment for the Third World. J Bone Joint Surg Br 1985; 67(5): 750-6.
- [9]. Bucholz RW, Heckman JD. Rockwood & Green's Fractures in Adults. 5<sup>th</sup> Edition: Lippincott Williams & Wilkins; 2001.
- [10]. Sanders R, Swiontkowski M, Rosen H, Helfet D. Double-plating of comminuted, unstable fractures of the distal part of the femur. J Bone Joint Surg Am 1991; 73 (3): 341-6.
- [11]. el-Sayed A, Saïd HG, Abdel-Aal A, Farouk O. Locked plate fixation for femoral shaft fractures. Int Orthop 2001; 25(4): 214-8.
- [12]. Valles Figueroa JFJ, Rodríguez Reséndiz F, Gómez Mont JG. Distal femur fractures. Comparative analysis of two different surgical treatments. Acta Ortopédica Mexicana 2010; 24(5): 323-29.
- [13]. Yuan BM. Preliminary clinical analysis of locking compression plate fixation in treatment of femoral shaft fractures in adults [dissertation]. China; 2012.
- [14]. Su Qi, Chen Mountain, Zhang flowers, Zhou, Song Xiaobin, Zhanhai Peng, Cai Jundong. Locking compression plate fixation of distal femoral fractures. Clinical Medicine Papers. <http://www.hi138.com> /access on 10.5.2011.
- [15]. Yeap EJ, Deepak AS. Distal Femoral Locking Compression Plate Fixation in Distal Femoral Fractures: Early Results. Malaysian Orthopaedic Journal 2007 May; 1(1): 12-17.
- [16]. Bae SH, Cha SH, Suh JT. Treatment of Femur Supracondylar Fracture with Locking Compression Plate. Jn Korean Fract Soc. Jul 2010; 23(3): 282-88.
- [17]. Kregor PJ, Stannard JA, Zlowodzki M, Cole PA. Treatment of Distal Femur Fractures Using the Less Invasive Stabilization System: Surgical Experience and Early Clinical Results in 103 Fractures. J Orthop Trauma 2004 Sep; 18(8): 509-20.
- [18]. JPS Walia, Avinash Gupta, Girish Sahni, Gagandeep Gupta, Sonam Kaur Walia. Role of locking compression plate in long bone fractures in adults - a study of 50 cases. Pb Journal Of Orthopaedics Vol-XI, No.1, 2009.
- [19]. Zhang Y. Comparison of effect between intramedullary nails and locking compression plates in the treatment of femoral shaft fracture [dissertation]. China; 2011.