

Primary Papillary Adenocarcinoma of Urinary Bladder: A Case Report

Raisa Ghosh¹, Srishtidhar Mangal², Sukla Naskar³, Keya Basu⁴

1)2nd Year Postgraduate Trainee; 2)Associate Professor; 3)Assistant Professor; 4)Professor & Head Of The Department

Department Of Pathology, Calcutta National Medical College & Hospital, Kolkata

Abstract: A 50 year old male presented with painless haematuria and nocturia since 3 months. Routine examination revealed mild anaemia and raised ESR. Ultrasonography of Kidneys, Bladder and Prostate showed an irregular mass in urinary bladder. An abdominal contrast enhanced computed tomography scan showed a 4cm mass in the posterior wall of urinary bladder. Cystoscopy and Transurethral resection of the mass was done. Histopathology revealed it as Adenocarcinoma with muscle invasion. Surgical intervention in the form of cysto-prostatectomy, bilateral pelvic lymph node dissection, bilateral uretero-sigmoidostomy was done. A soft nodular exophytic growth was found in the posterior wall of urinary bladder. Histopathology and Immunohistochemistry confirmed it as Primary Papillary Adenocarcinoma. All other visceral sites were adequately excluded for primary adenocarcinoma. We are reporting this case as Primary papillary adenocarcinoma of urinary bladder, which is a rare neoplasm.

Keywords: Primary Papillary Adenocarcinoma, Urinary Bladder, Rare Neoplasm

I. Introduction

Primary adenocarcinoma of bladder is rare with an incidence of 0.5-2% of all bladder carcinomas.^{1,6} It may be of urachal in origin, associated with schistosomiasis or unassociated with any of these.^{1,2,6} Median age of presentation is around 50 years with a slight male predominance. Prognosis in urachal ones is better than the non-urachal ones.⁵ The 5 year survival rate is around 18-47%.¹

II. Case Report

A male, 50 years old, presented with painless haematuria and nocturia for past 3 months. His past medical history was unremarkable. Digital rectal examination excluded any evidence of prostatic or rectal malignancy.

III. Investigations

Transabdominal ultrasound showed a hypoechoic lesion in the urinary bladder. CECT of KUB region showed a lobulated, predominantly solid mass in the posterior wall of urinary bladder; the mass had scattered low attenuation areas. Cystoscopy and TURBT was done next; histopathology of the resected tumor confirmed it to be 'Moderately differentiated Adenocarcinoma of urinary bladder invading deeper muscle layer'.

IV. Surgery

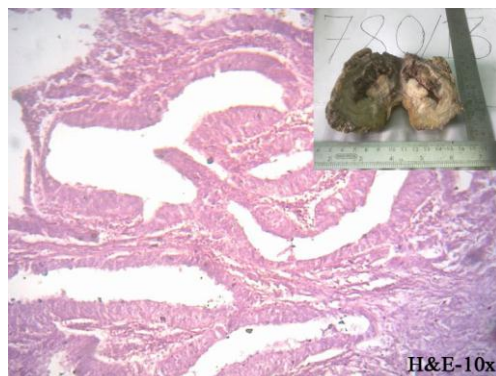
Following the above investigations, radical cystoprostatectomy, B/L pelvic lymph node dissection, B/L ureterosigmoidostomy was done.

V. Histopathology

Grossly, a 4cm x 3.5cm x 2cm exophytic, nodular mass was found to involve the posterior wall of urinary bladder; cut surface of the mass was yellowish white with minute foci of haemorrhage and necrosis.

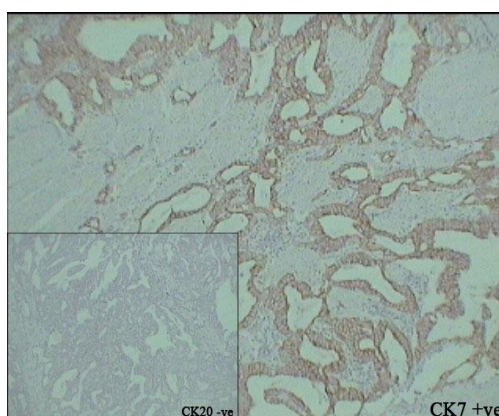
Histopathology of the mass confirmed the diagnosis as Primary papillary adenocarcinoma of urinary bladder showing predominantly papillary architecture; papillae and variable sized glands are lined by malignant cells with abundant pale eosinophilic cytoplasm, marked nuclear pleomorphism and were found to dissect through muscularis propria.

Histopathology of the resected prostate showed Benign hyperplasia of prostate which excluded direct invasion of the bladder by prostatic adenocarcinoma.



VI. Immunohistochemistry

The neoplastic cells showed **CK7 Positivity** (thus excluding possibility of metastatic adenocarcinoma) and **CK20 Negativity**.



VII. Discussion

Bladder adenocarcinomas are of three types- Primary,Urachal,Metastatic.⁶ Regarding histogenesis of Primary Adenocarcinoma of Urinary Bladder,*Mostofi* proposed that metaplastic changes consequent to chronic vesical irritation and infection may be the predisposing factor.^{1,3,4}

Haematuria is the most common presenting symptom;other symptoms like mucosuria(rarely),dysuria,nocturia,frequency,pain may be present^{1,3,4}

Histologic variations^{1,4} are- Adenocarcinoma NOS

- Adenocarcinoma,enteric type
- Adenocarcinoma with signet ring cells
- Mucinous Adenocarcinoma
- Clear cell Adenocarcinoma
- Hepatoid Adenocarcinoma
- Mixed Adenocarcinoma

Immunohistochemically,vesical adenocarcinomaas express CEA,CDX2,MUC1,MUC2,MUC3,same as colonic adenocarcinoma.^{1,2,3,4} CK7 and CK20 are usually positive unlike colonic adenocarcinoma.^{3,4,5}

VIII. Differential Diagnosis

- Local/metastatic spread
- TCC with glandular differentiation
- Intestinal metaplasia
- Villous adenoma
- Endometriosis,Endocervicosis,Endosalpingosis

IX. Conclusion

Primary adenocarcinoma of urinary bladder is a rare neoplasm whereas metastatic adenocarcinoma is a comparatively common entity.However,metastasis can be excluded clinically,radiologically and immunohistochemically.

References

- [1]. Christopher D.M Fletcher.Diagnostic Histopathology of tumors.3rd edition.Churchill Livingstone,Elsevier;2007.
- [2]. Juan Rosai.Rosai and Ackerman's Surgical Pathology.10th edition.Mosby,Elsevier;2011
- [3]. Stacey E.Mills.Sternberg's Diagnostic Surgical Pathology.5th edition.Wolter's Kluwer,Lippincot Williams & Wilkins;2010.
- [4]. Konstantinos Sigalas,Stavros I Tyrirtzis,Eleni Trigka,Ioannis Katafigiotis,Nikolaos Kavantzas,Konstantinos G Stravodimos.A male presenting with a primary mucinous bladder carcinoma:A case report.Cases Journal.2010;3:49.
- [5]. Mardi K,Gupta N.Urachal papillary cystadenocarcinomas:A rare case report.J Can Res Ther 2011;7:223-5.